

**US HDLIVE EN OBSTETRICIA Y  
GINECOLOGIA**

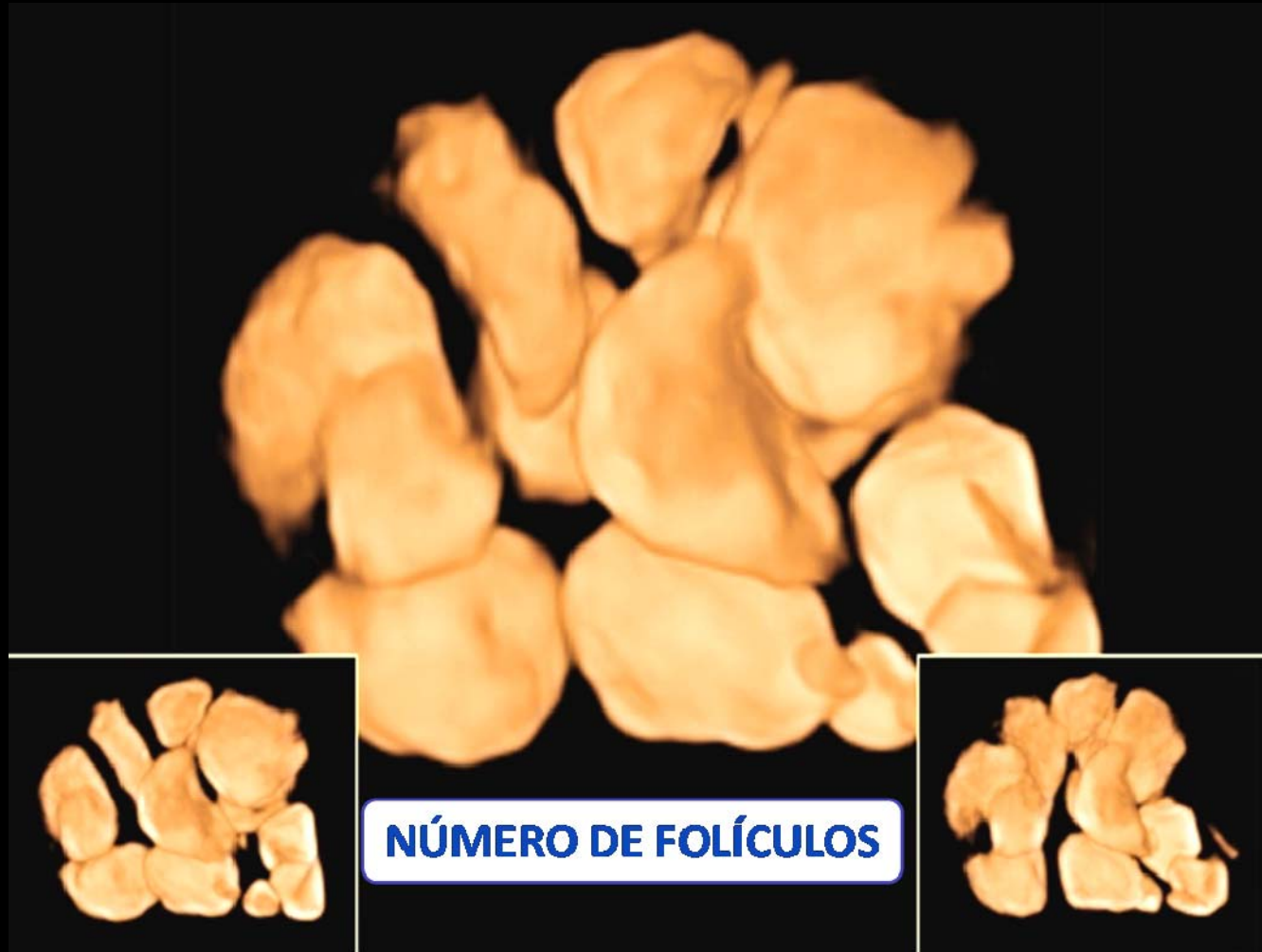**PROF. DR. MED. PROF. H.C**

**F.BONILLA-MUSOLES**

**REAL ACADEMIA DE MEDICINA DE LA  
COMUNIDAD VALENCIANA**

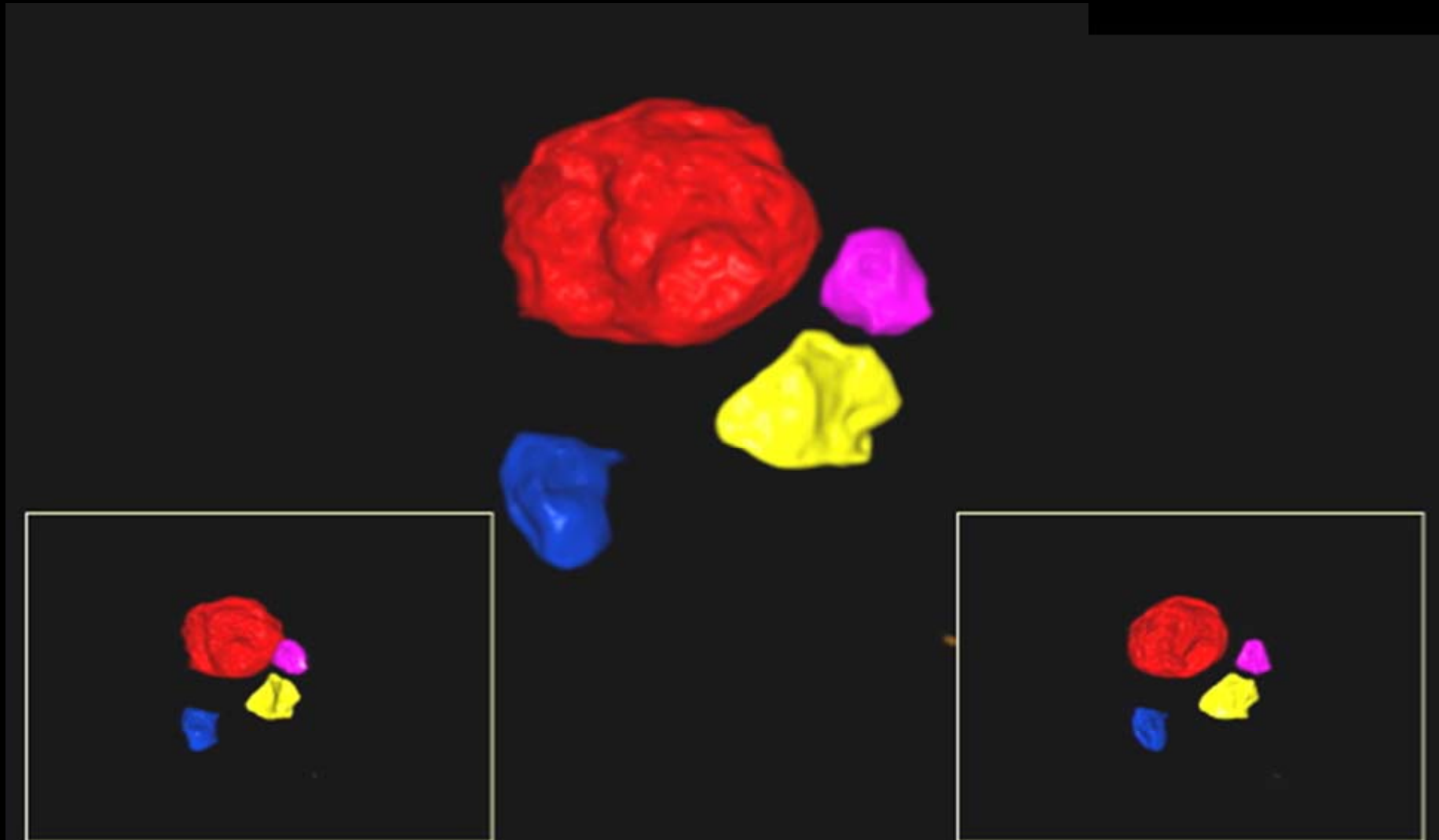
**29- 04- 2014**

# NUEVOS MODOS ECOGRÁFICOS DE CONTROL FETAL MODO INVERSO



# NUEVOS MODOS ECOGRÁFICOS DE CONTROL FETAL


## AVC AUTOMATIC VOLUME CALCULATION



# **NUEVOS MODOS ECOGRÁFICOS DE CONTROL FETAL**

**VOCAL: SEMI-AUTOMATIC ORGAN CALCULATION**

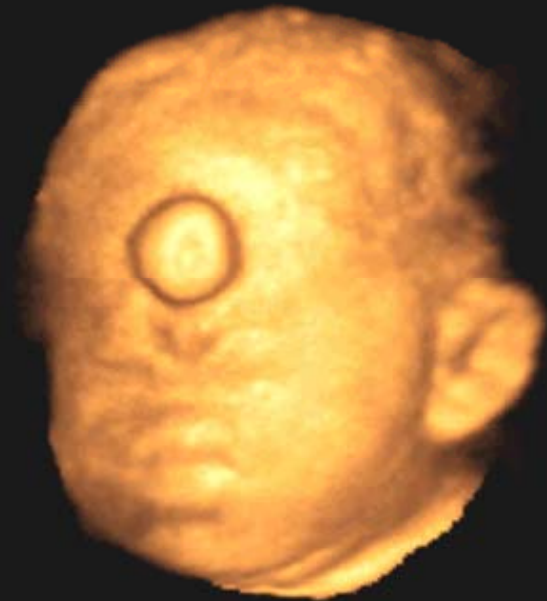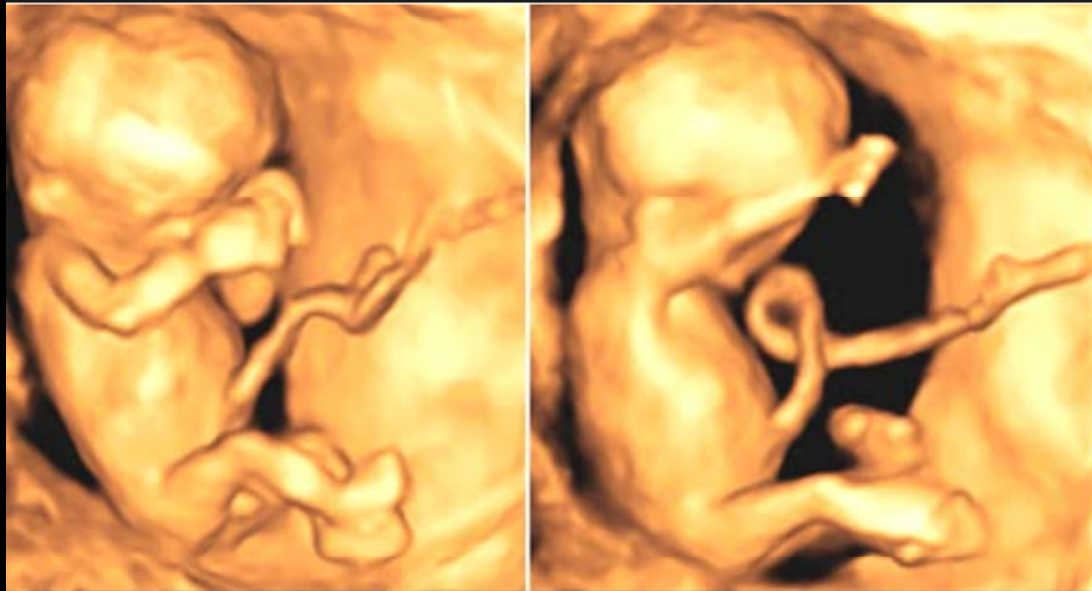## **MEDICIONES TOTALES CÁSCARA**



# NUEVOS MODOS ECOGRÁFICOS DE FETAL

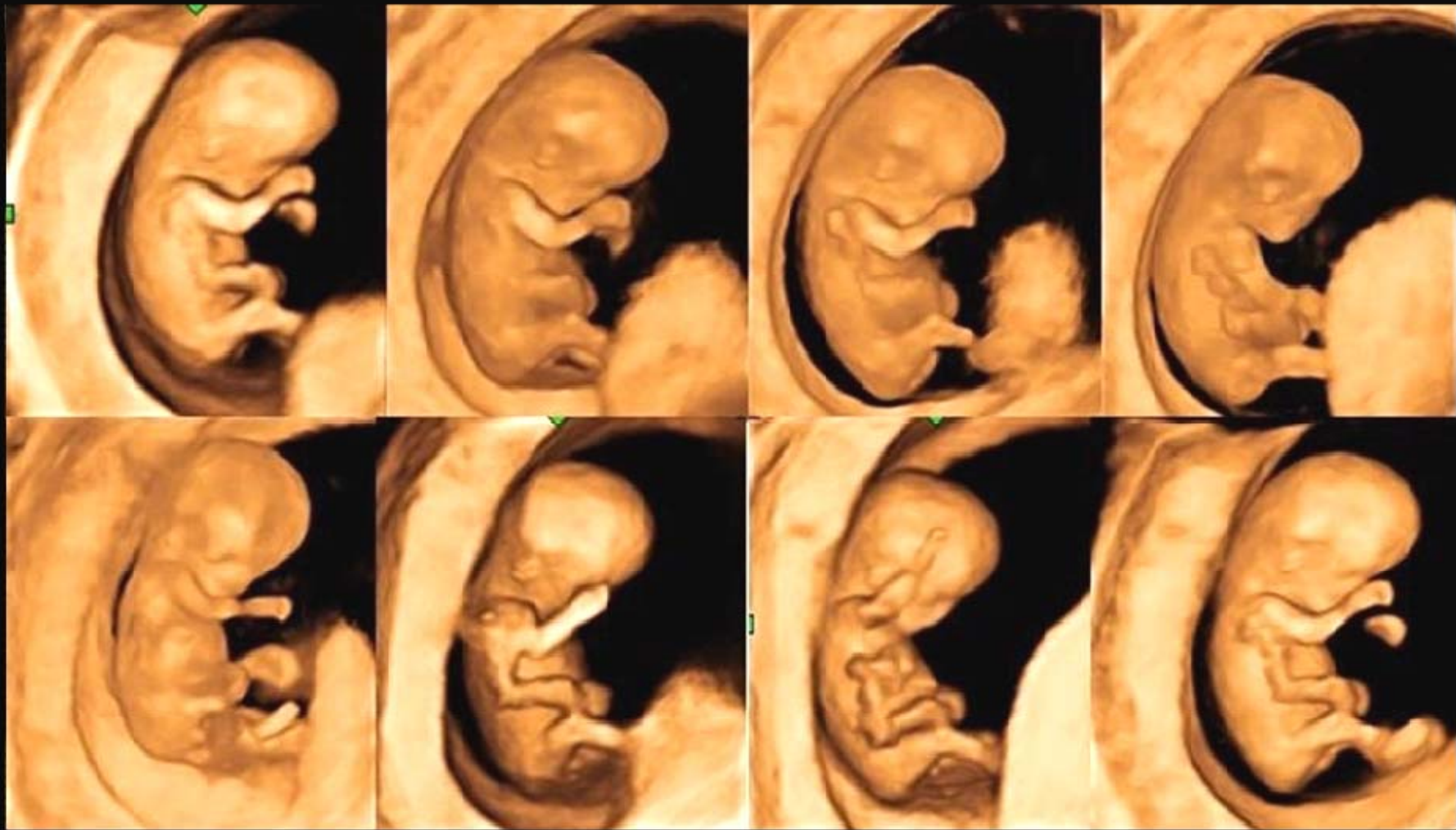3D/4D

## CORDÓN

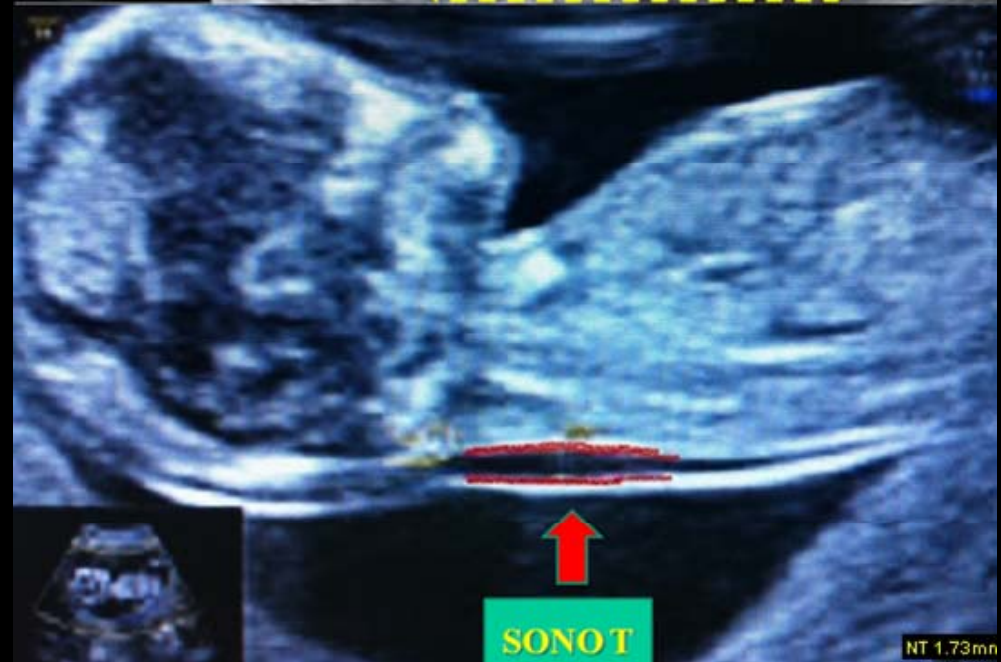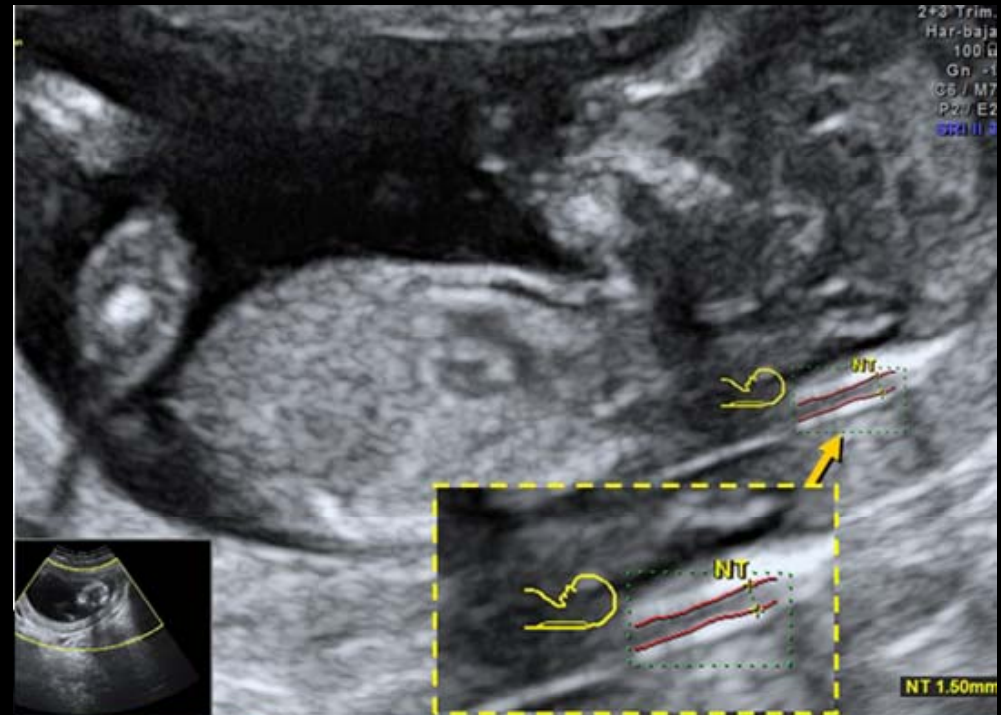


# NUEVOS MODOS ECOGRÁFICOS DE CONTROL FETAL

## TOMOGRAFIA ULTRASONOGRÁFICA




# NUEVOS MODOS ECOGRÁFICOS DE FETAL SONO T




# MEJORA DE LA CALIDAD Y COLOR DE LA IMAGEN

- MAYORES FRECUENCIAS
- MAYORES AMPLITUDES
- MODOS 3D
- CAMBIOS DE COLOR

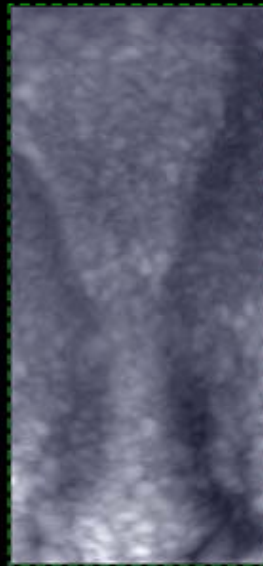
**HD LIVE**



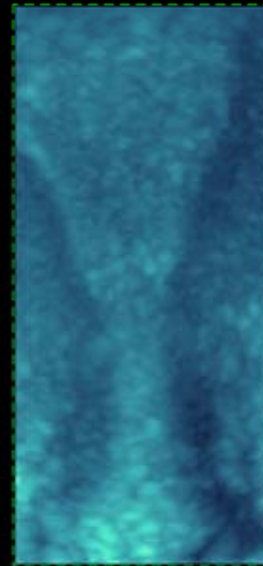
VELA




SEPIA



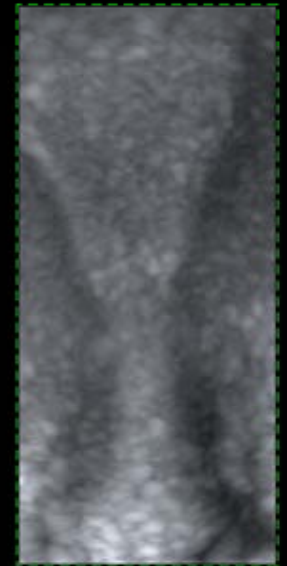
HIELO



AZUL



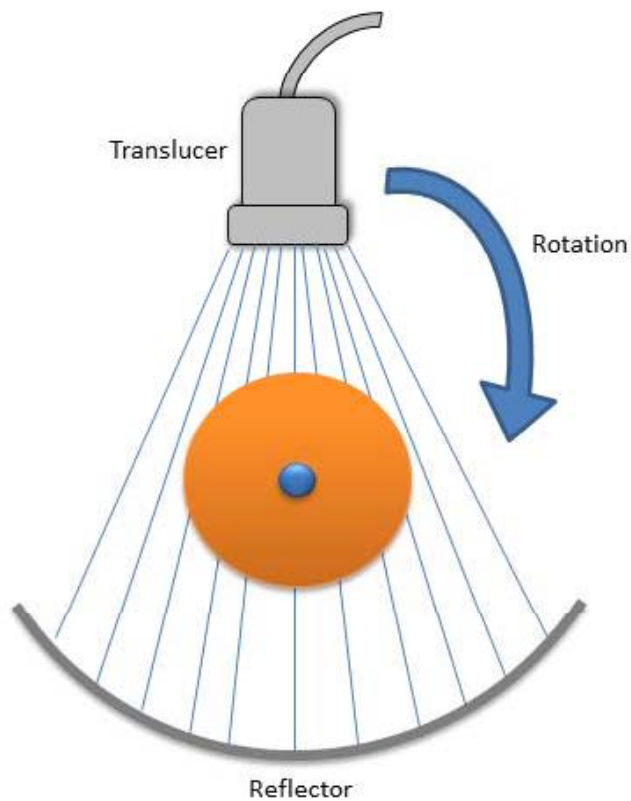
COBRE



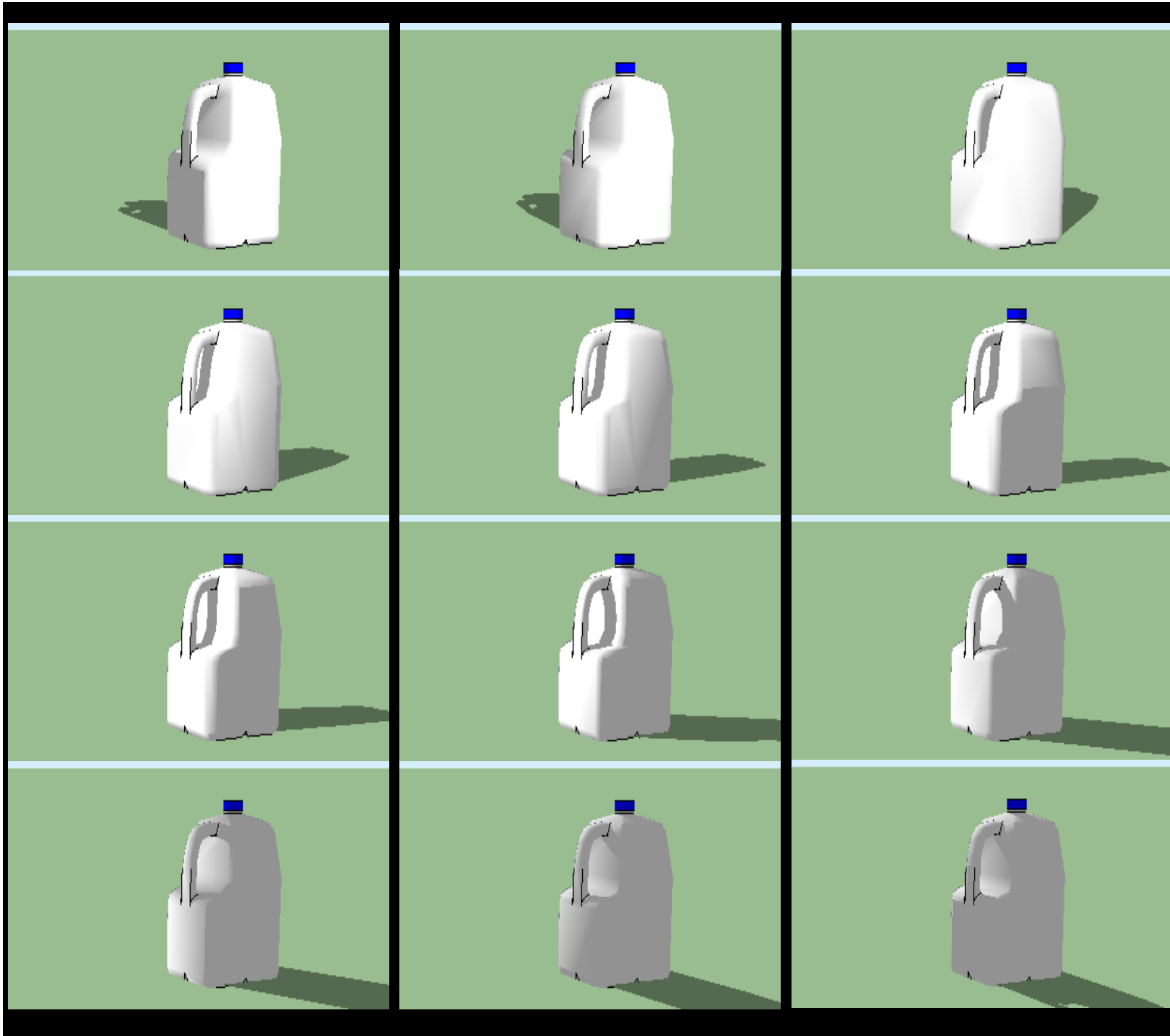
CROMA  
CLARO



## SOUND SPEED MEASUREMENT



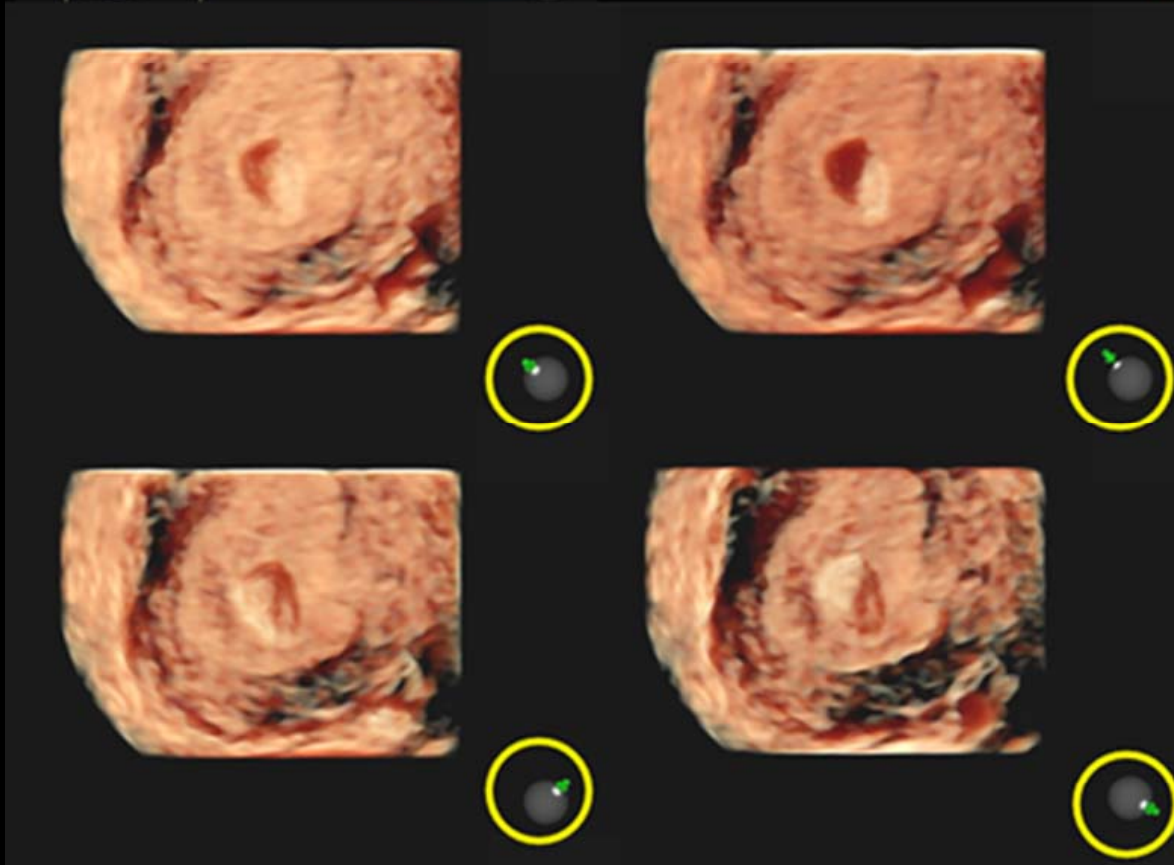
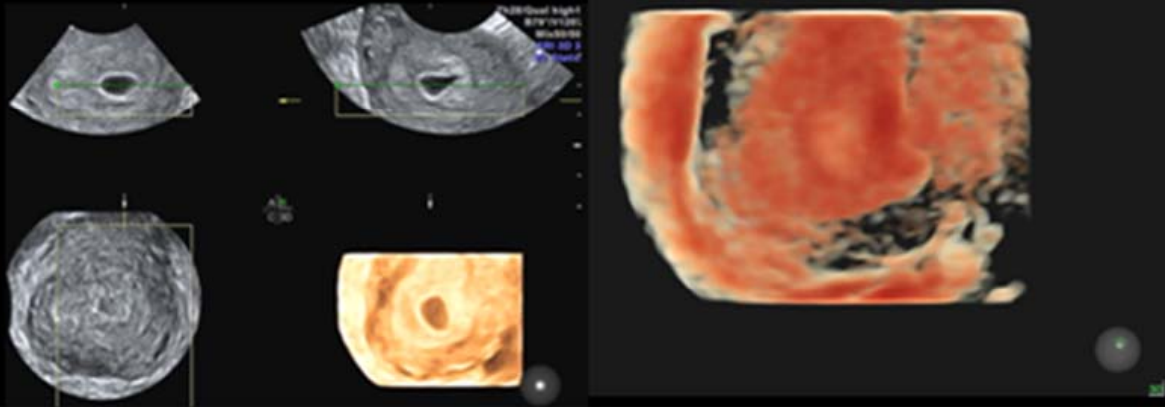
**128 Radiofrequency scan lines.**  
**2400 samples at 0.0627 microseconds per sample ( 16 Mhz sample rate)**



**CAMBIA LA  
POSICIÓN  
DE LA  
FUENTE DE  
LUZ**

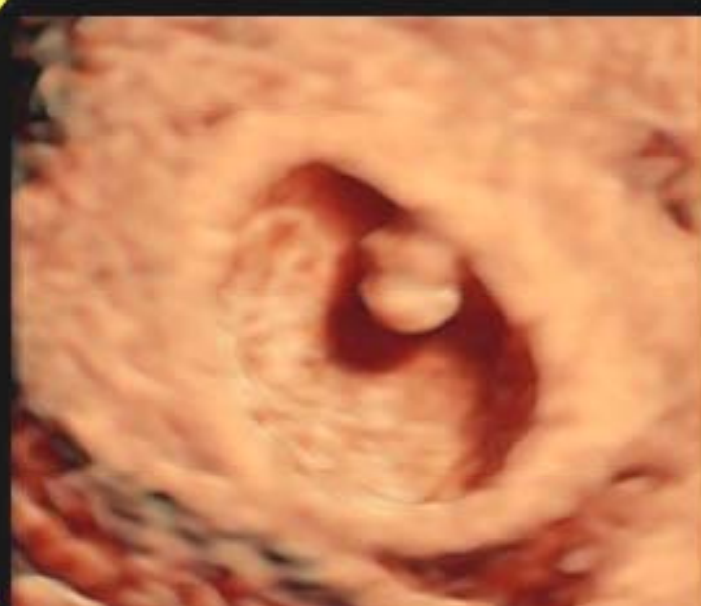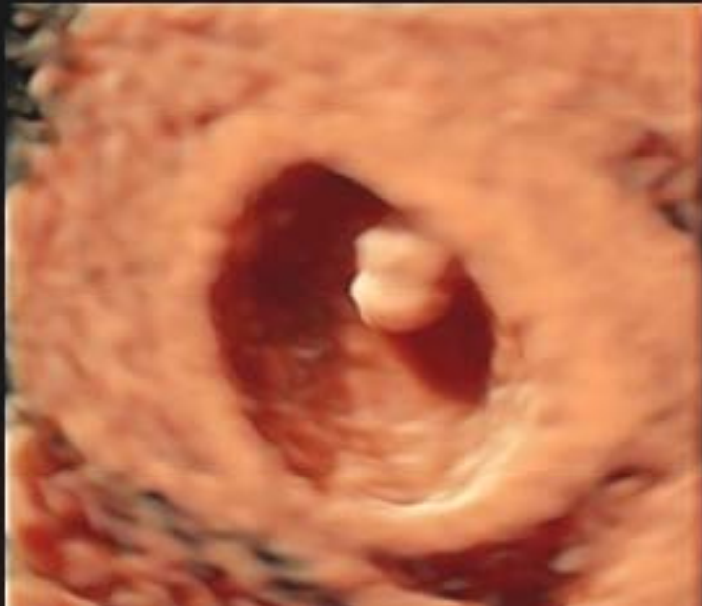
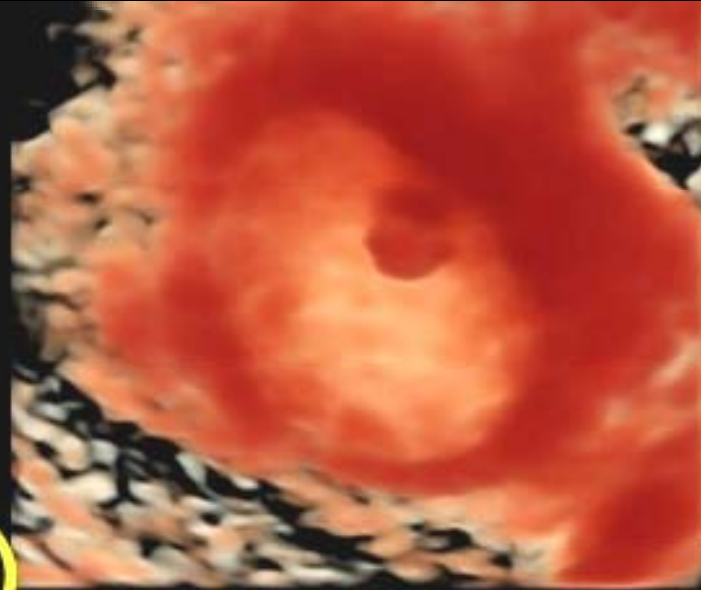
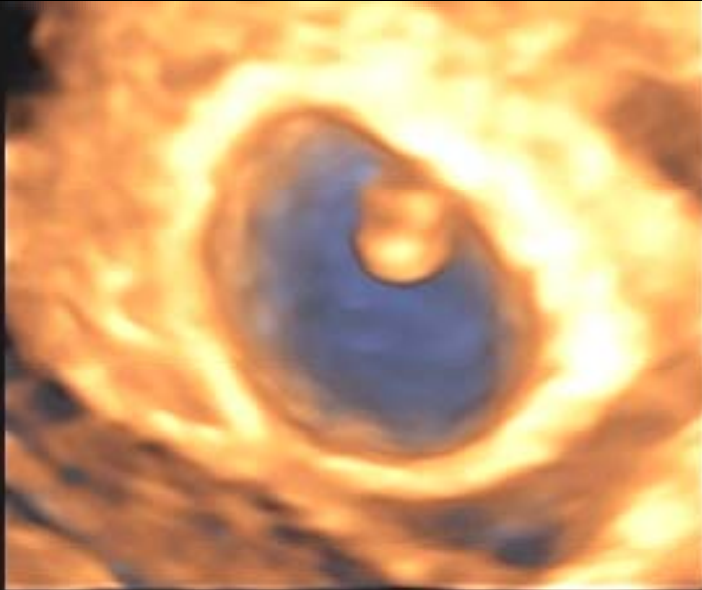


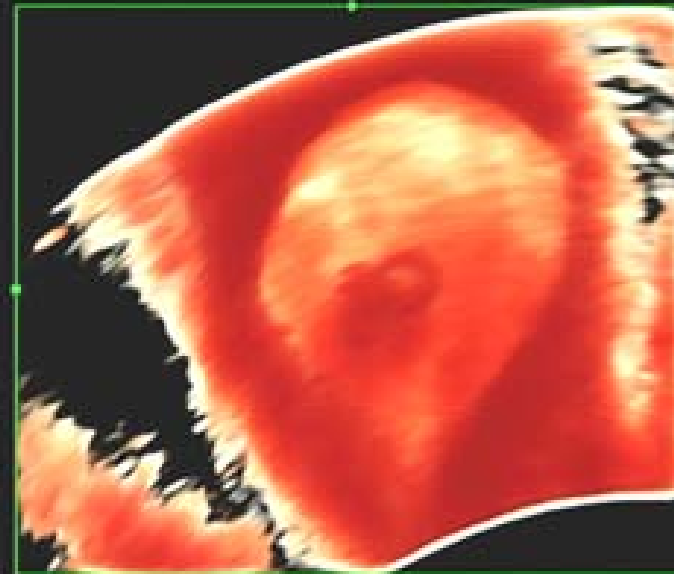
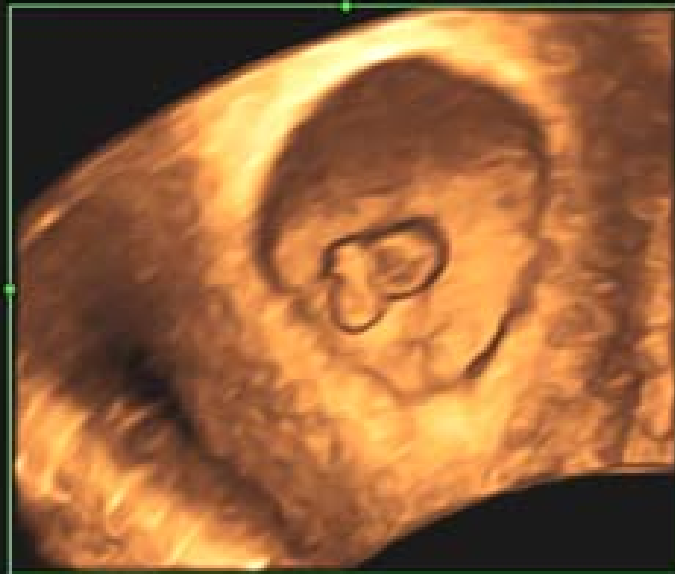**CAMBIA LA POSICIÓN  
DEL OBJETO**



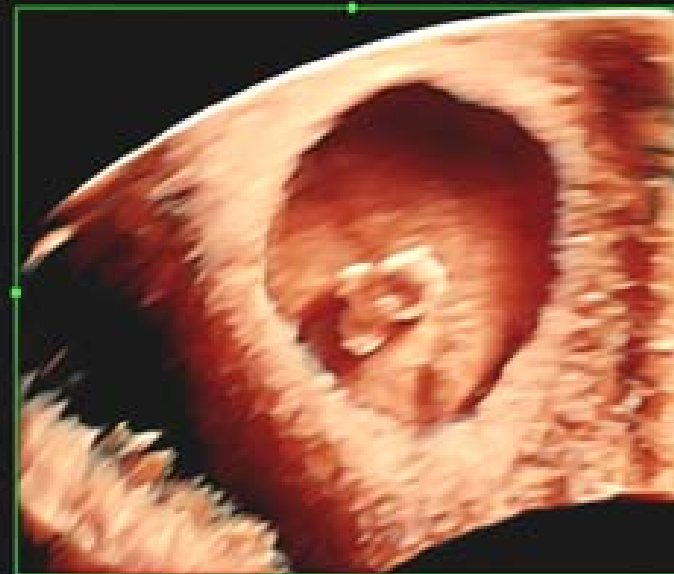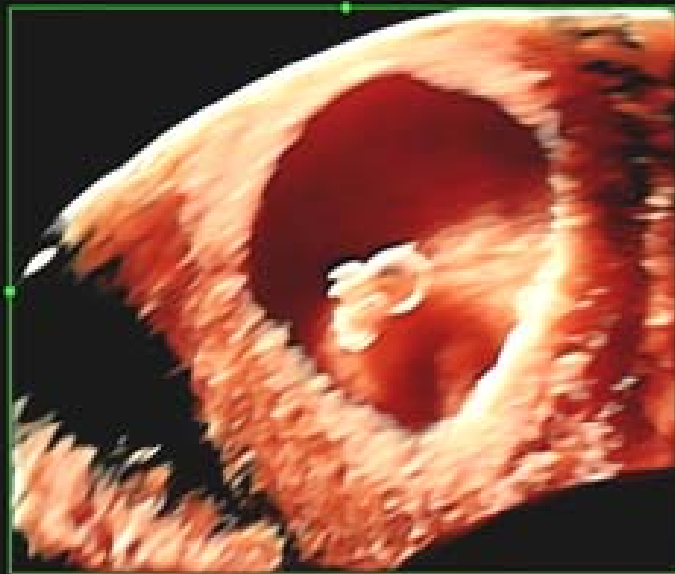31  
DIAS

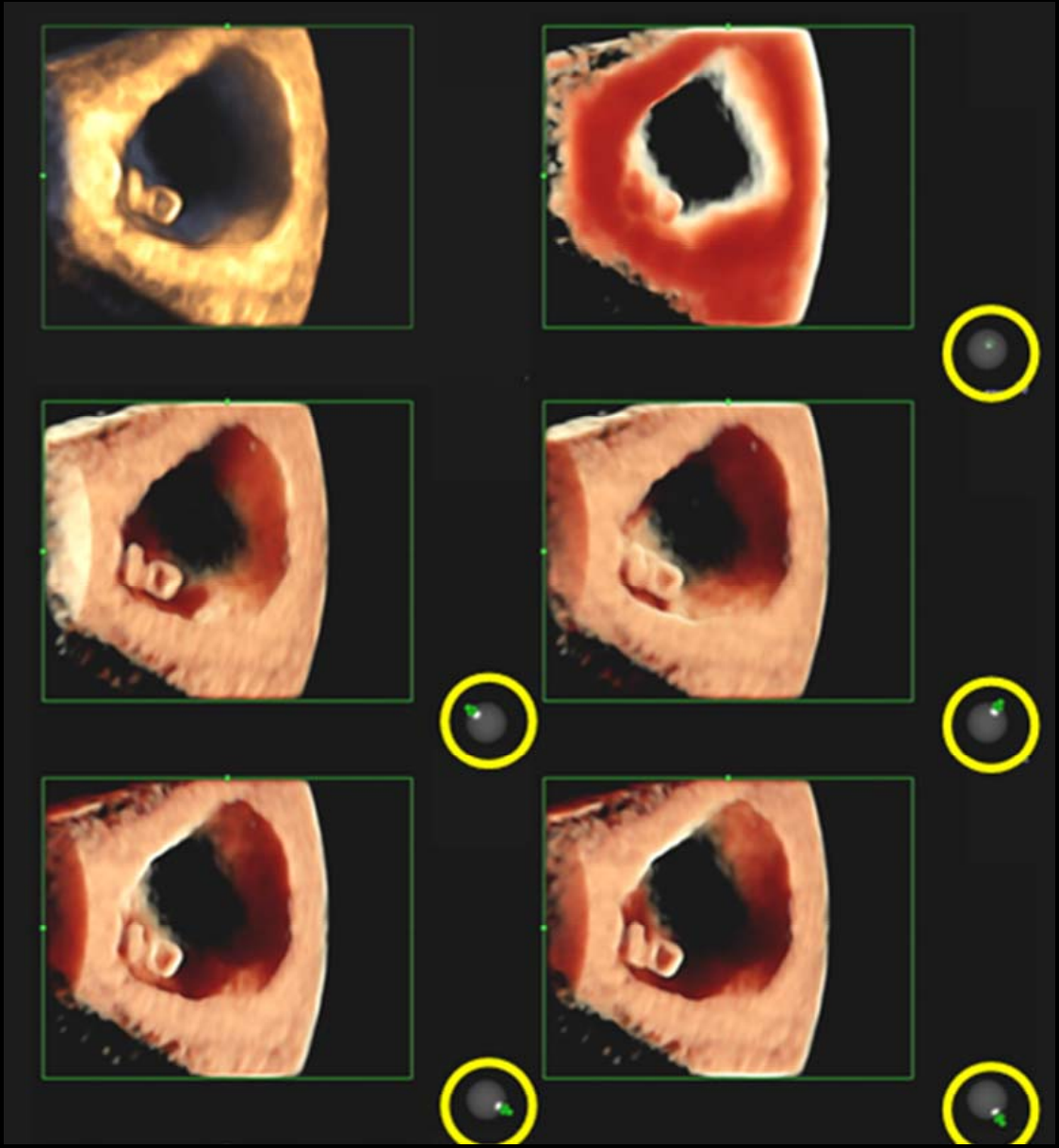
# 5 SEMANAS



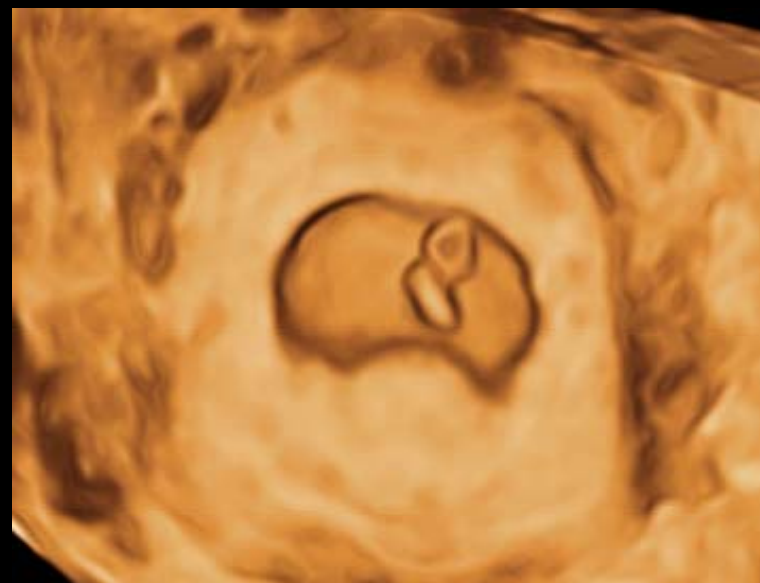
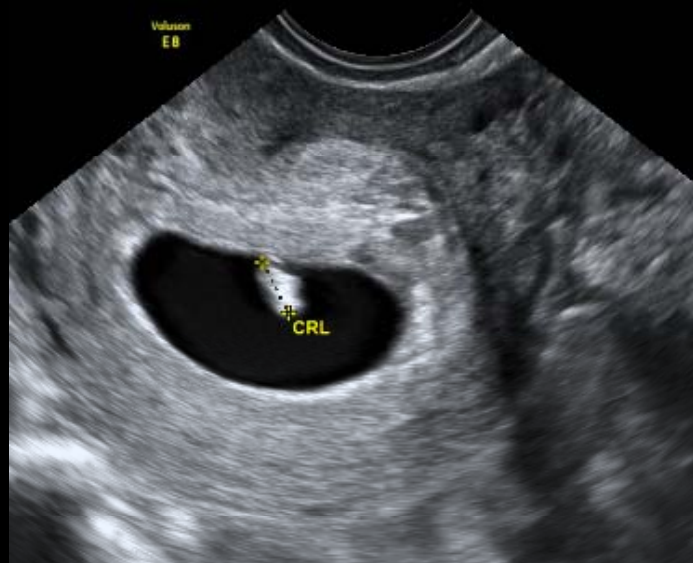


**5 SEMANAS + 3 DIAS**

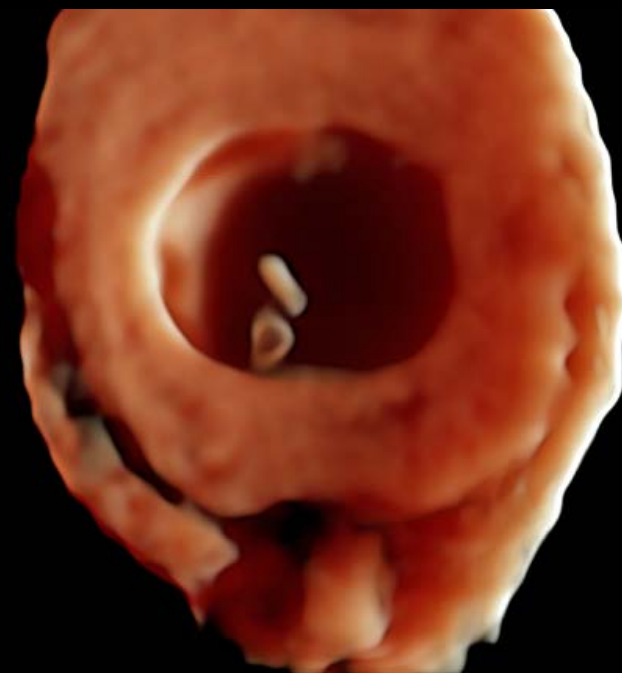
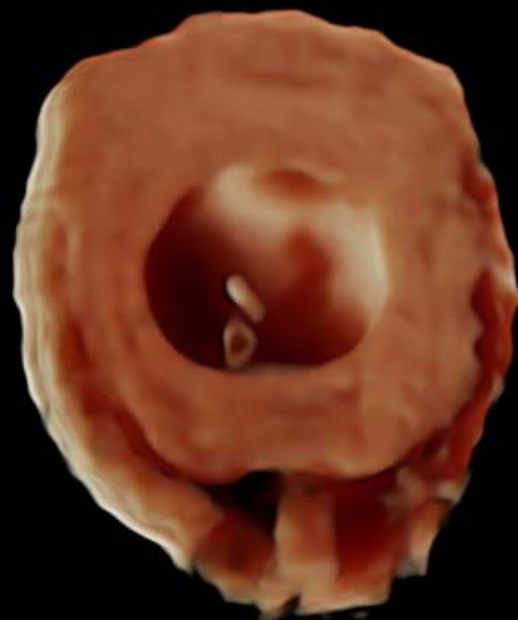


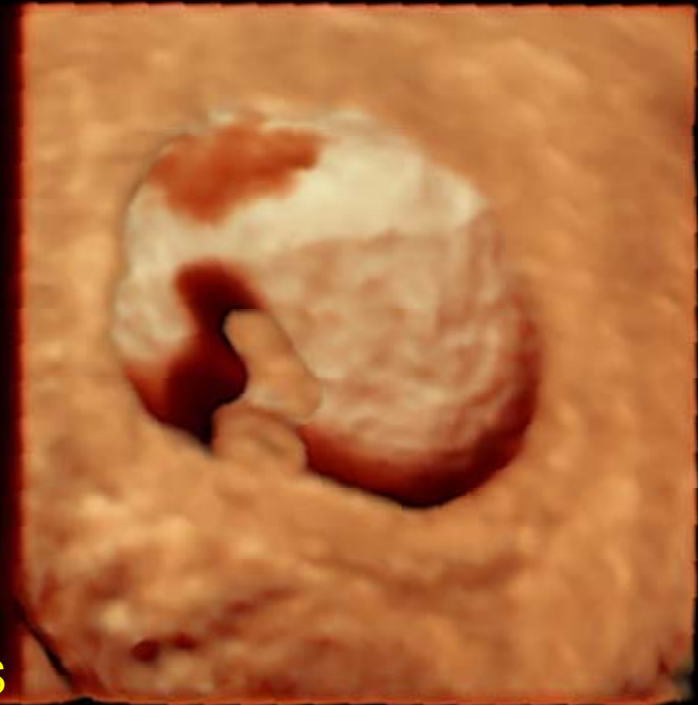
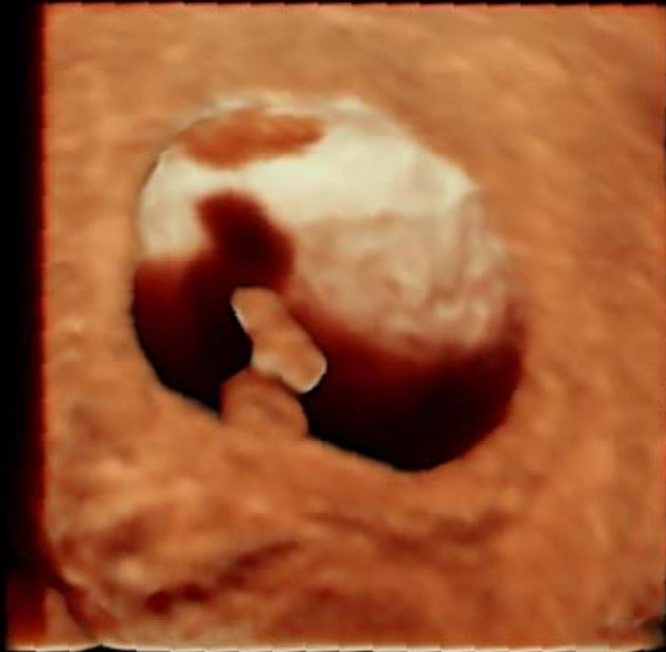**5+5  
SEMANAS**



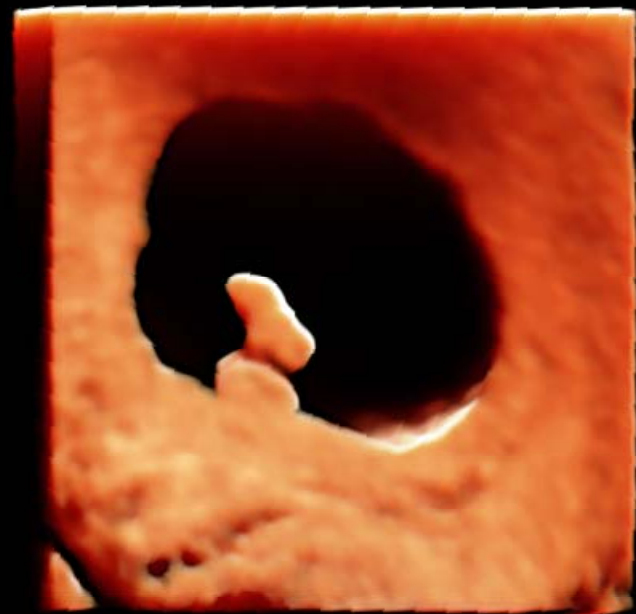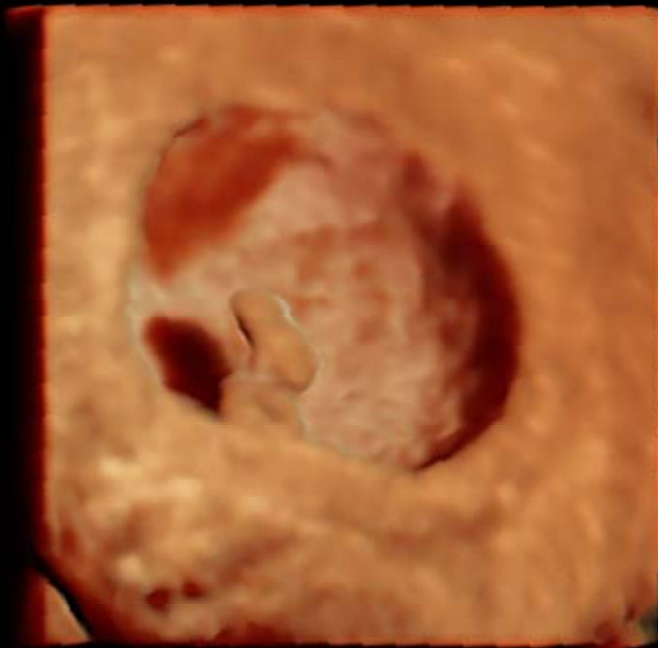
**5+6 SEMANAS**

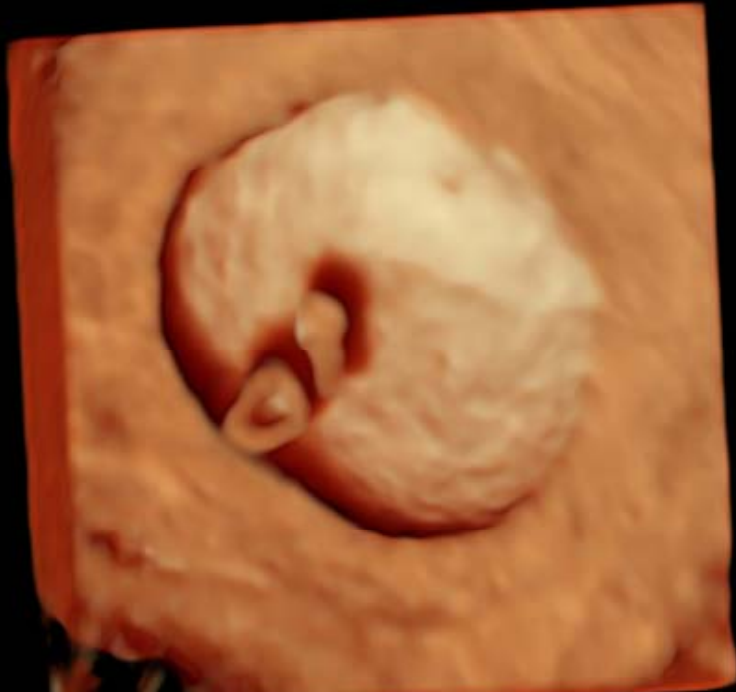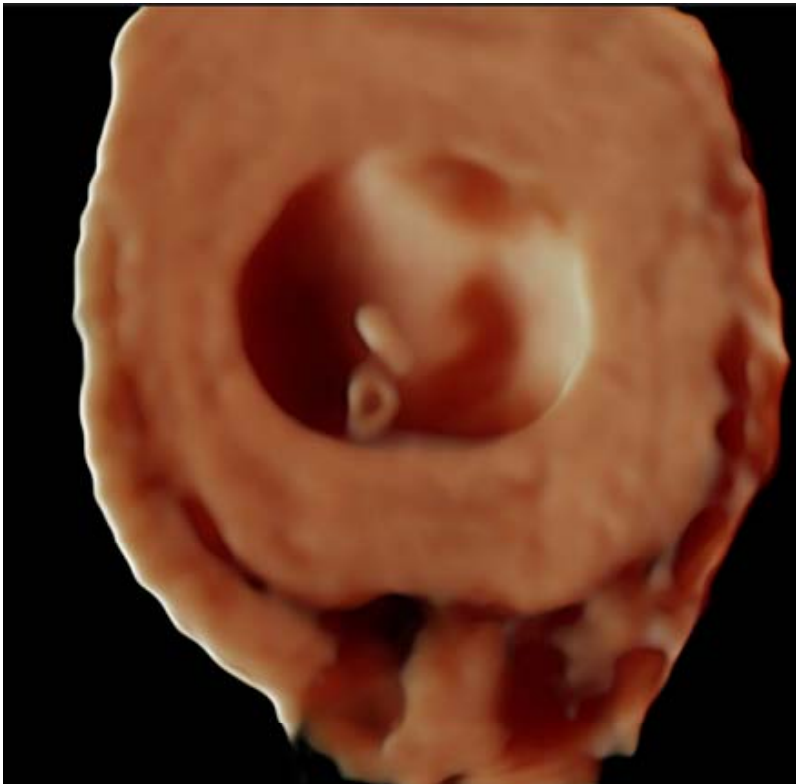




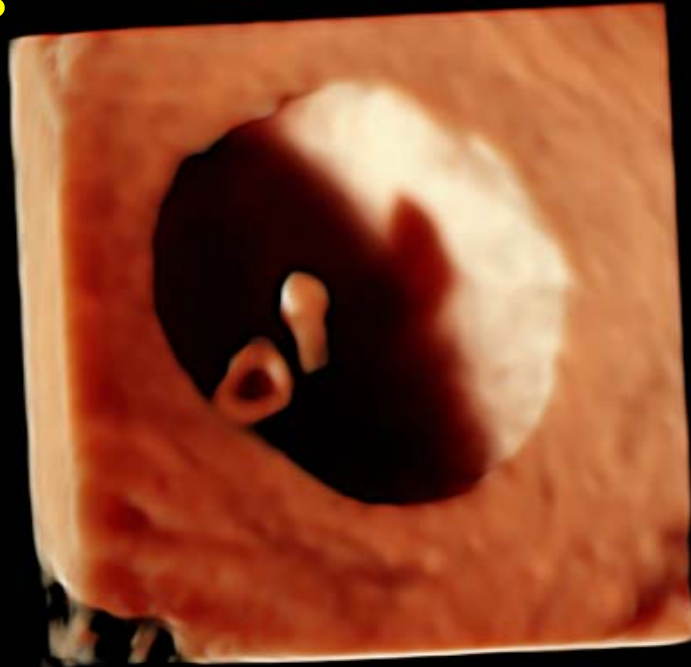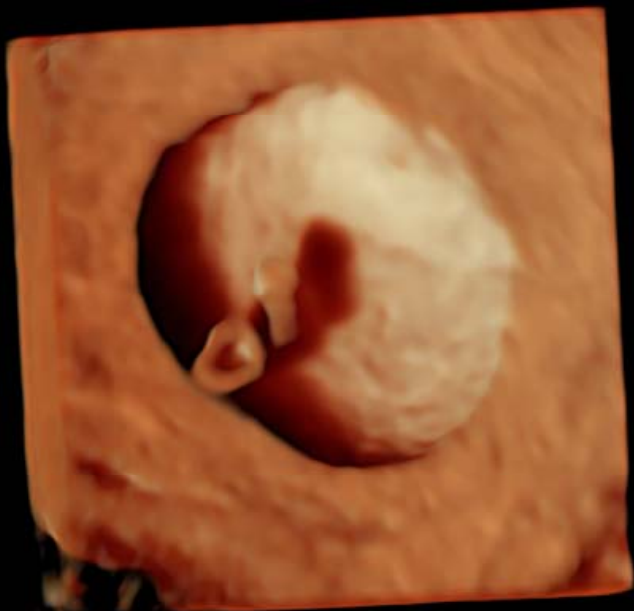


6 SEMANAS

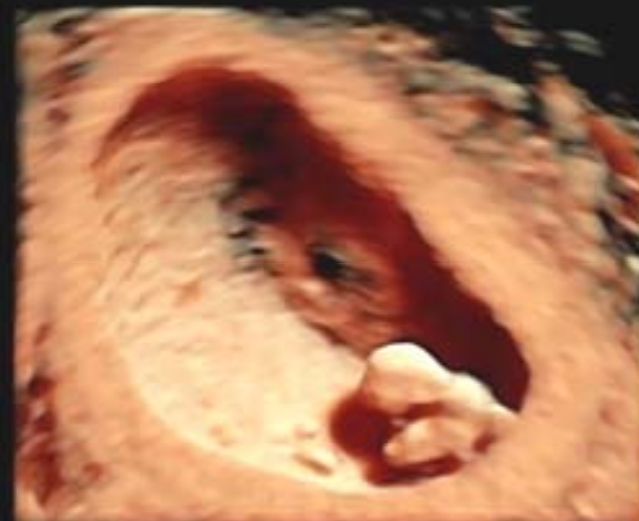
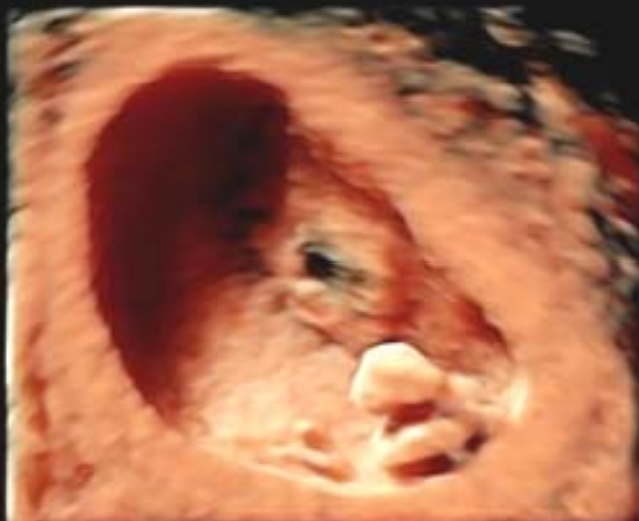
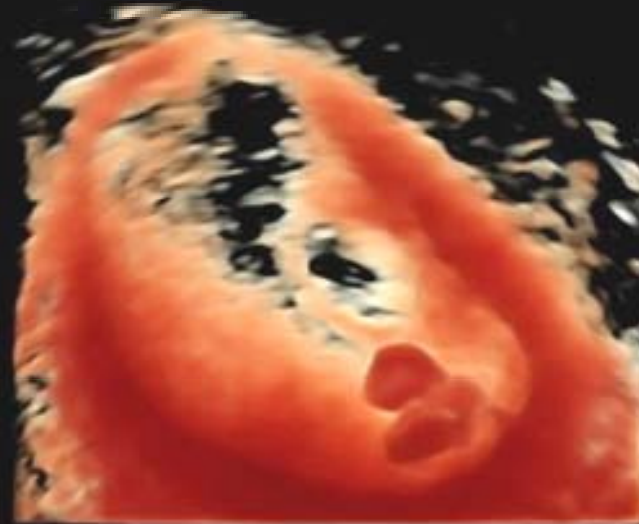
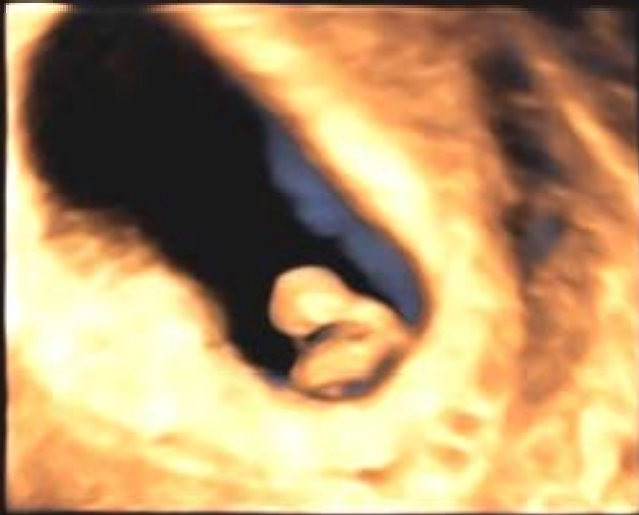


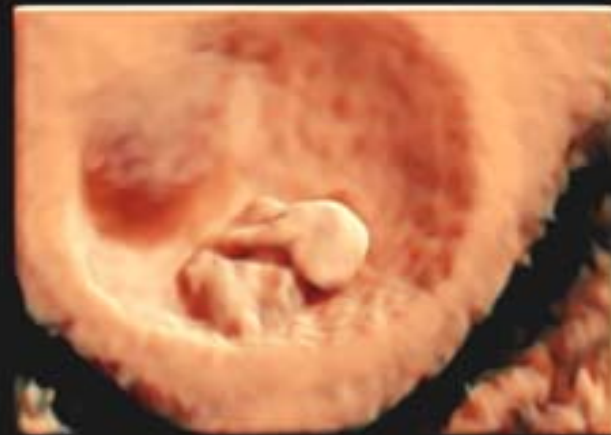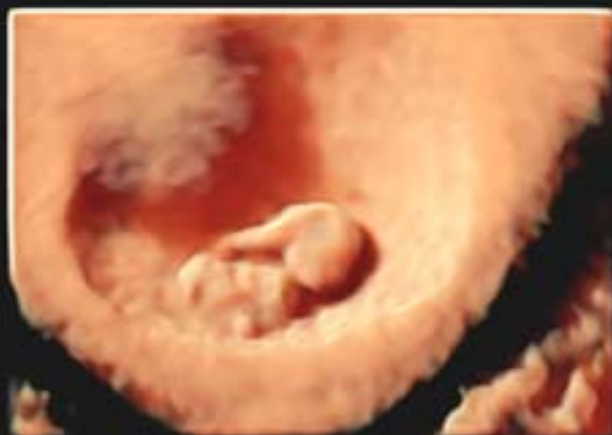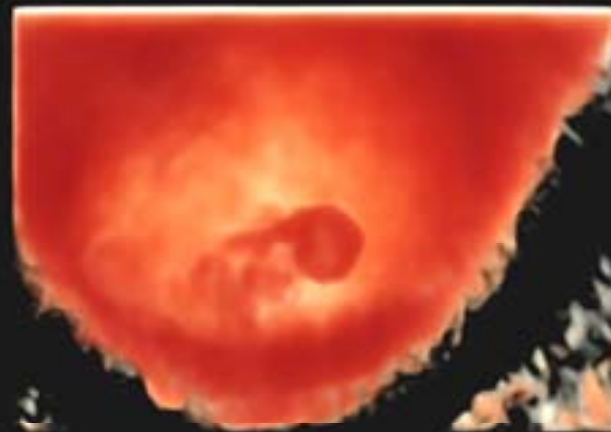
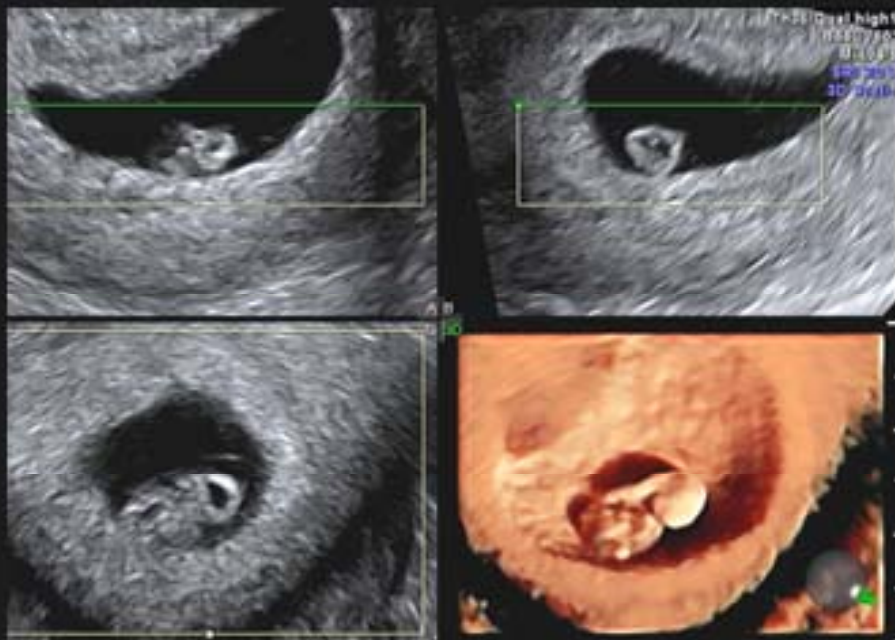


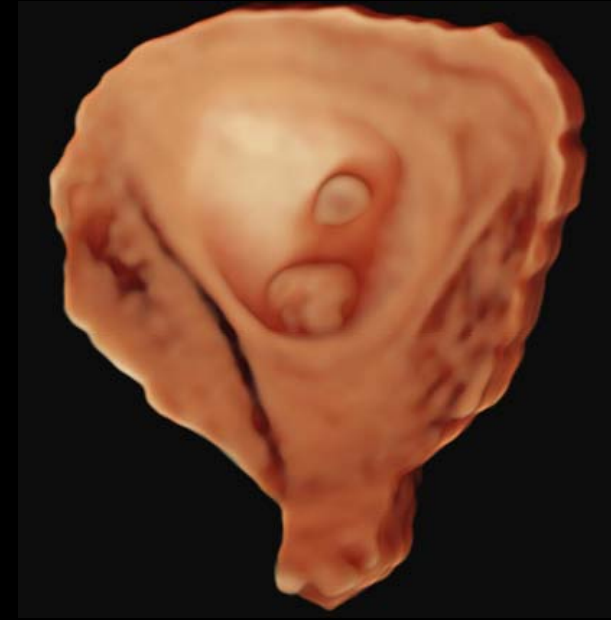
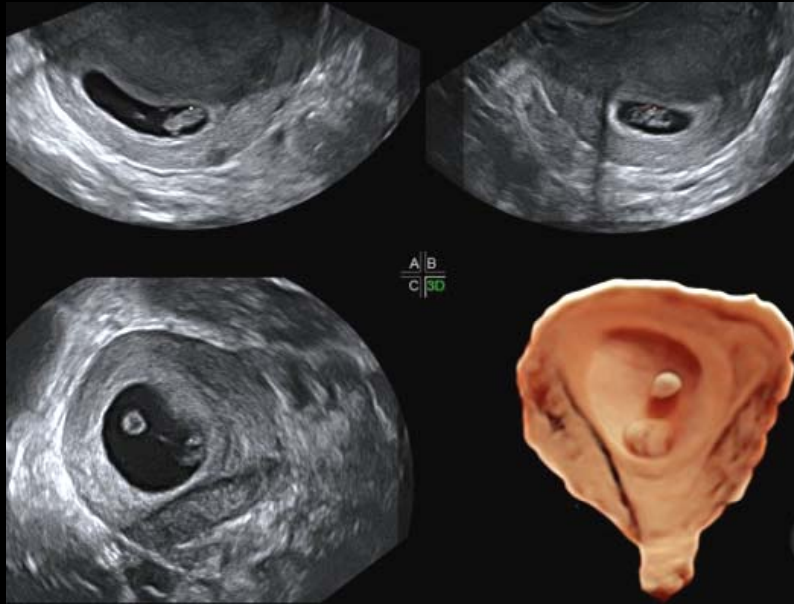
6 SEMANAS



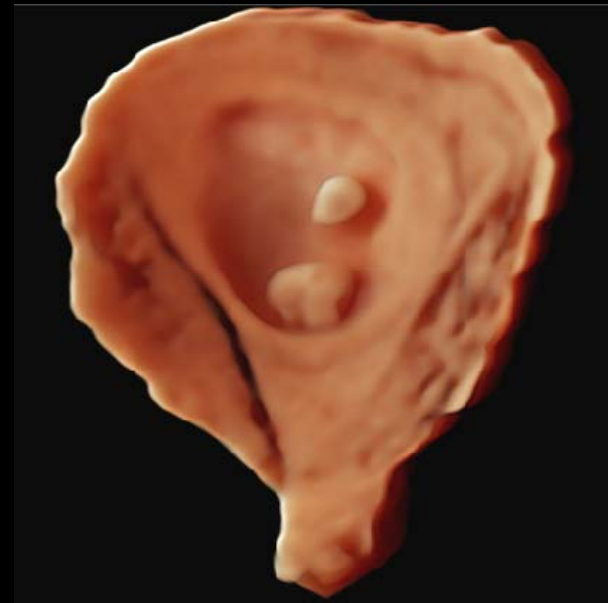
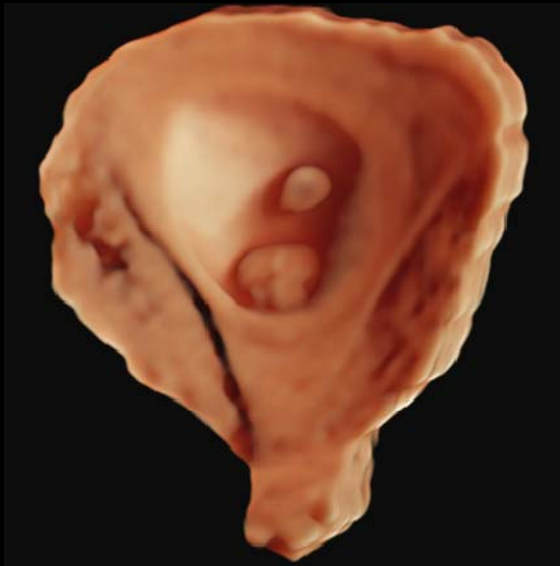
# 6 SEMANAS + 2 DIAS

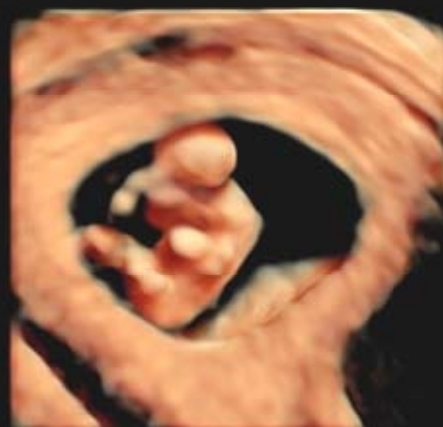
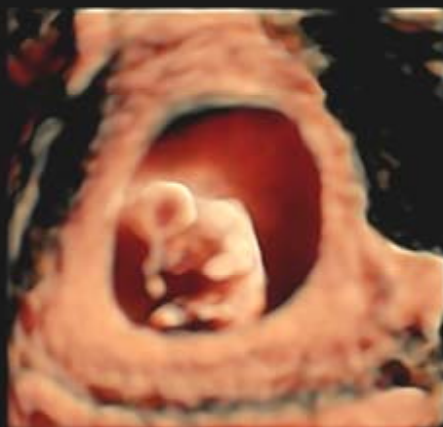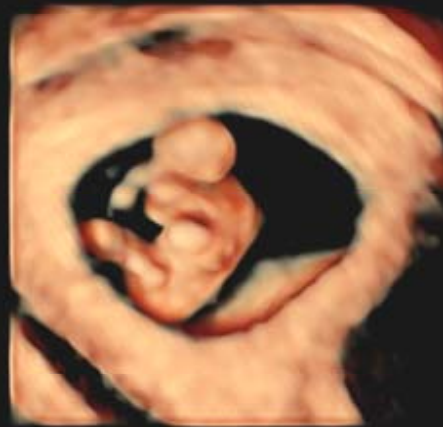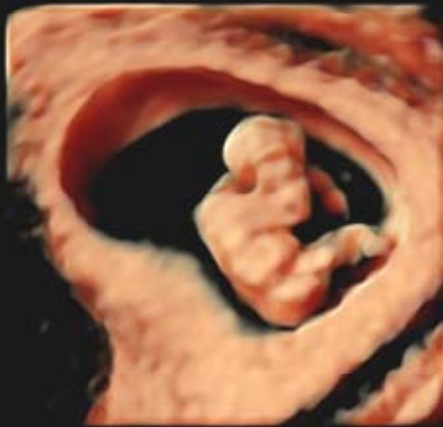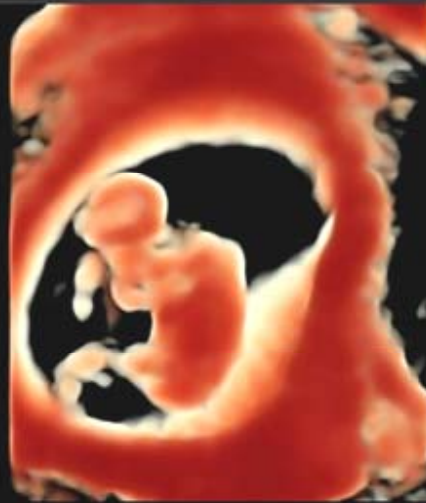



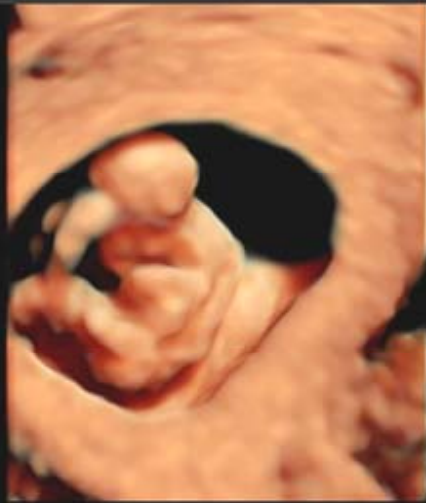
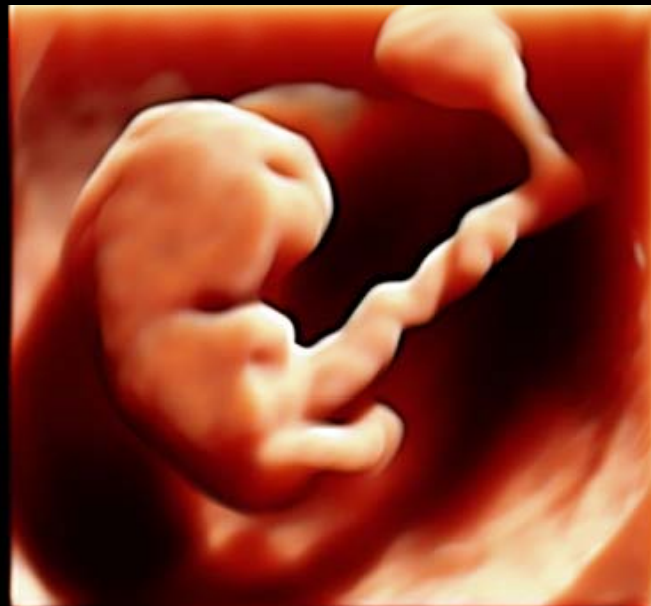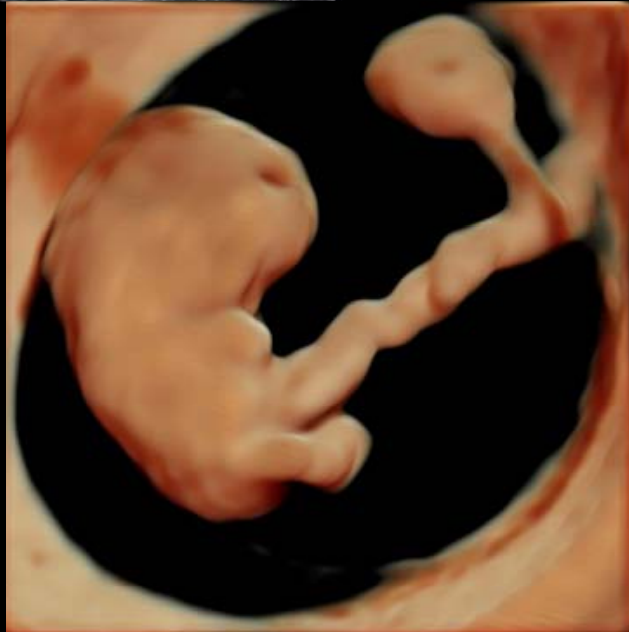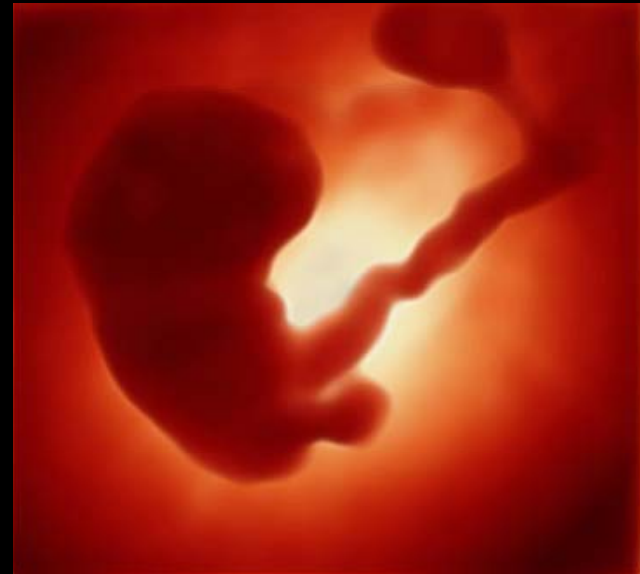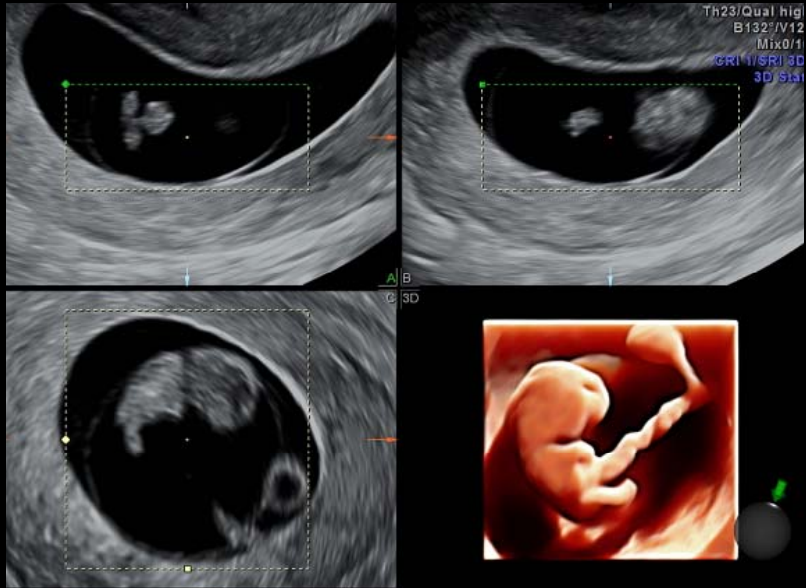


**7 SEMANAS**



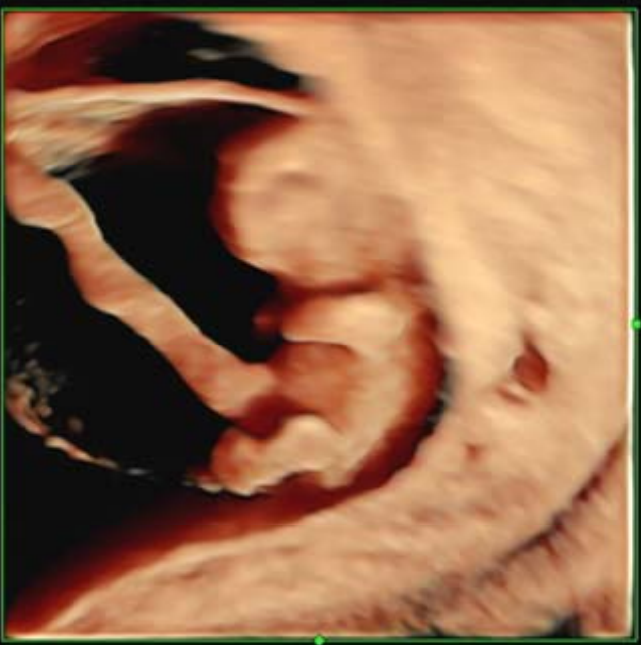
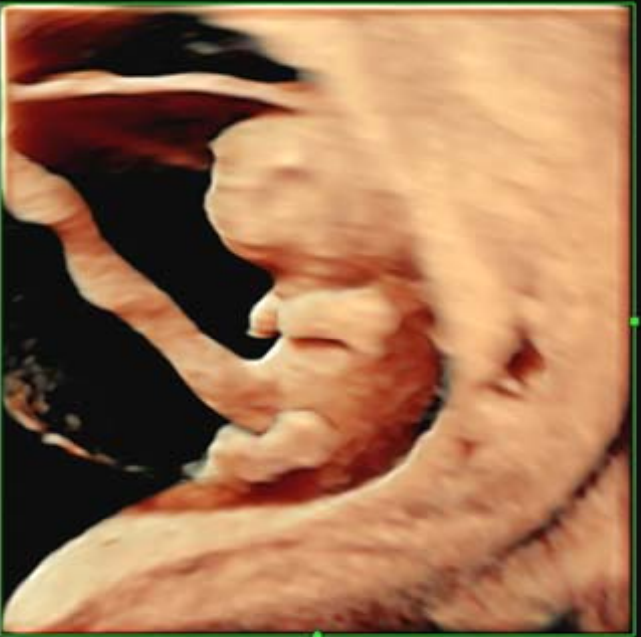
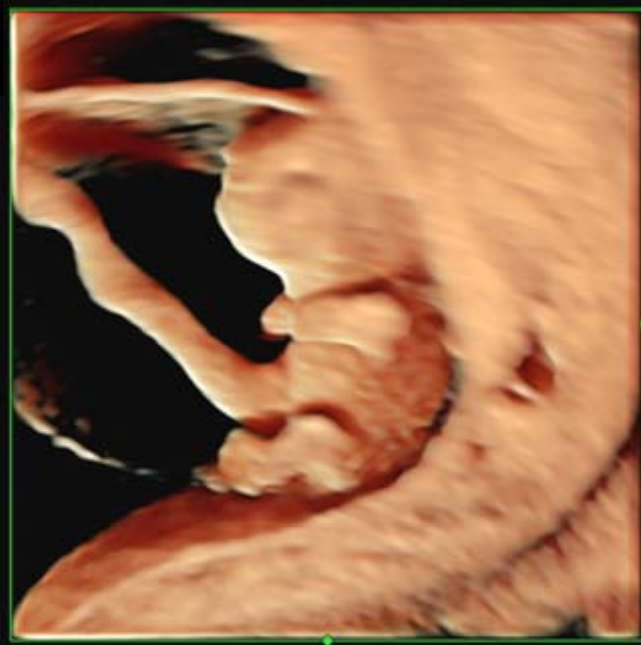
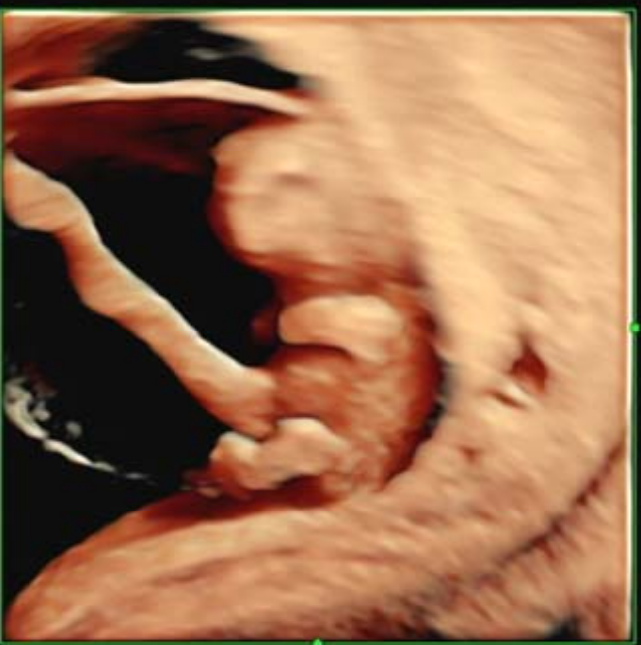

**7**  
**semanas**




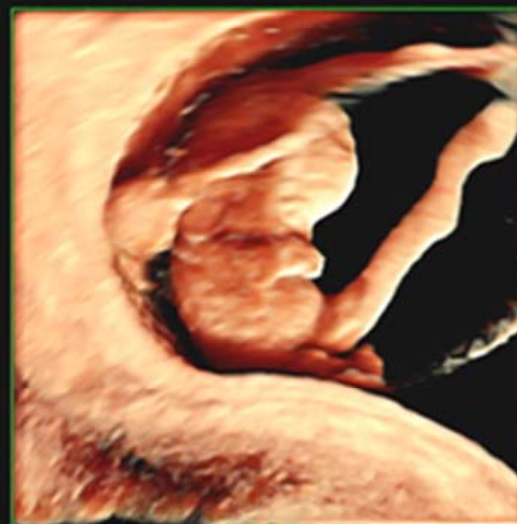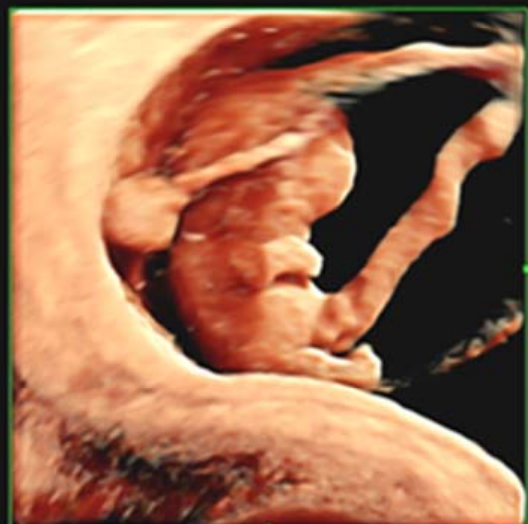
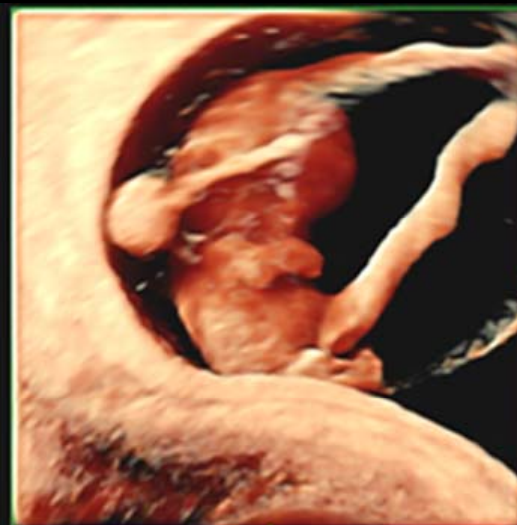
8 + 6

9 SEMANAS



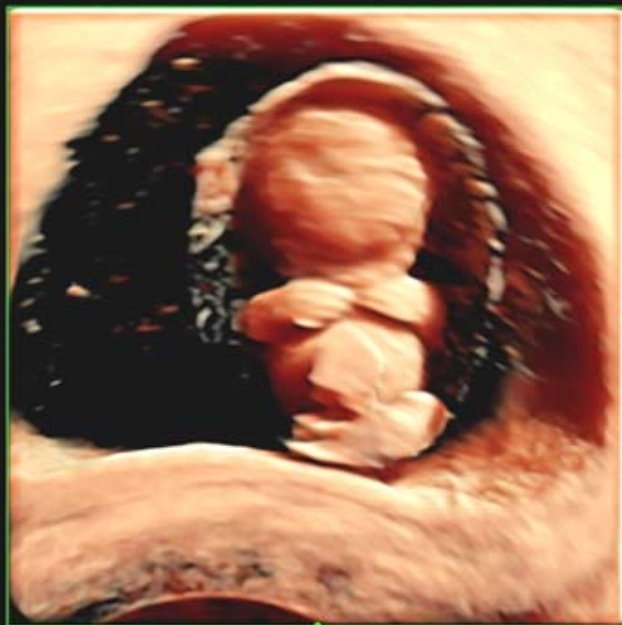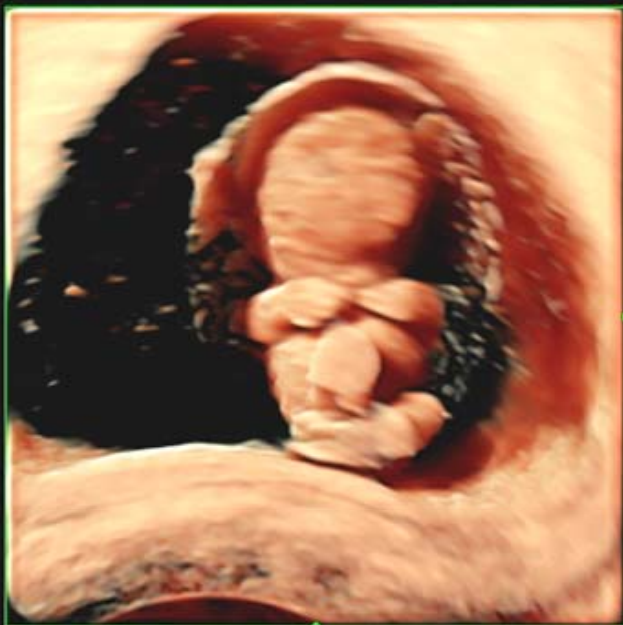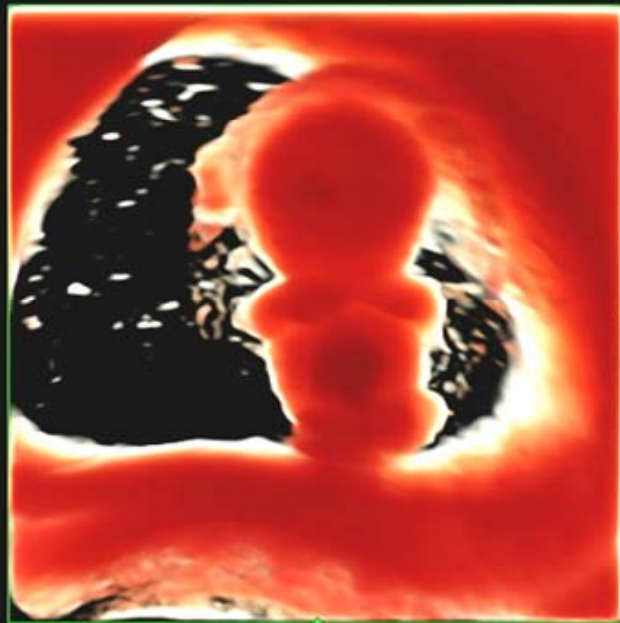
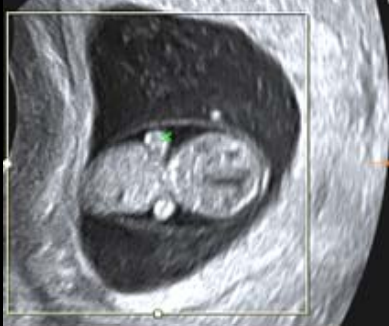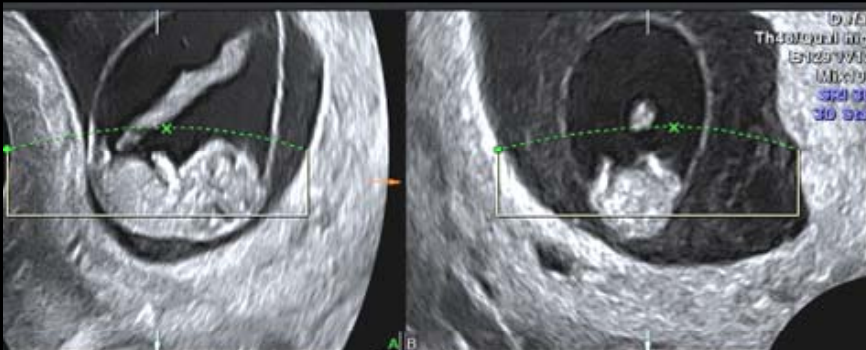


**9 SEMANAS**



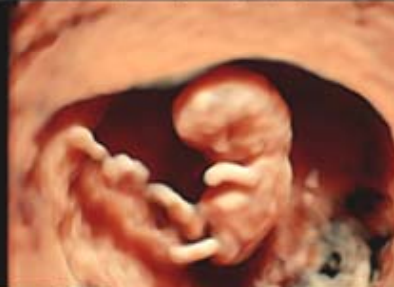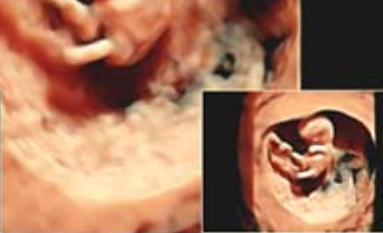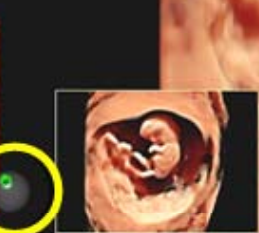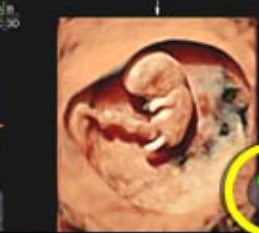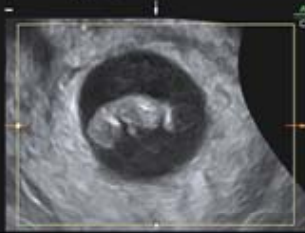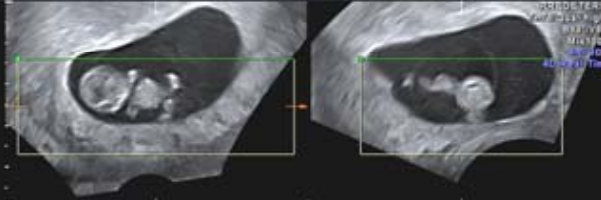
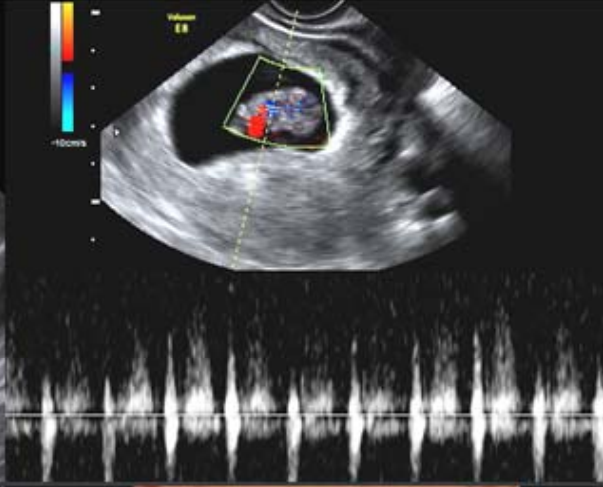
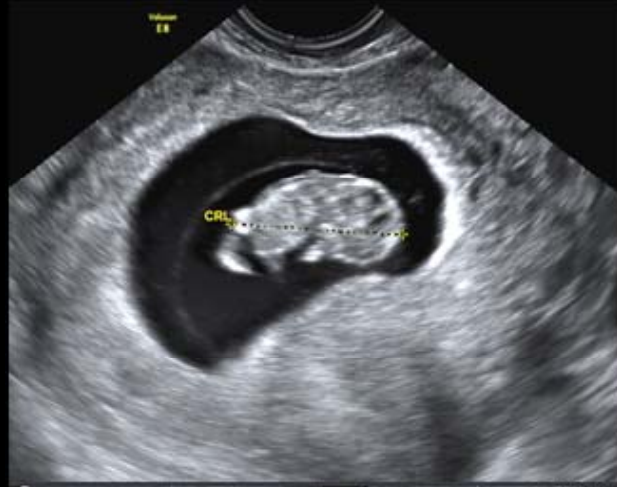10

S  
E  
M  
A  
N  
S

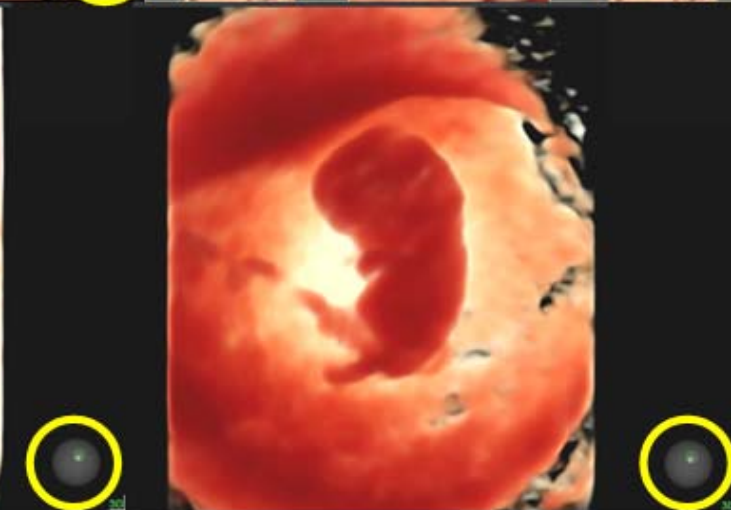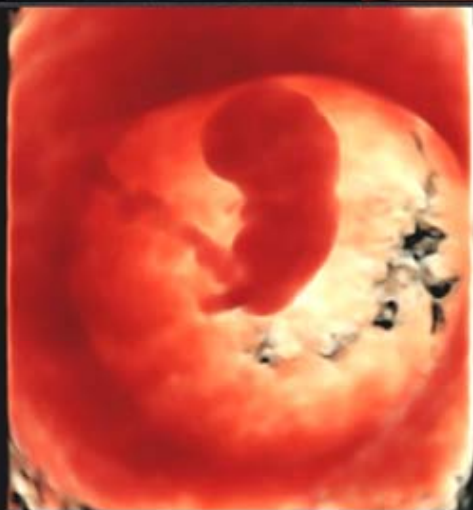


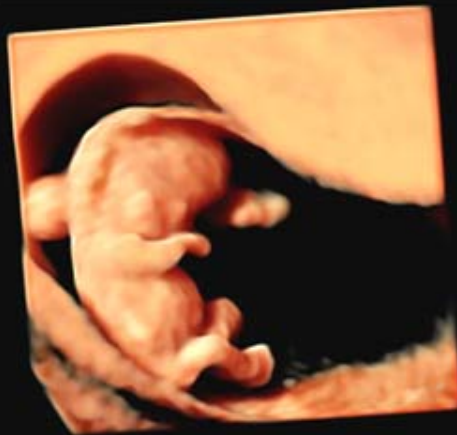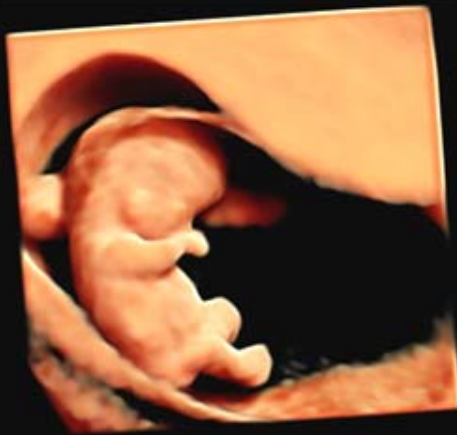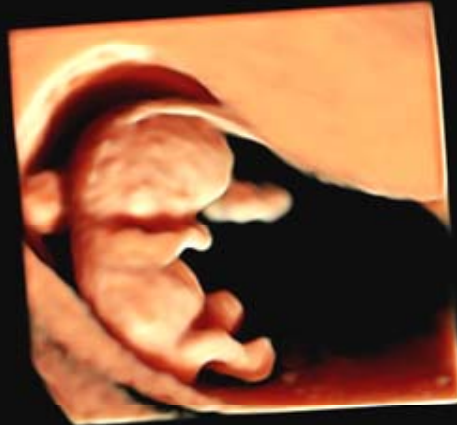
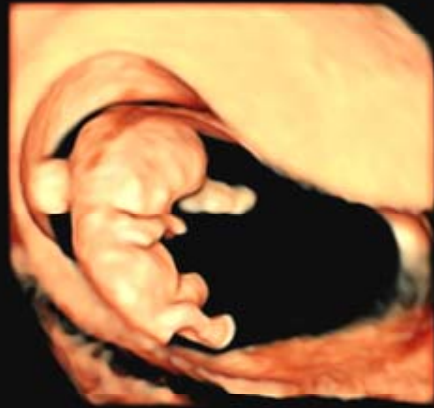
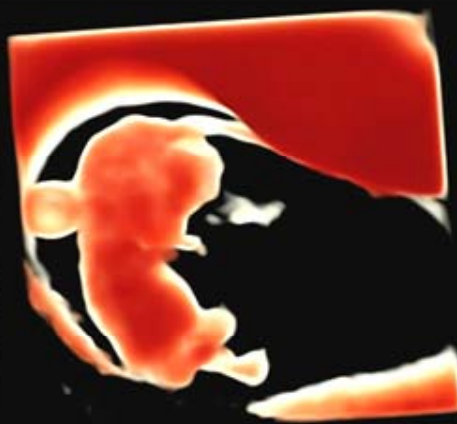
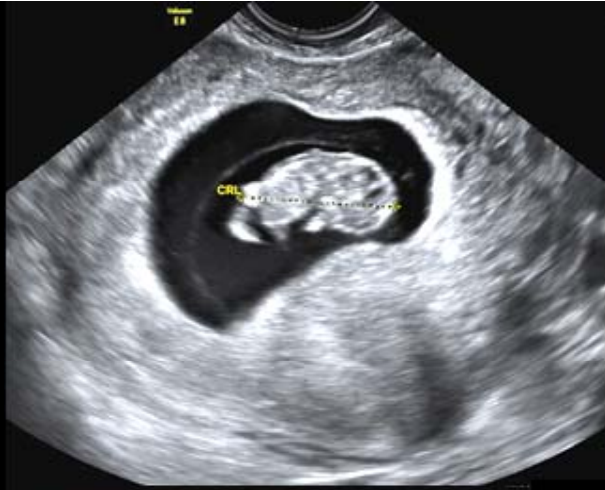3d

3d



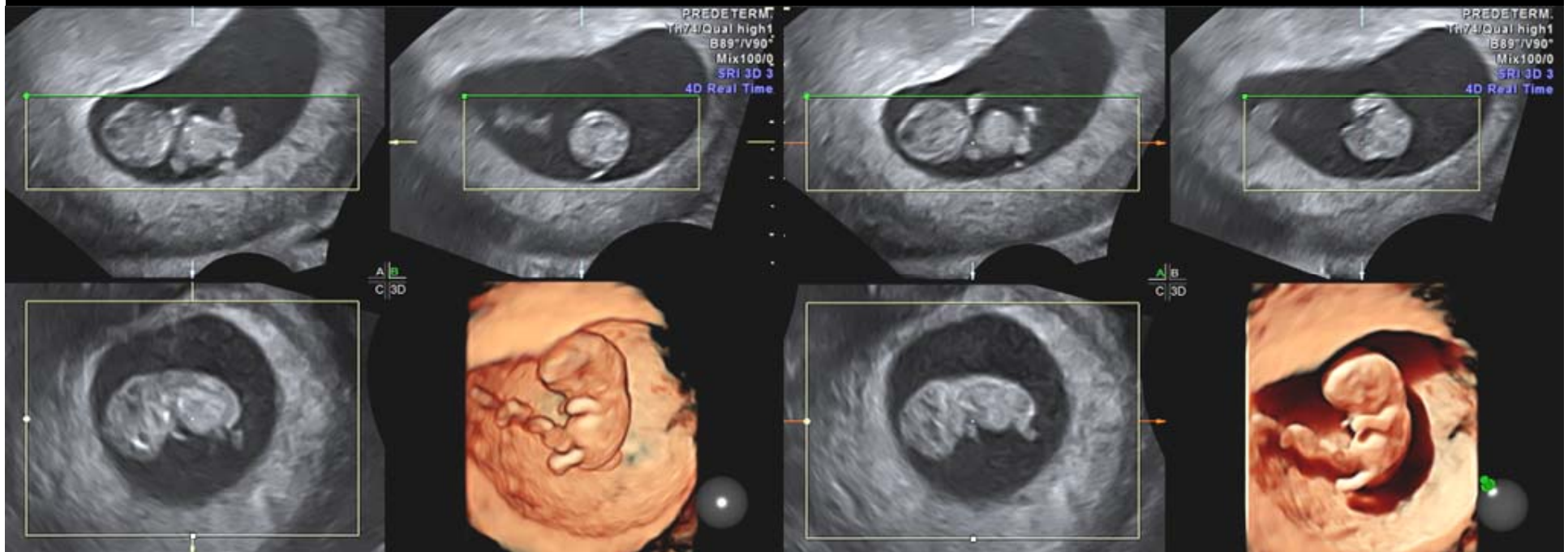
**10  
SEMANAS**

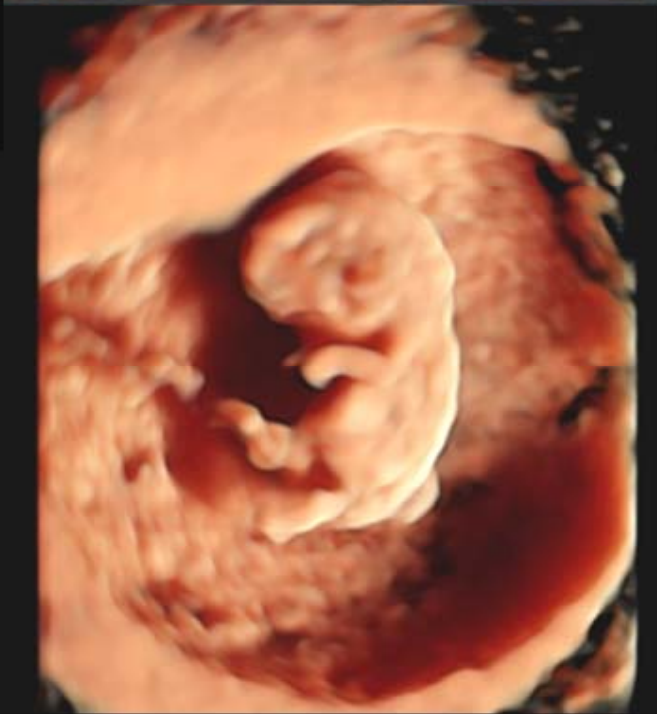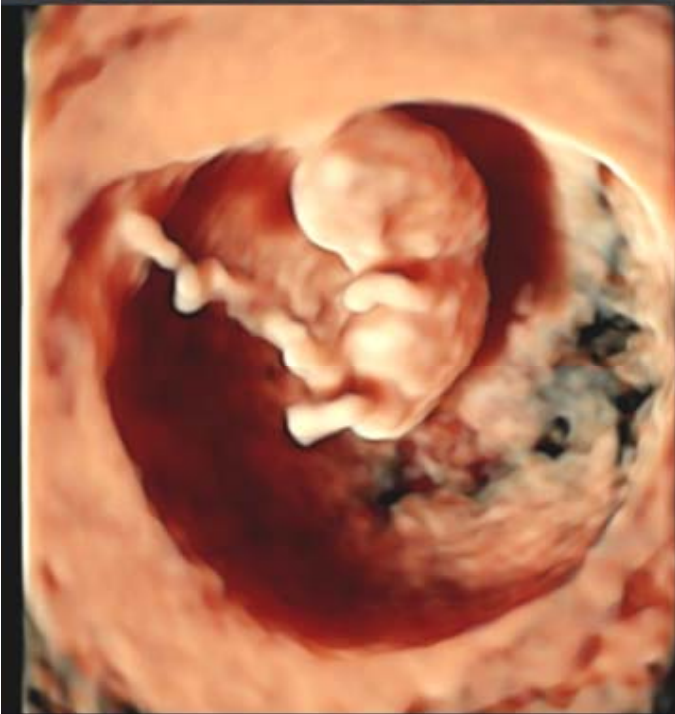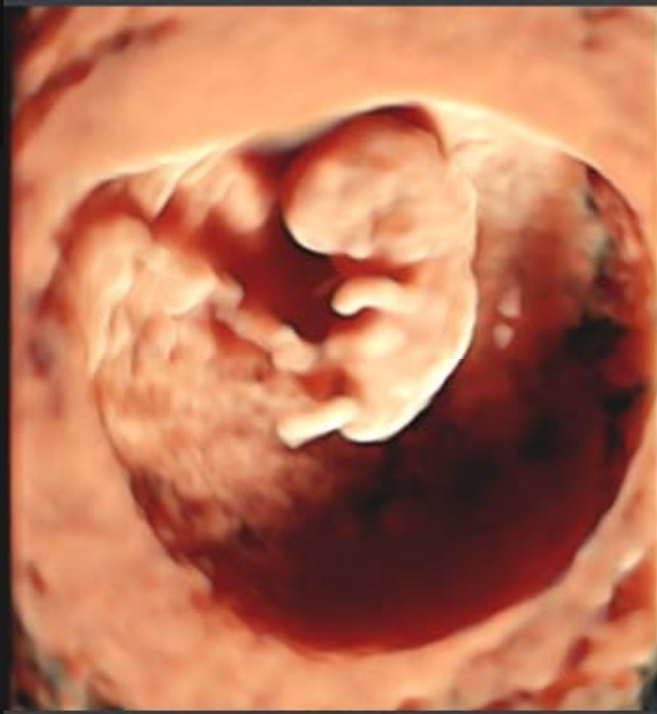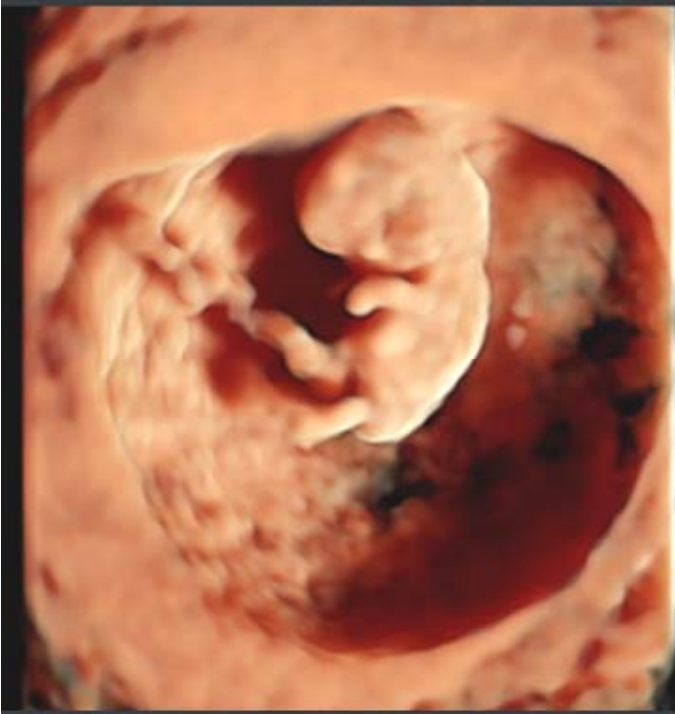


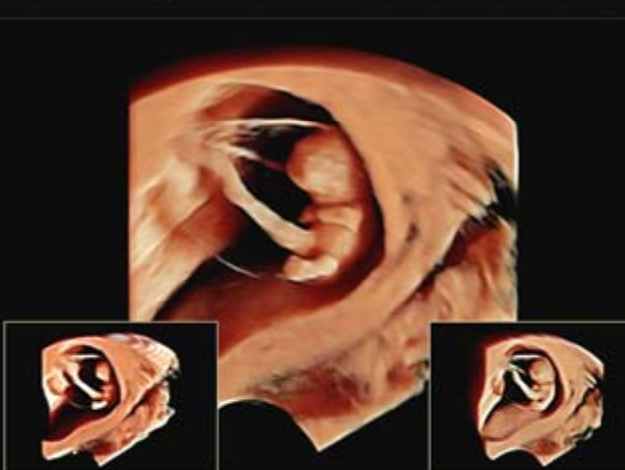
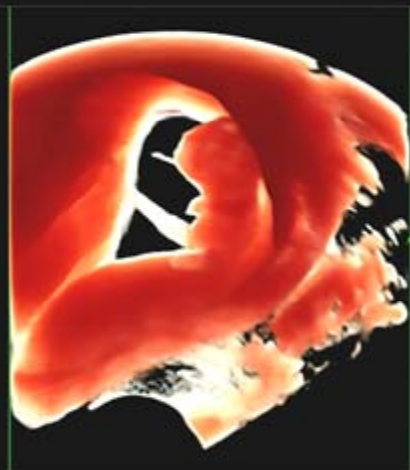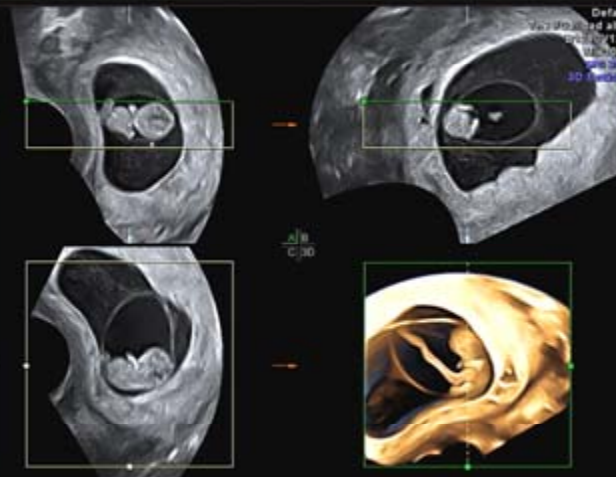
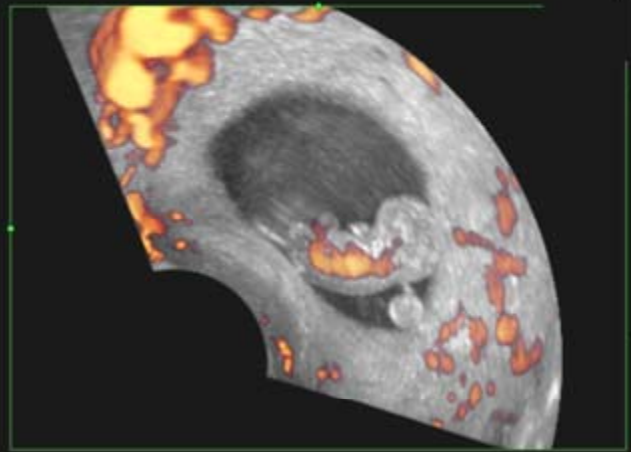
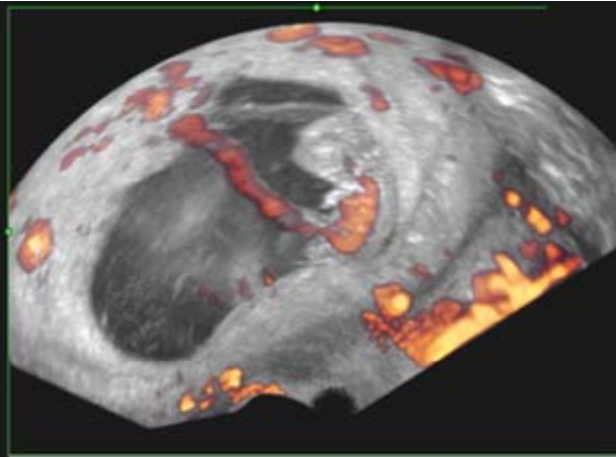
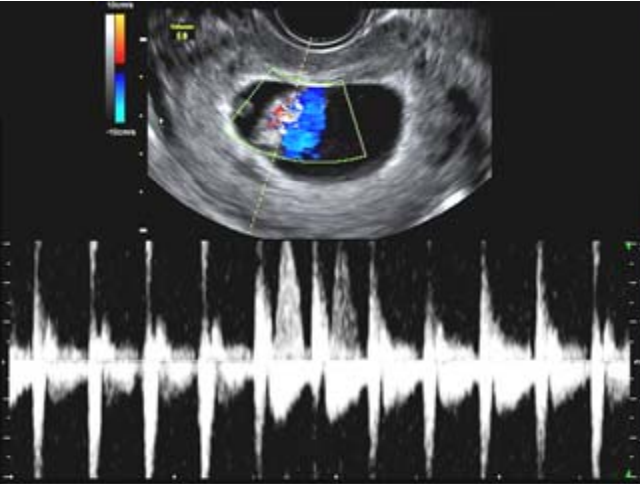


**10  
SEMANAS**

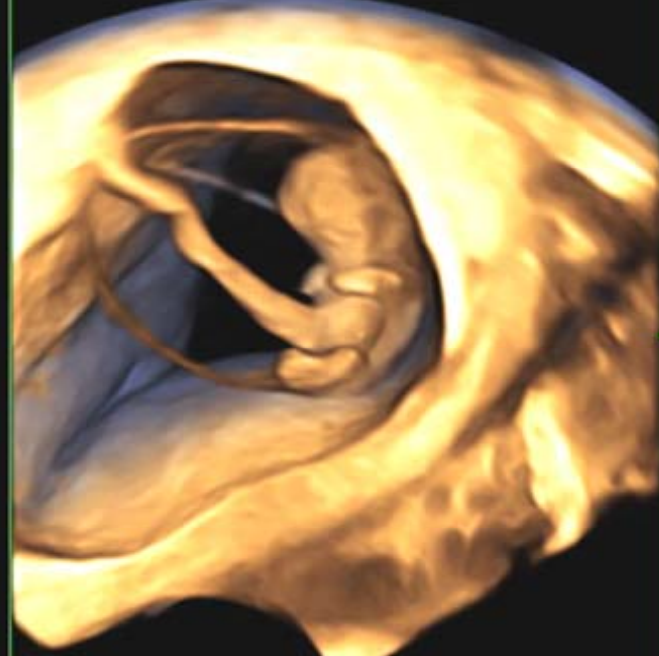
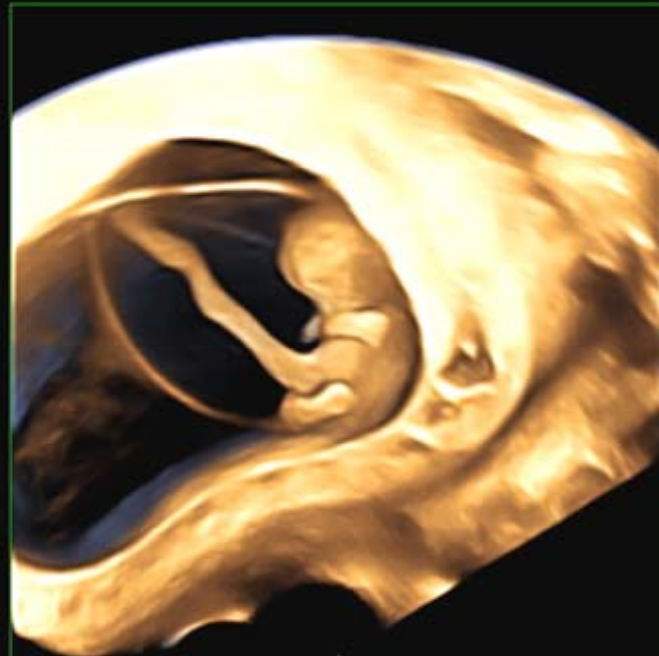
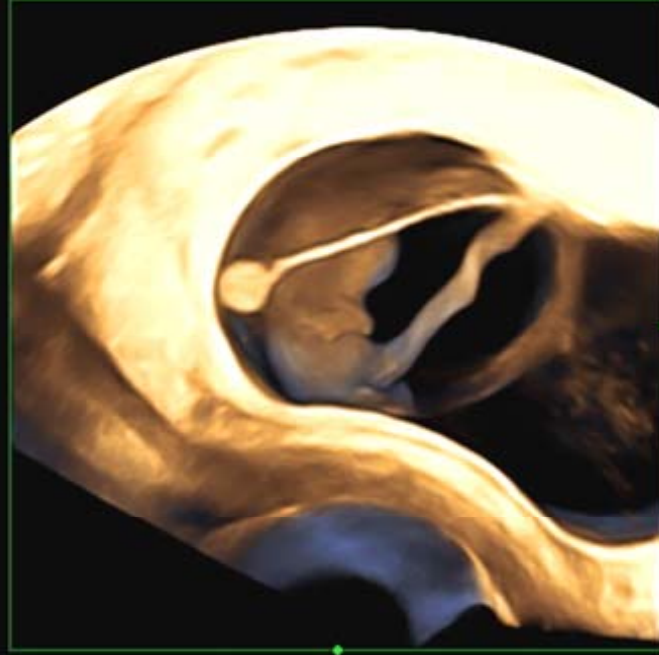
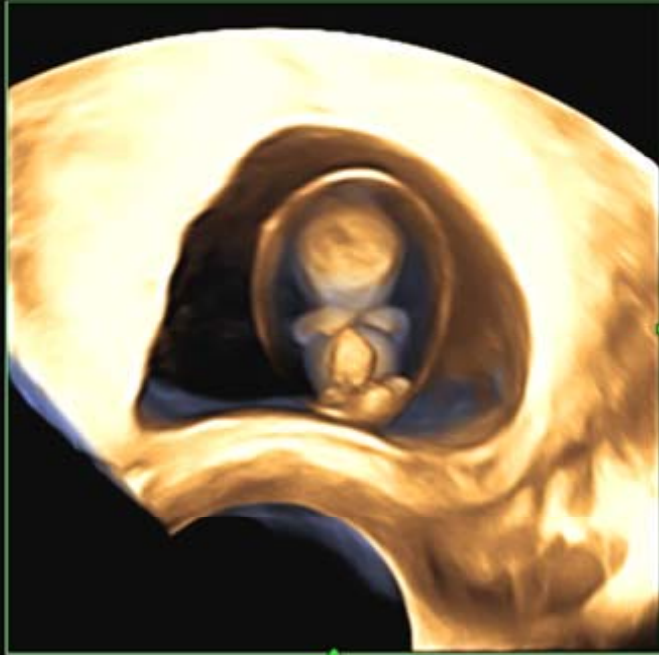
# 10 SEMANAS



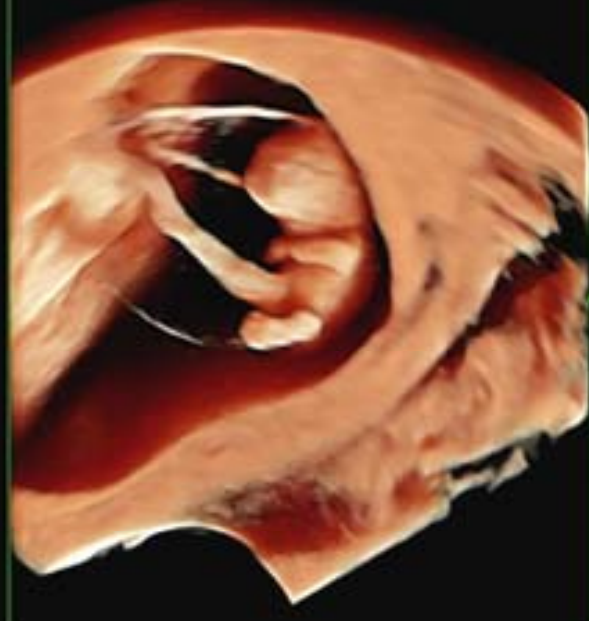
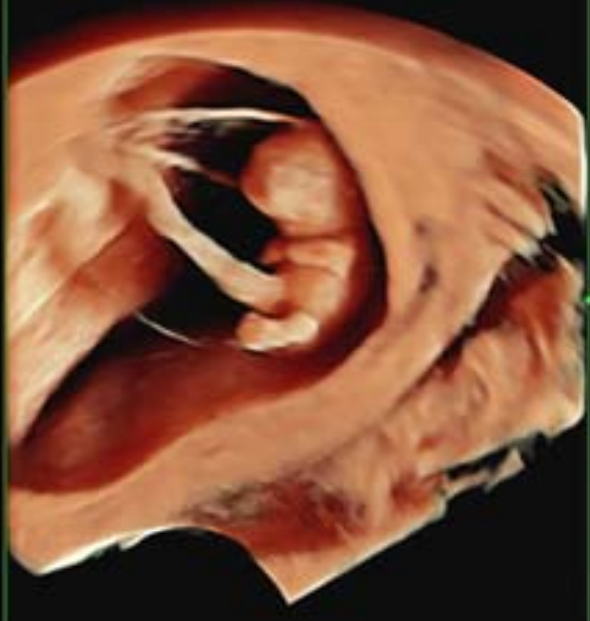
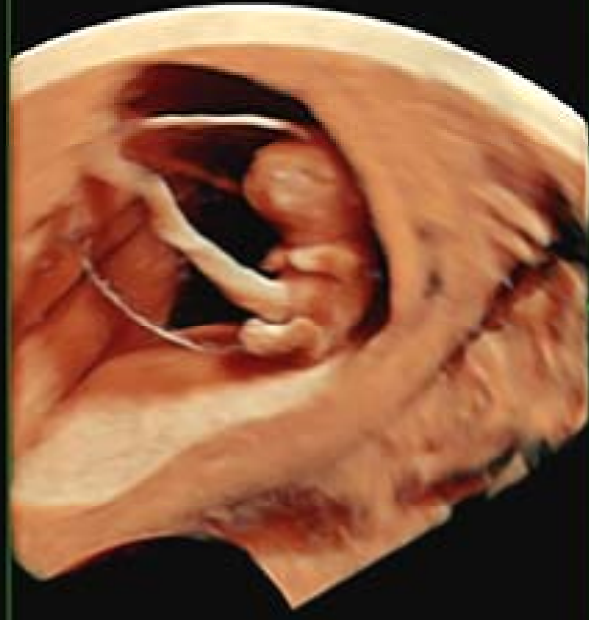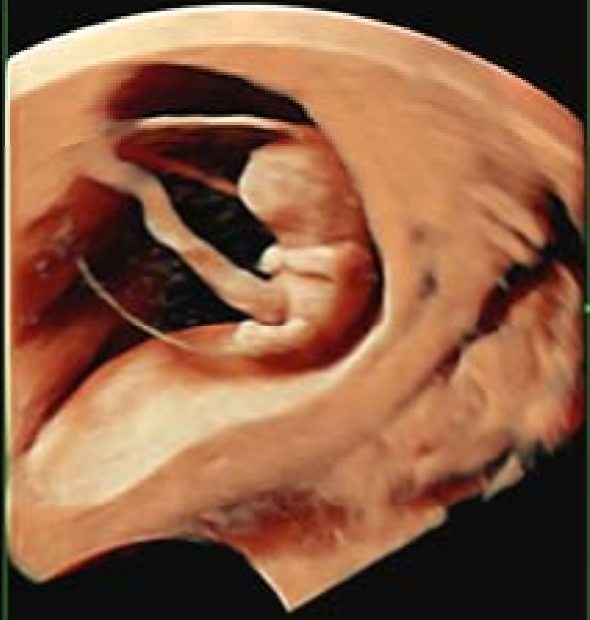



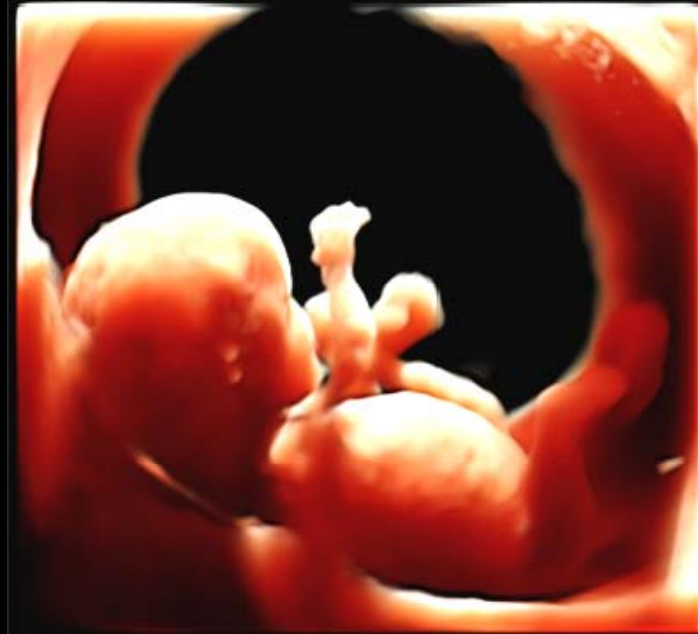
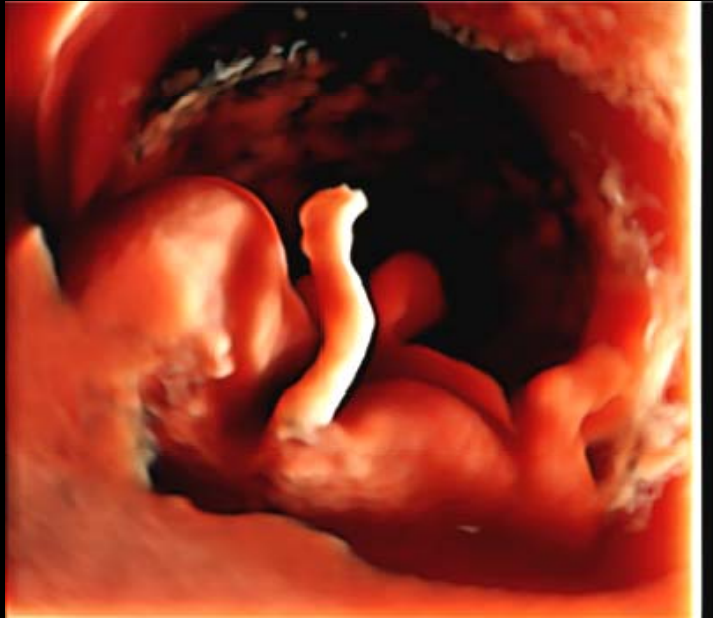11  
SEMANAS

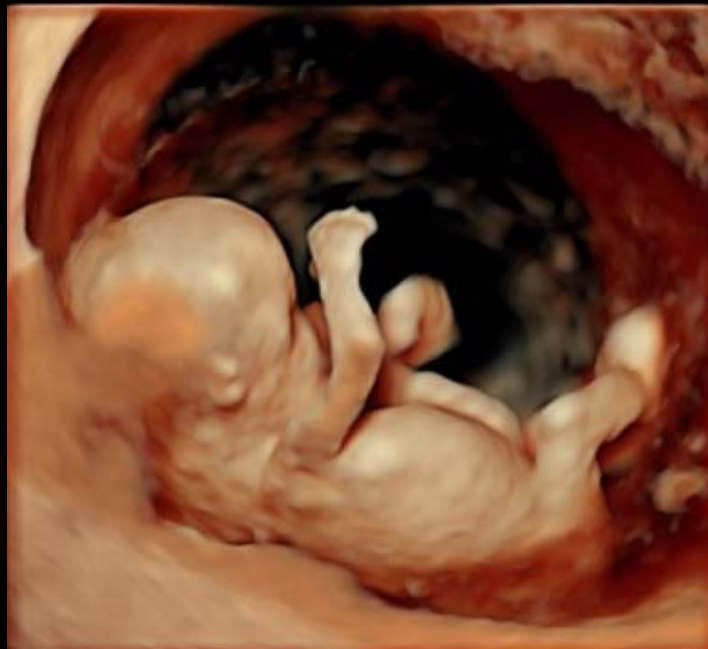


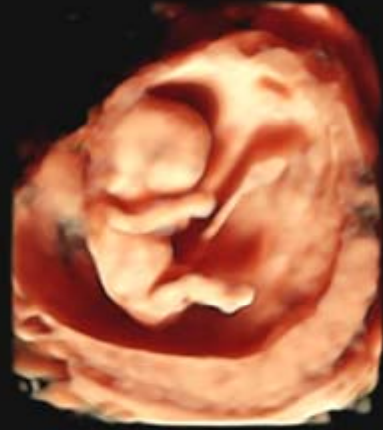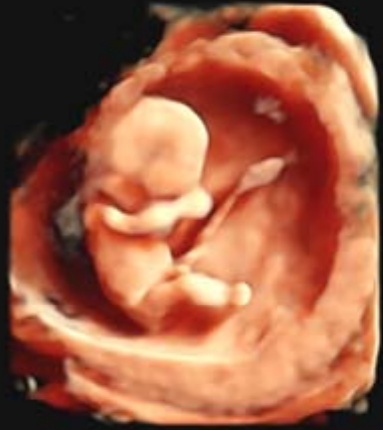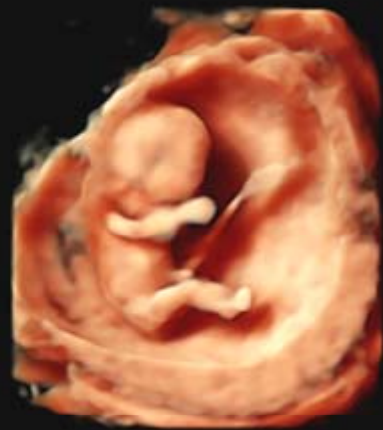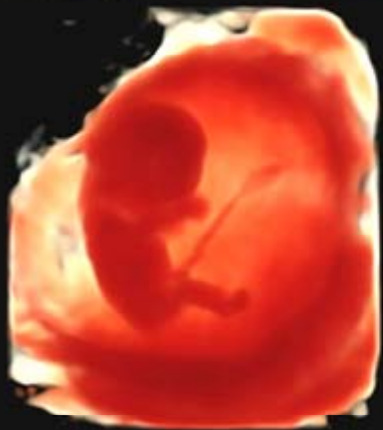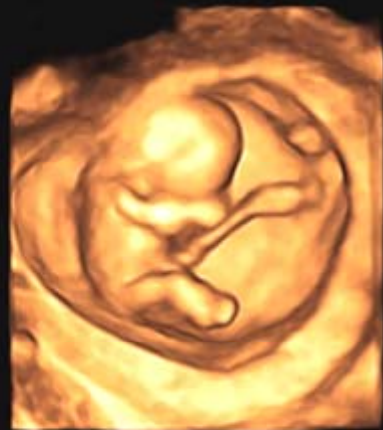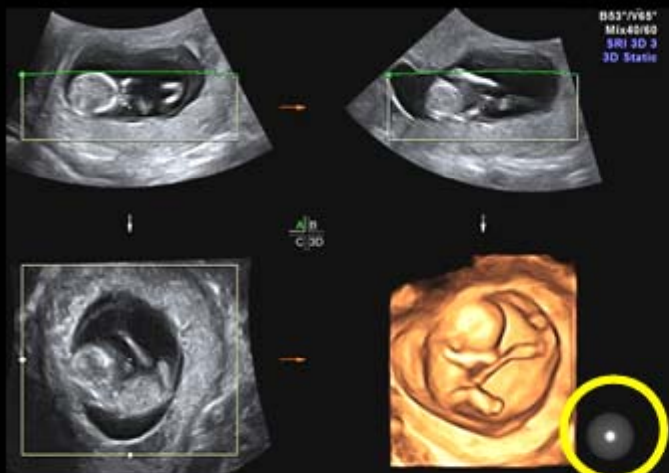






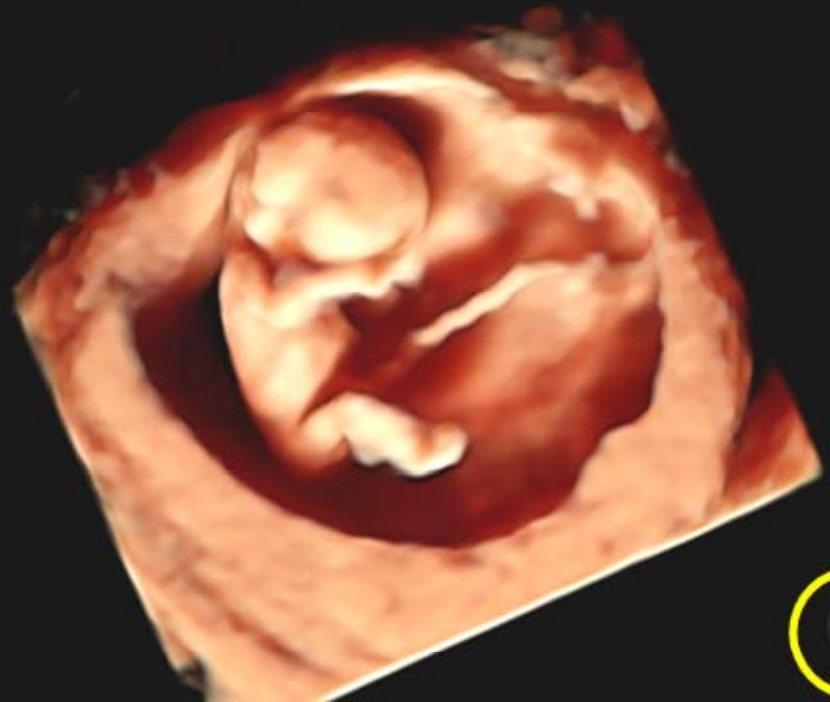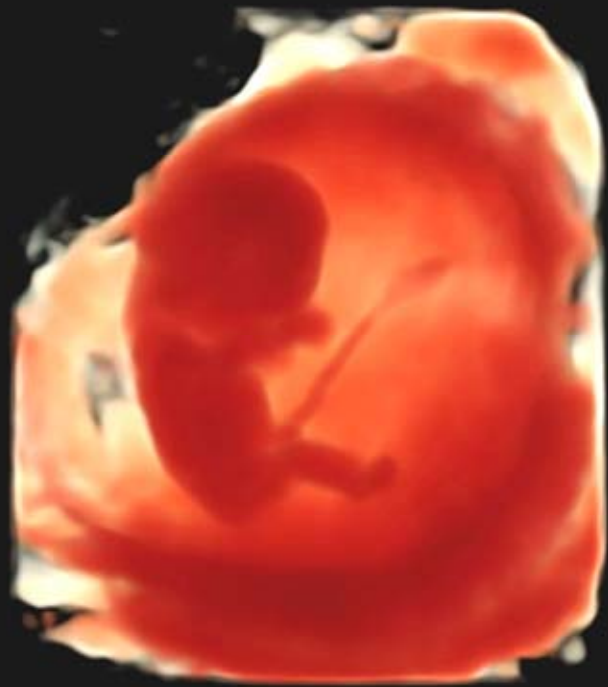**12 Schw. W**

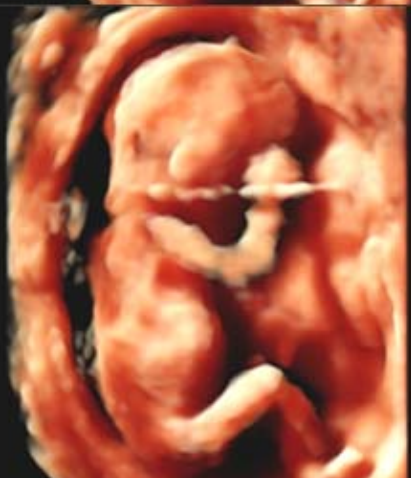
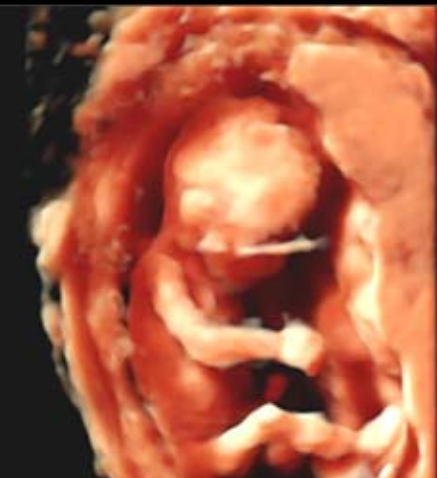
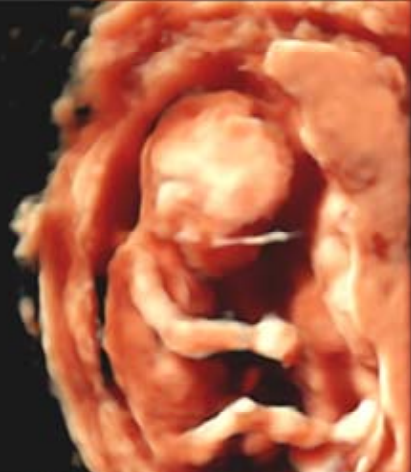
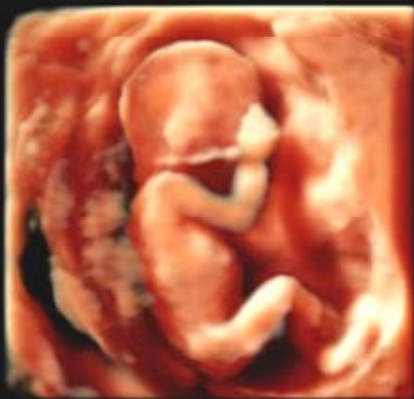
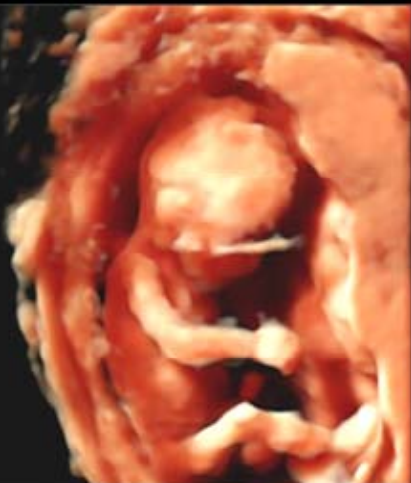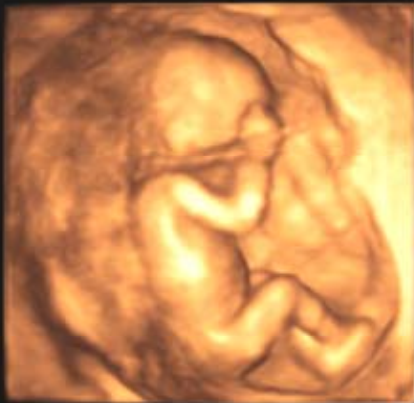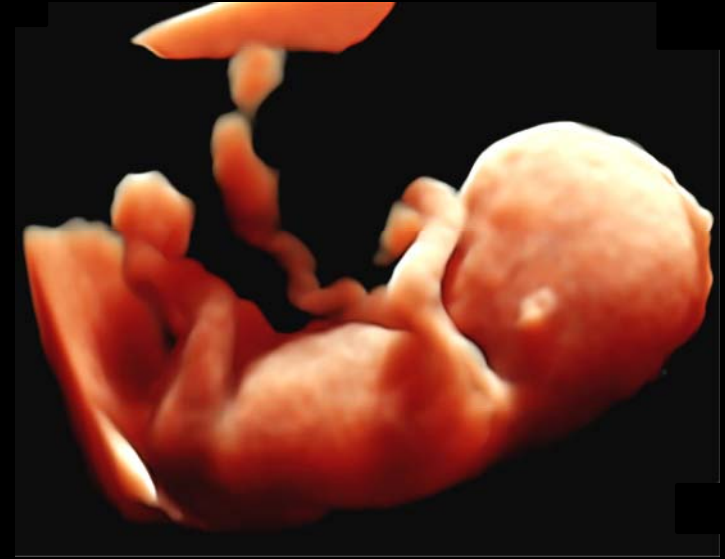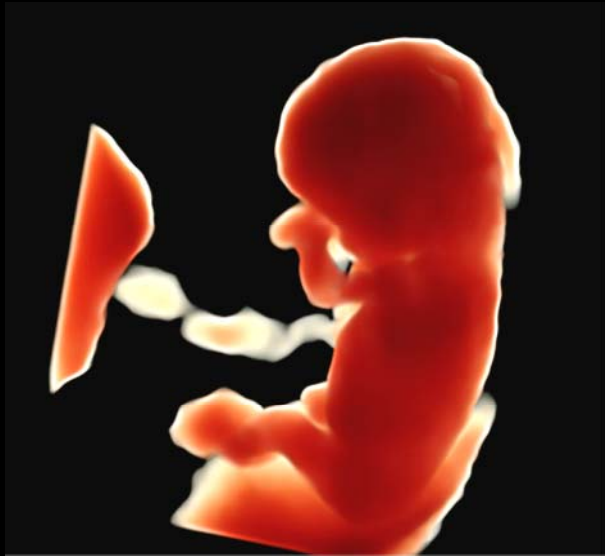**12  
SEMANAS**

# 12 SEMANAS

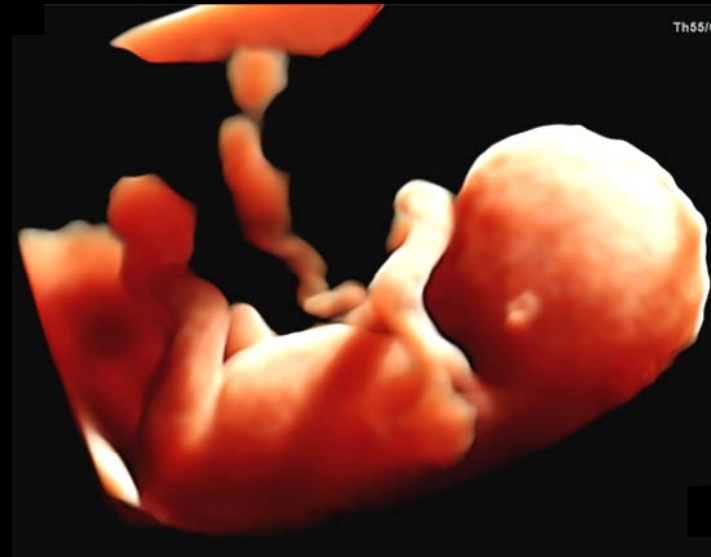



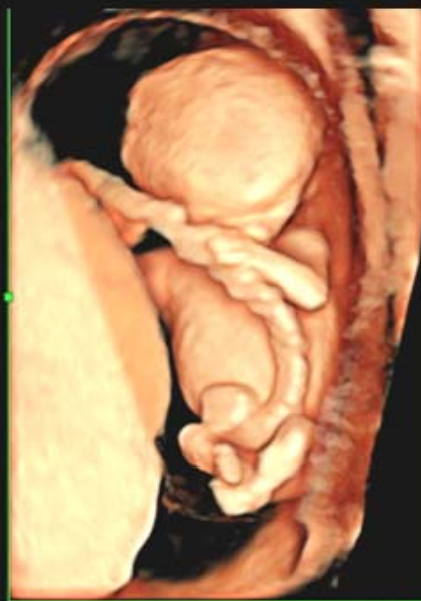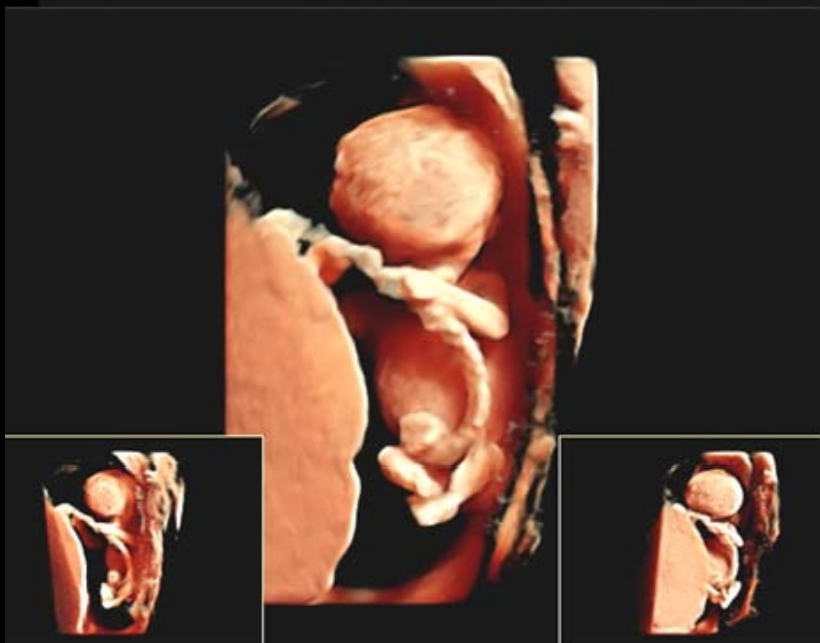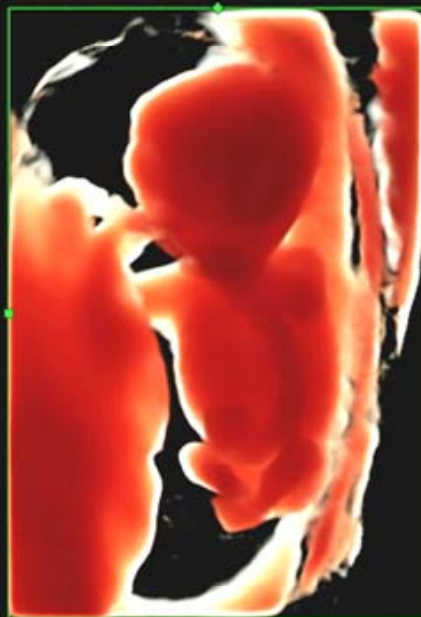
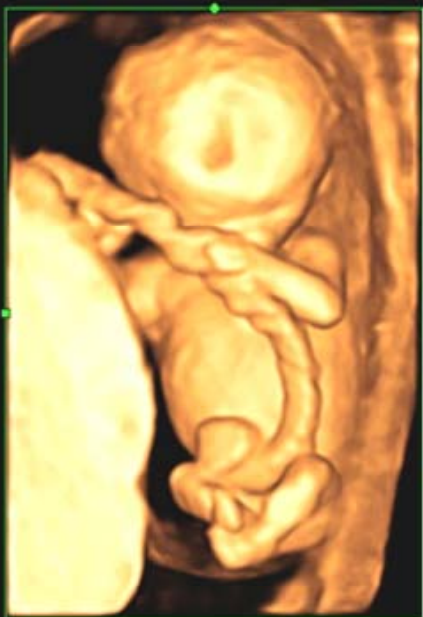13  
SEMANAS



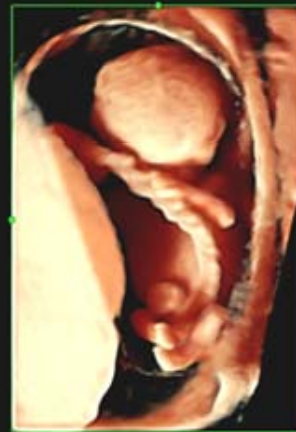
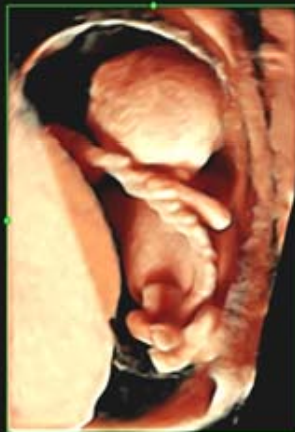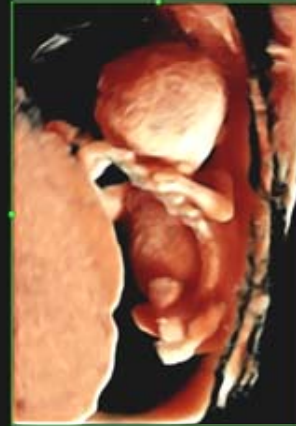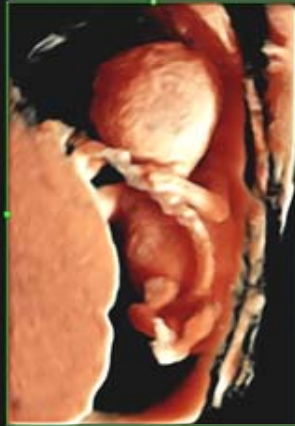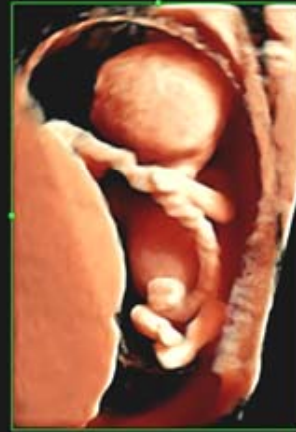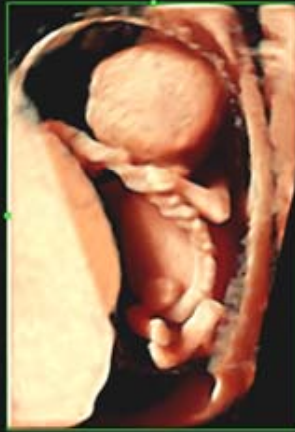**13**  
**SCHW. W**



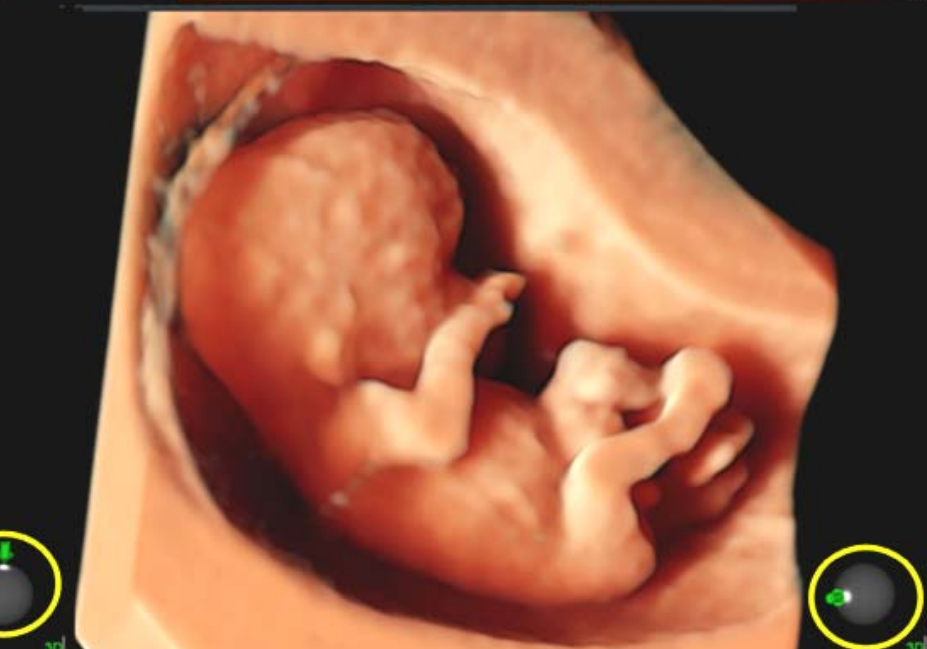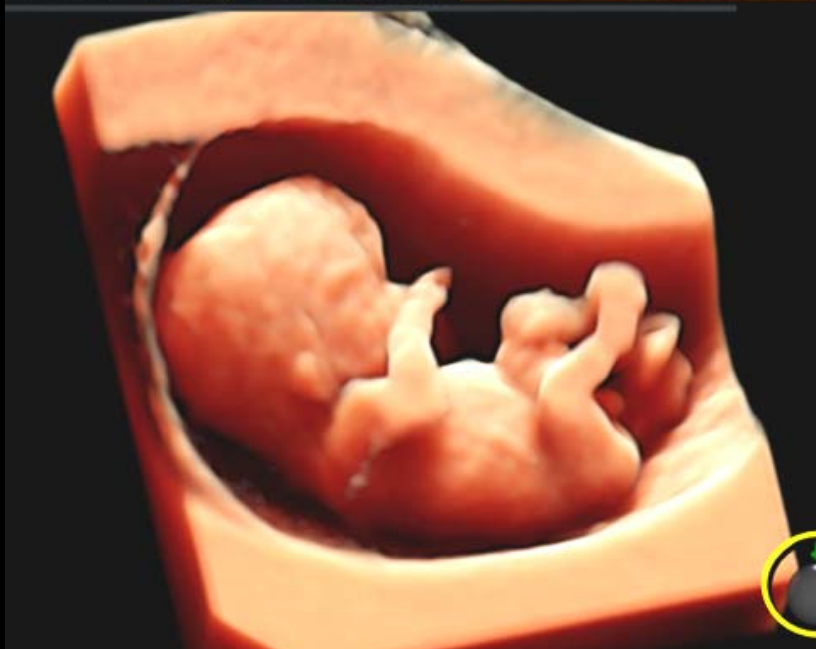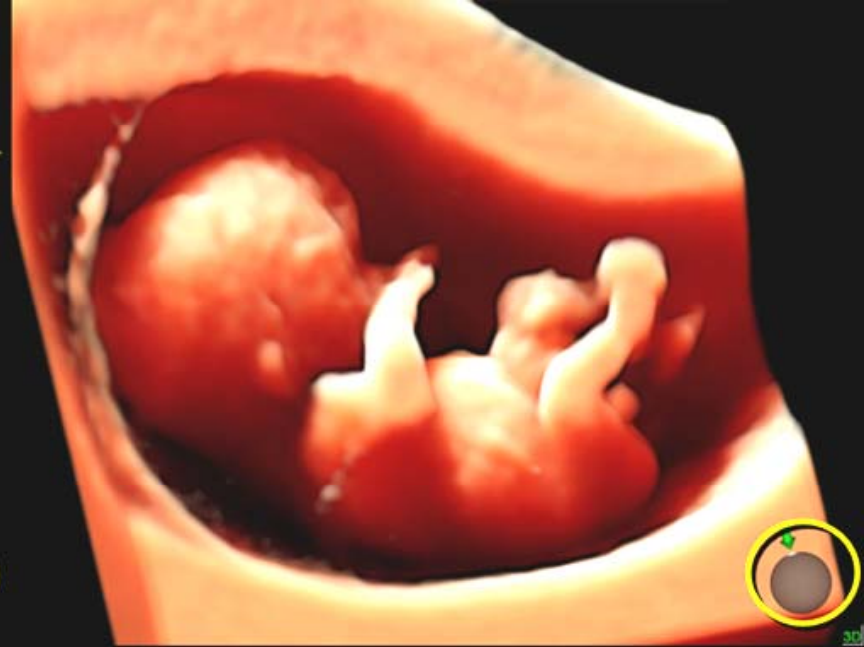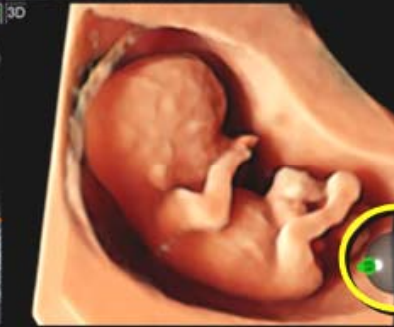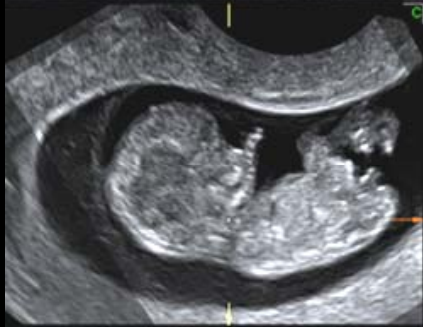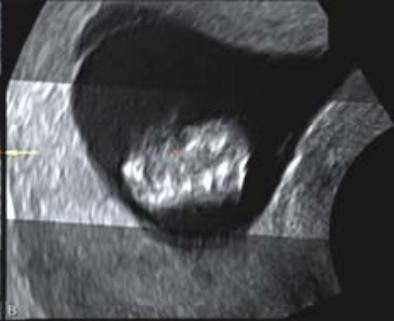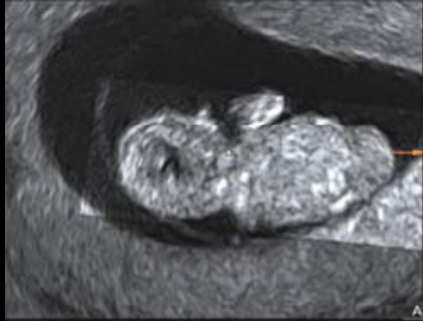# 14 SEMANAS

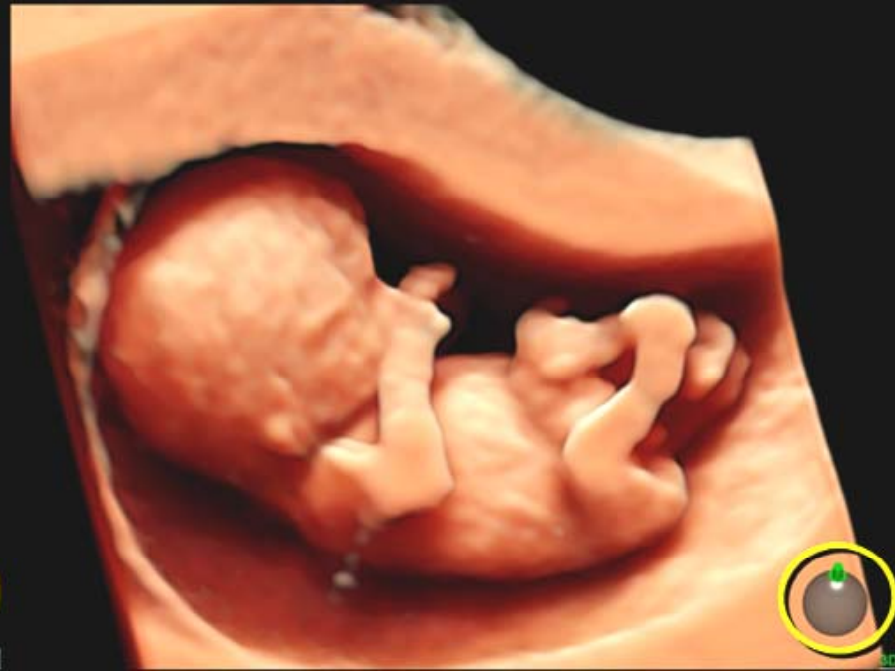
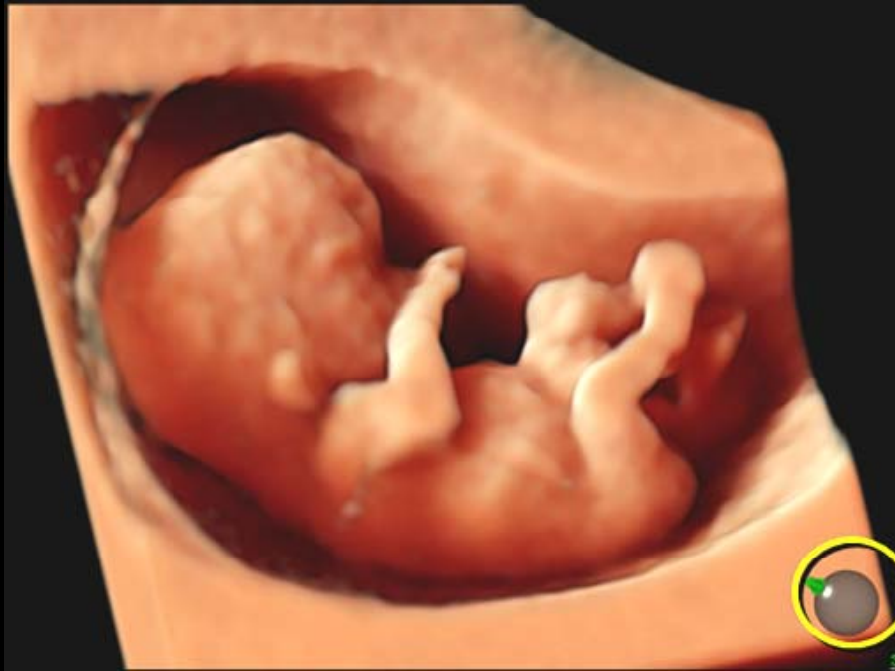
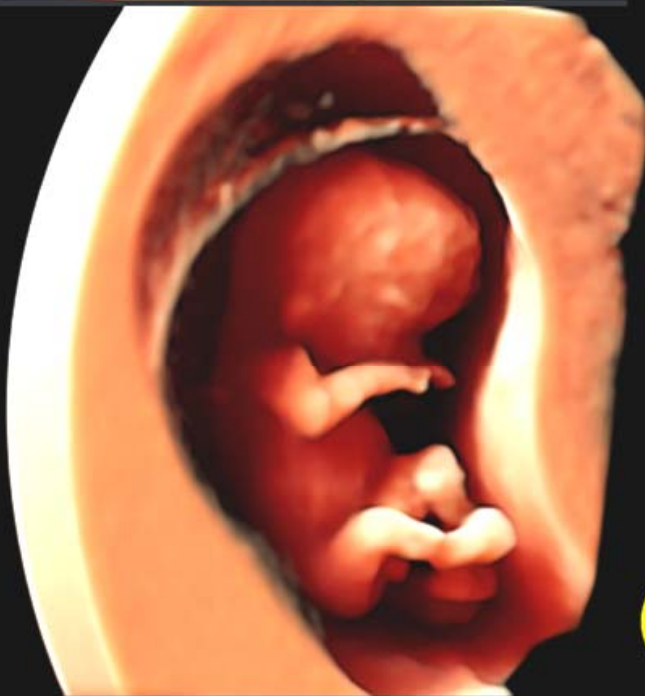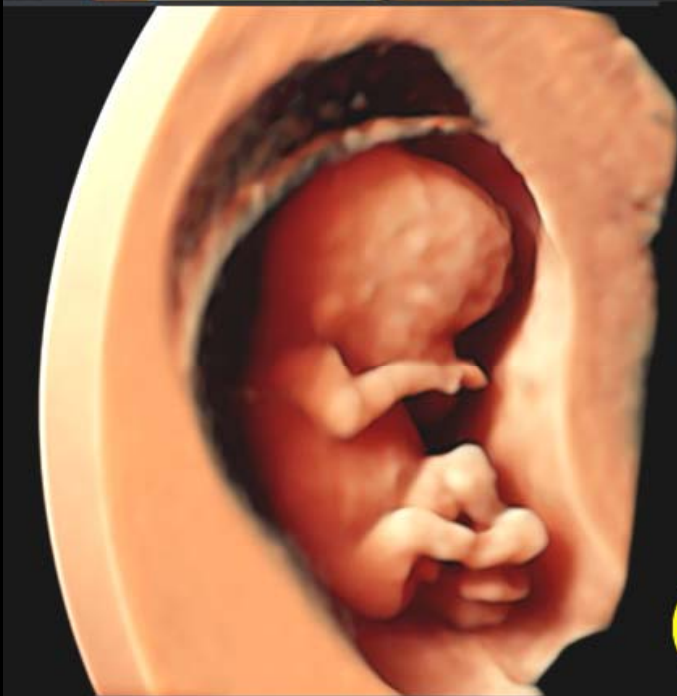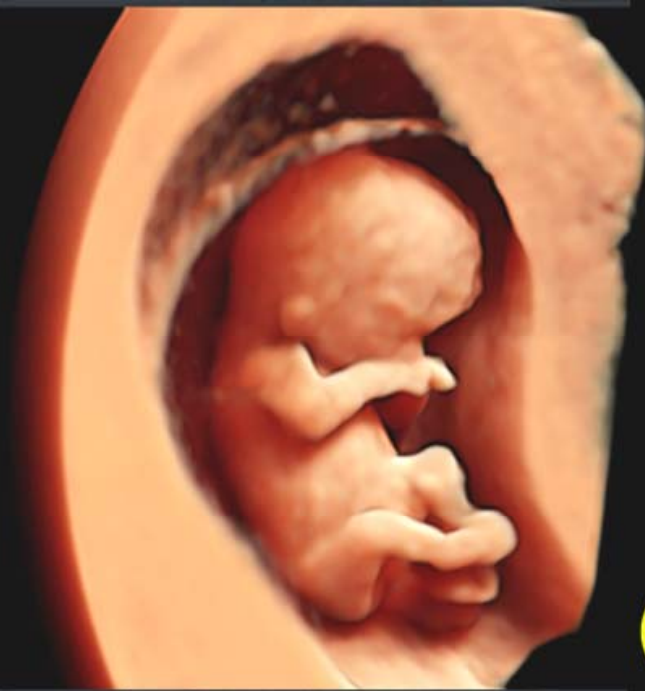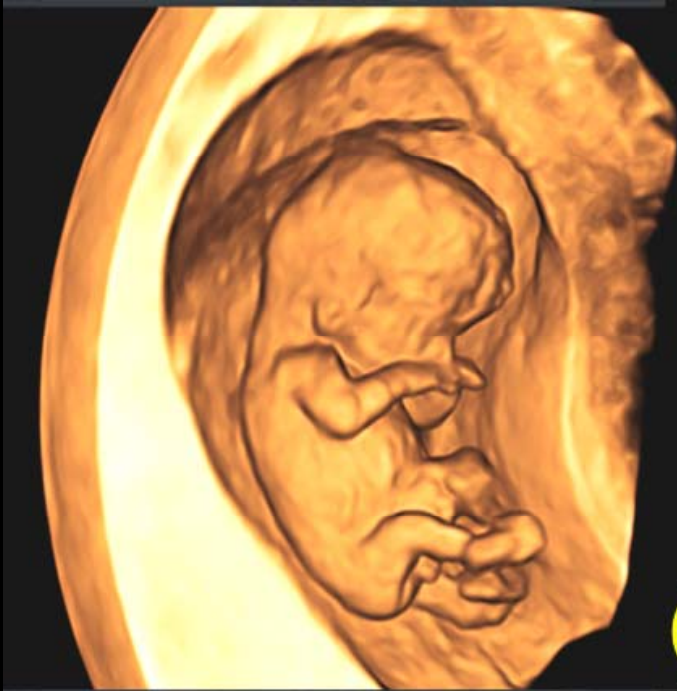14 SEMANAS

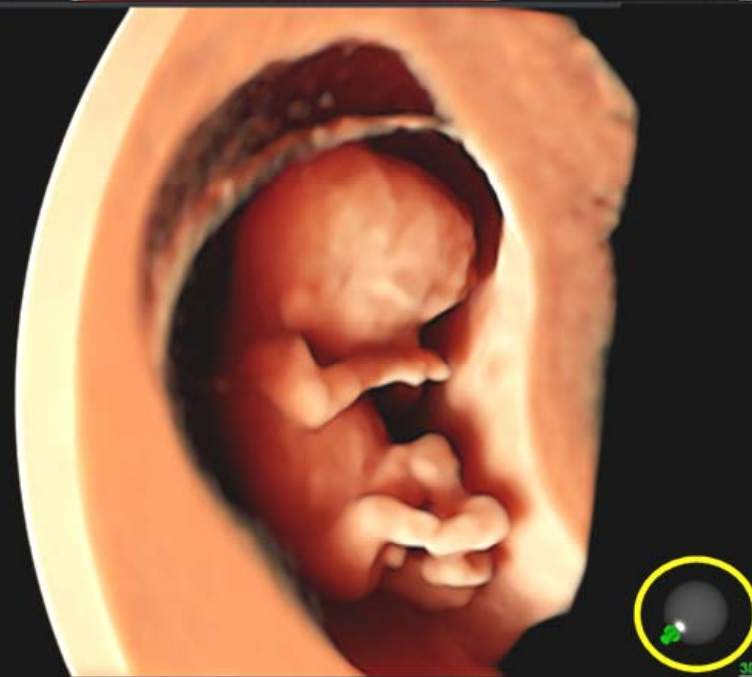
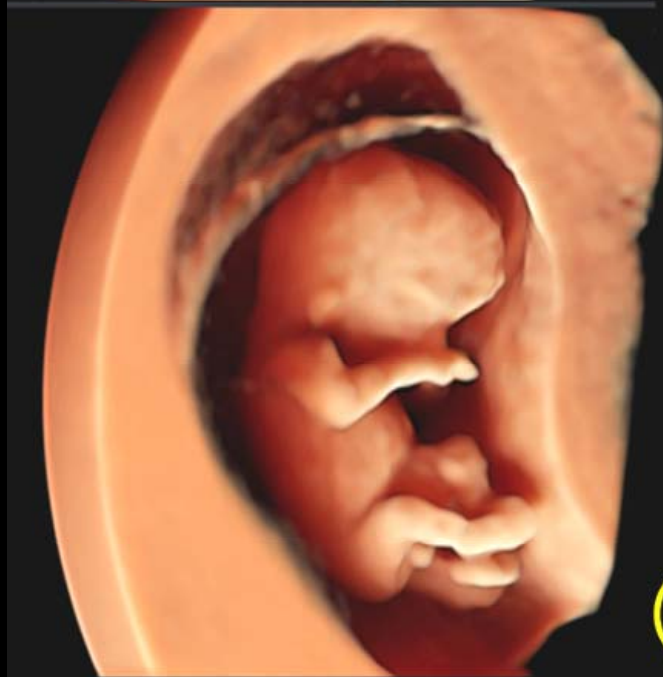
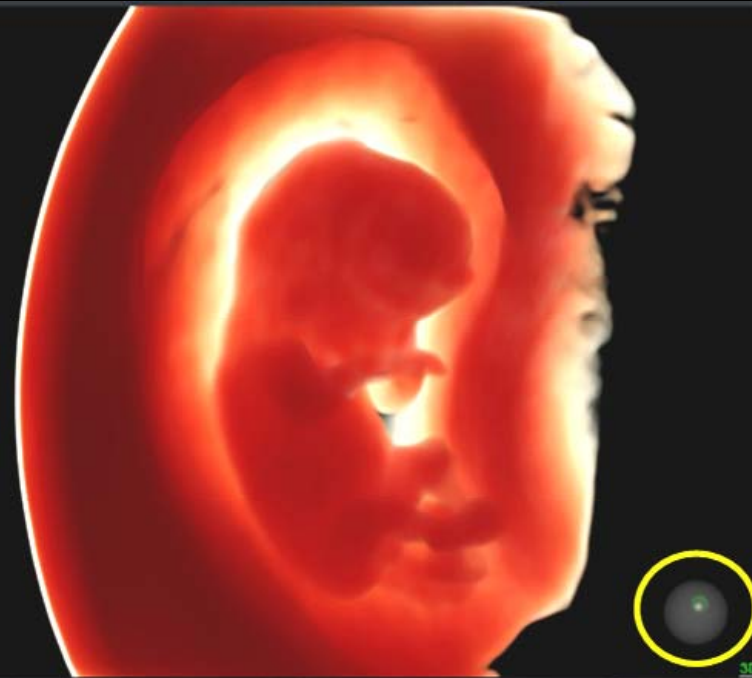
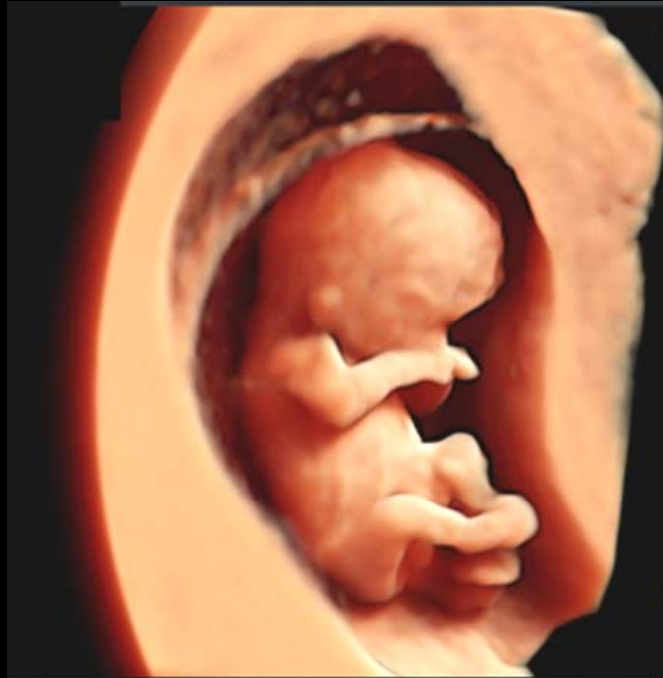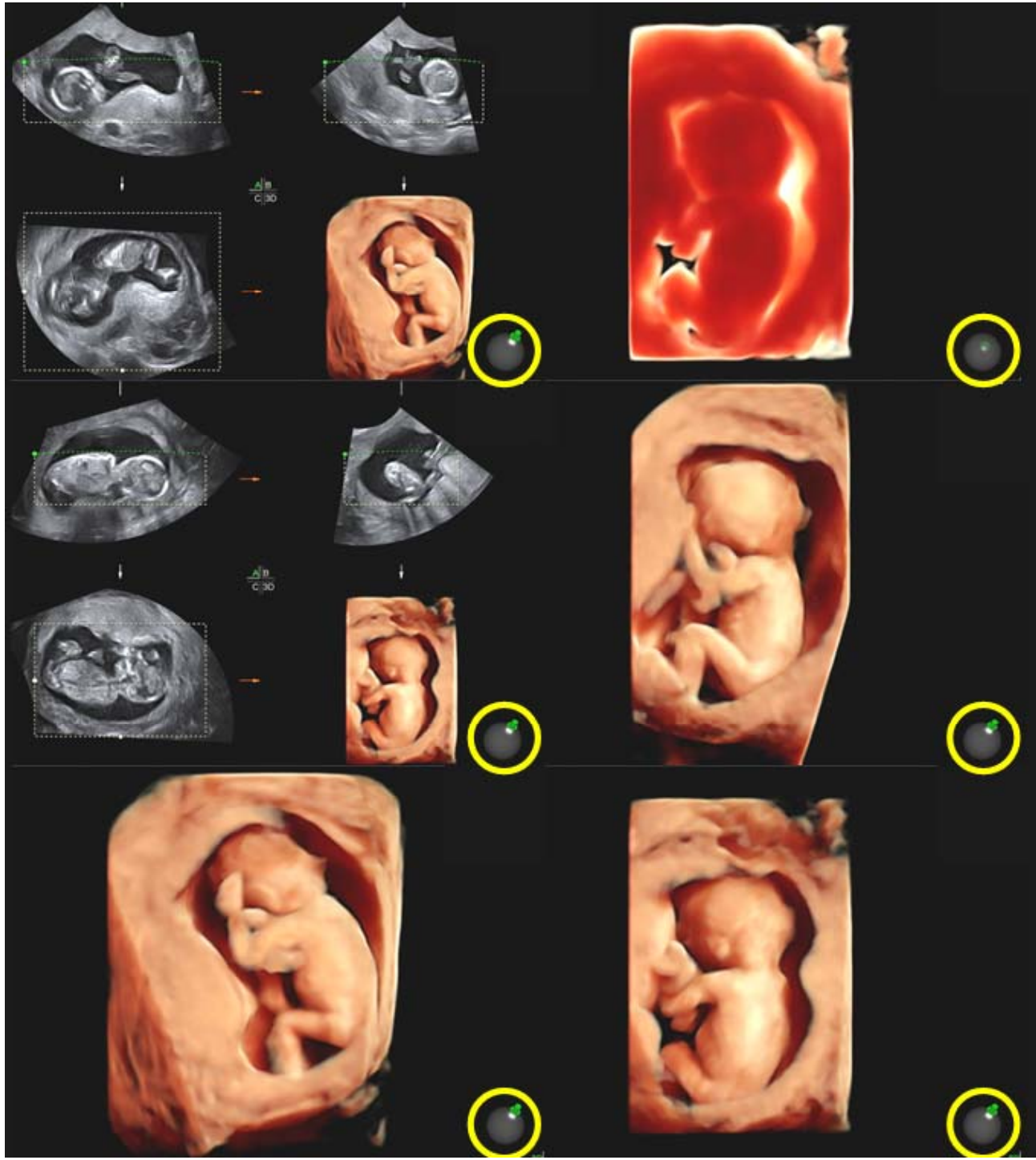







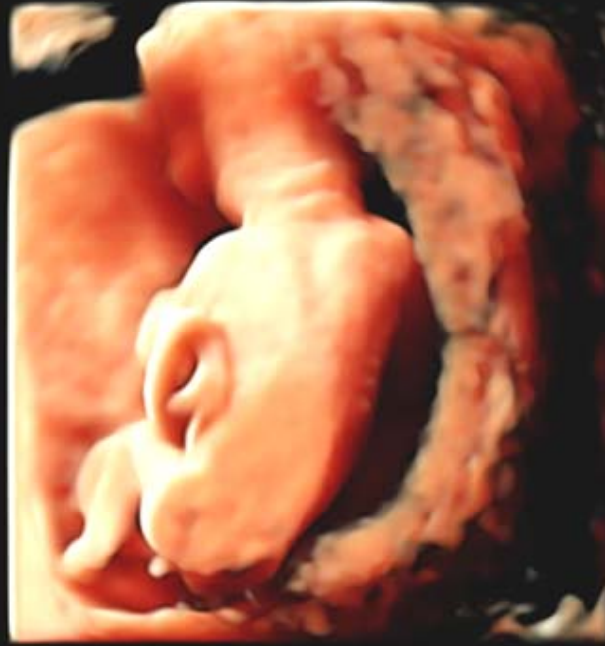
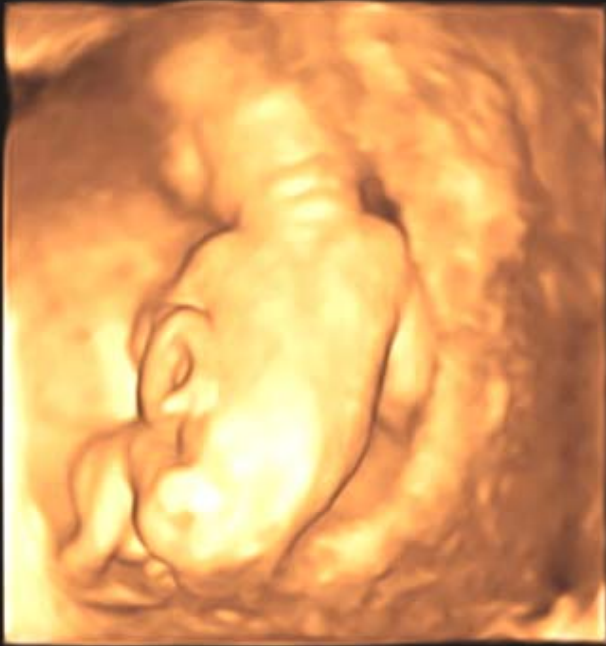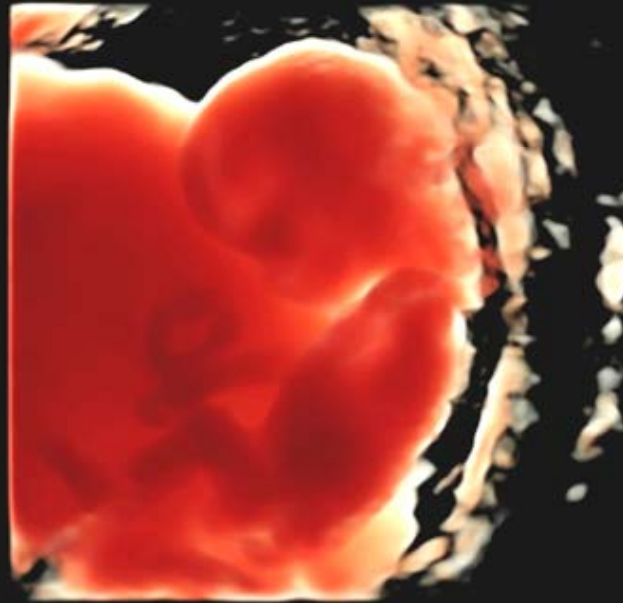
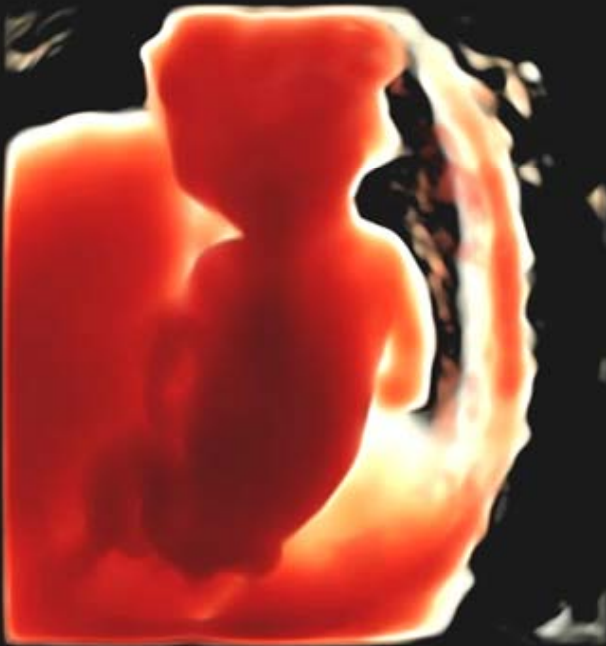




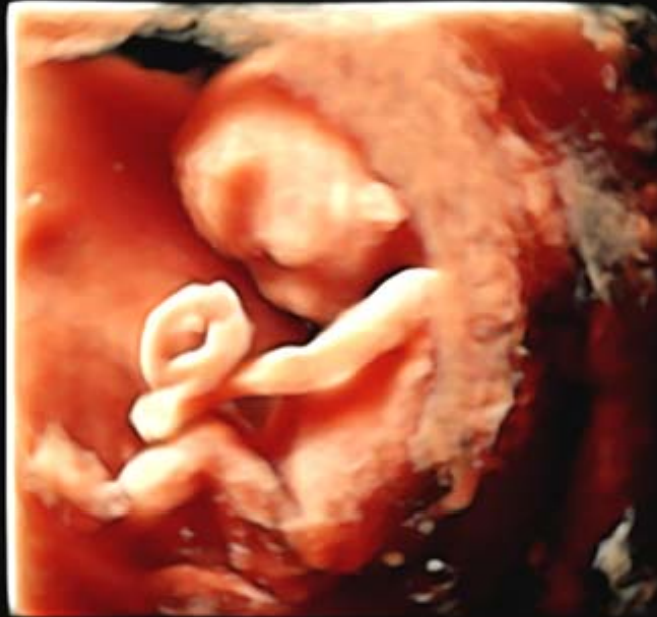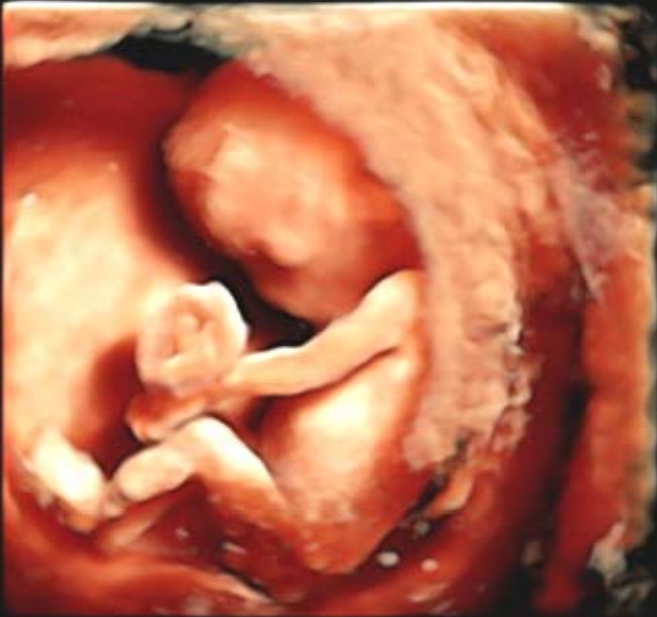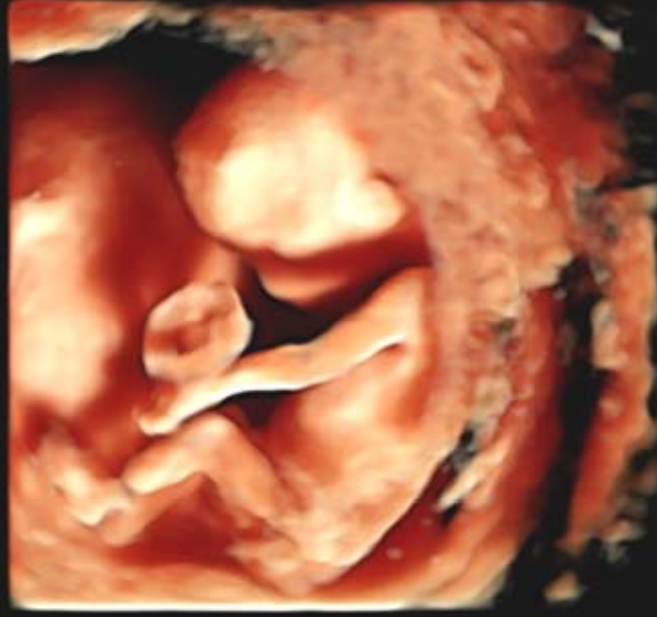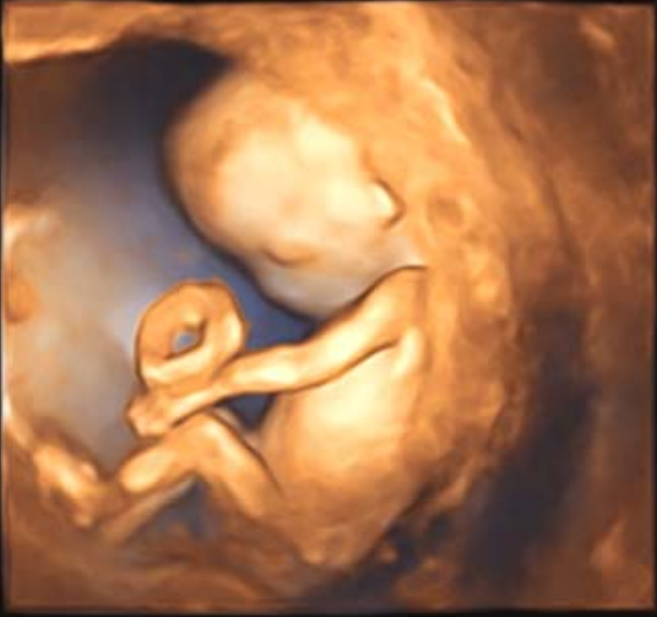**16  
SEMANAS**

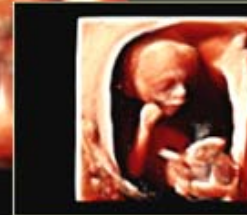
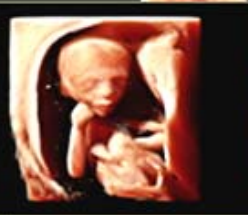
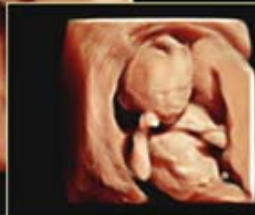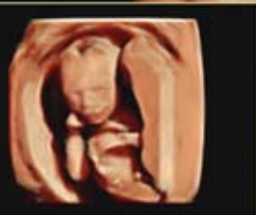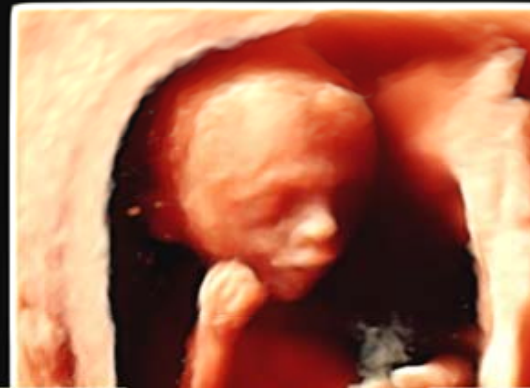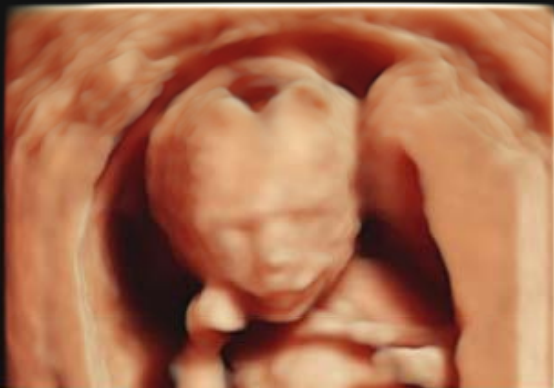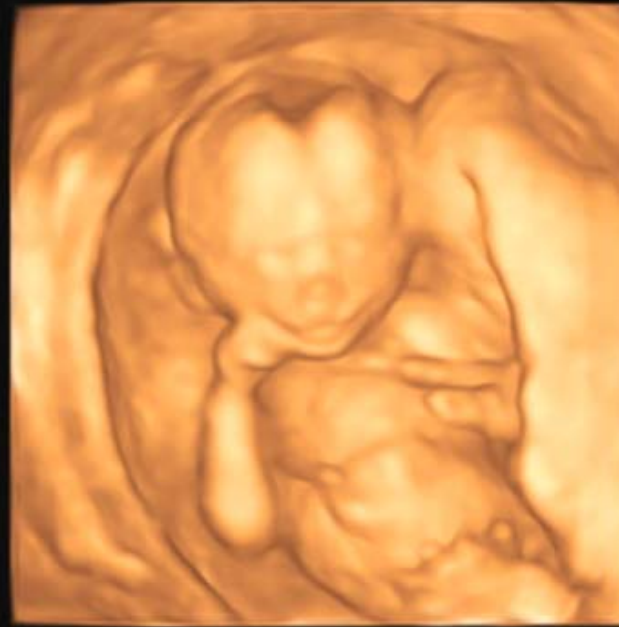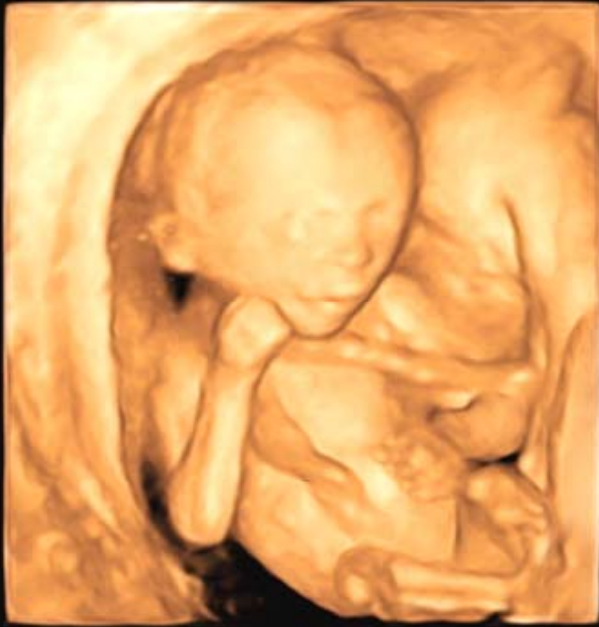17  
SEM

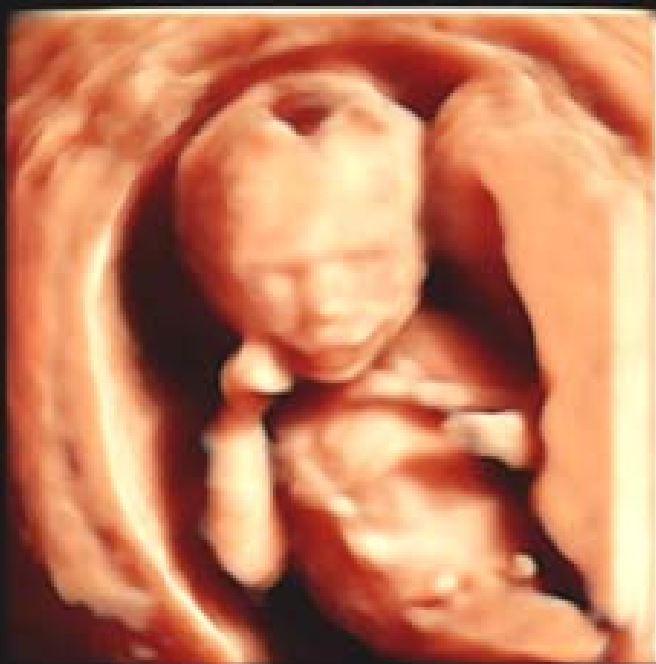
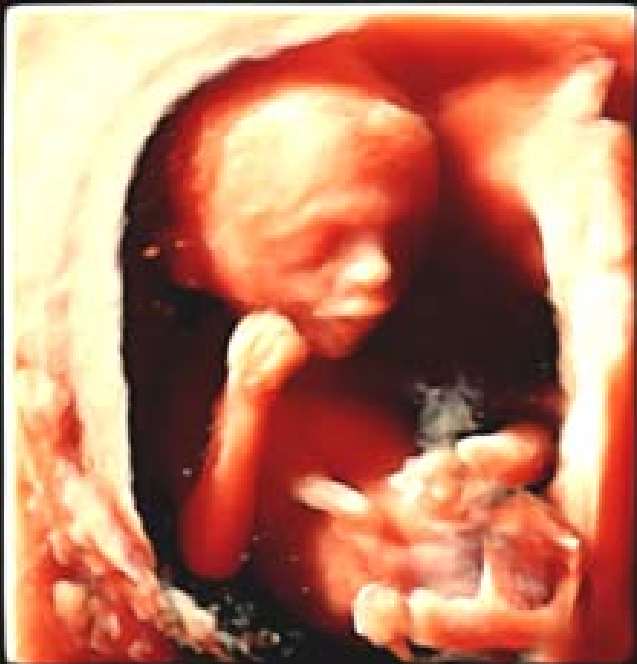
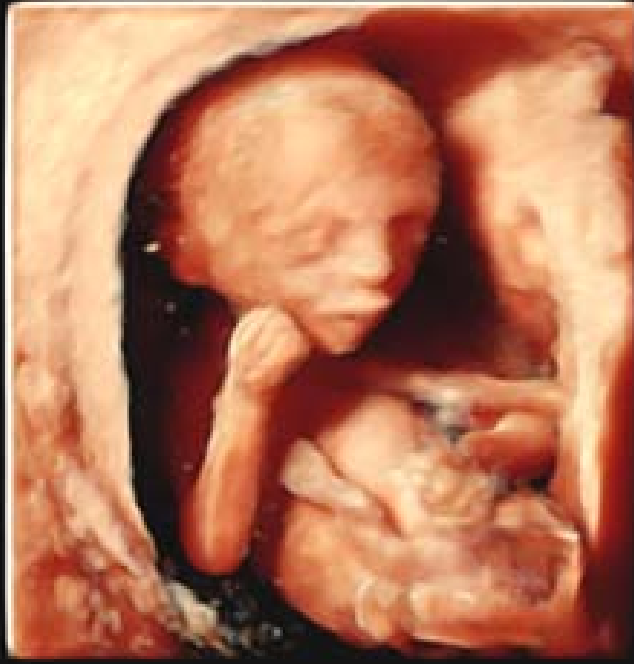
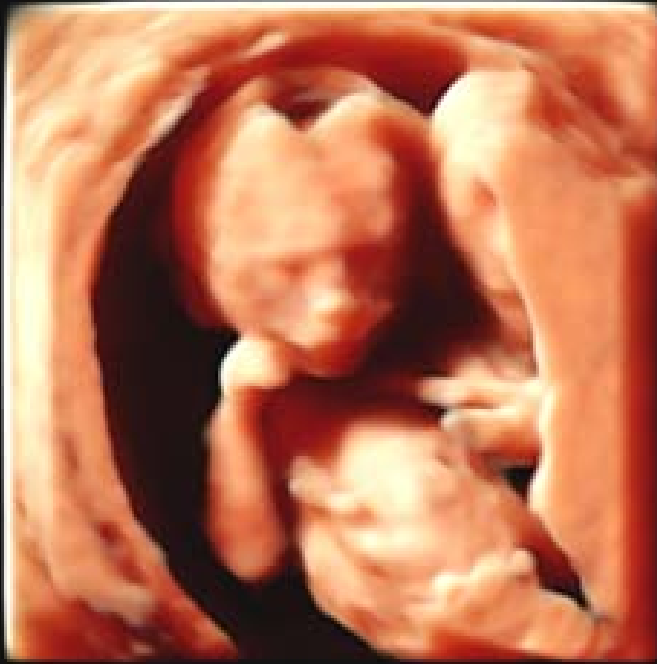
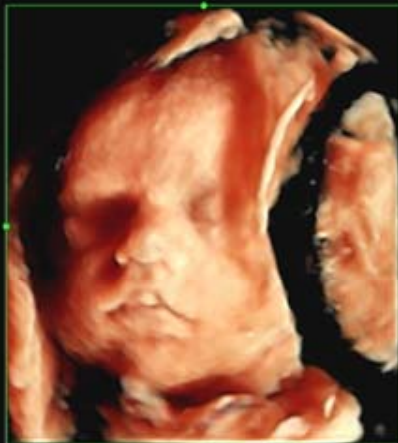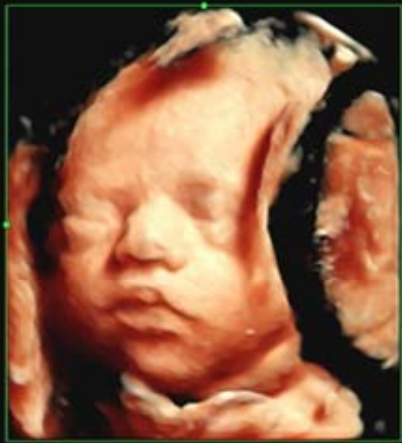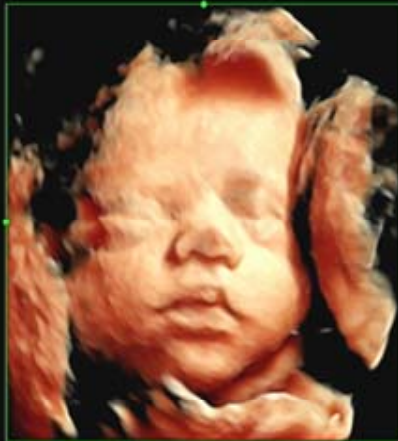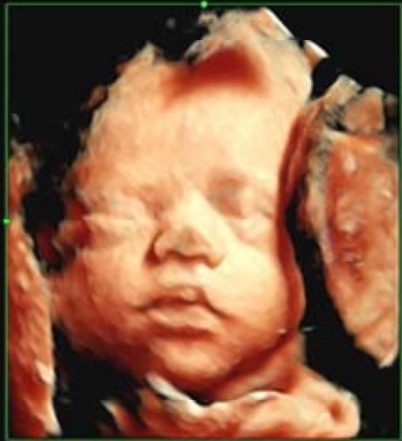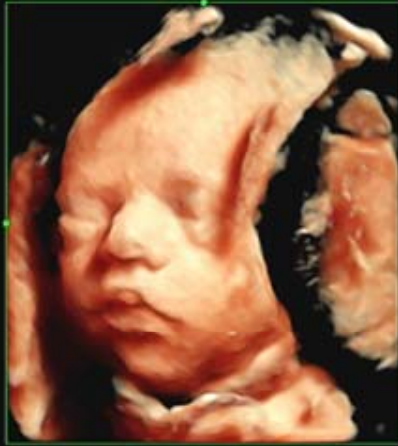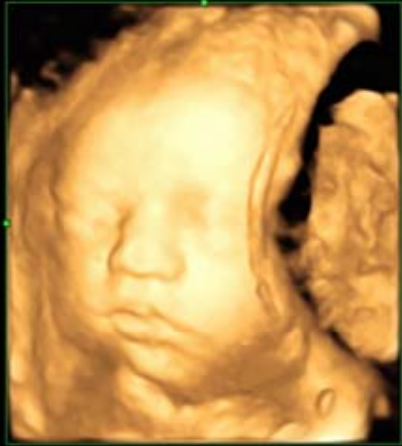**18  
SEMANAS**

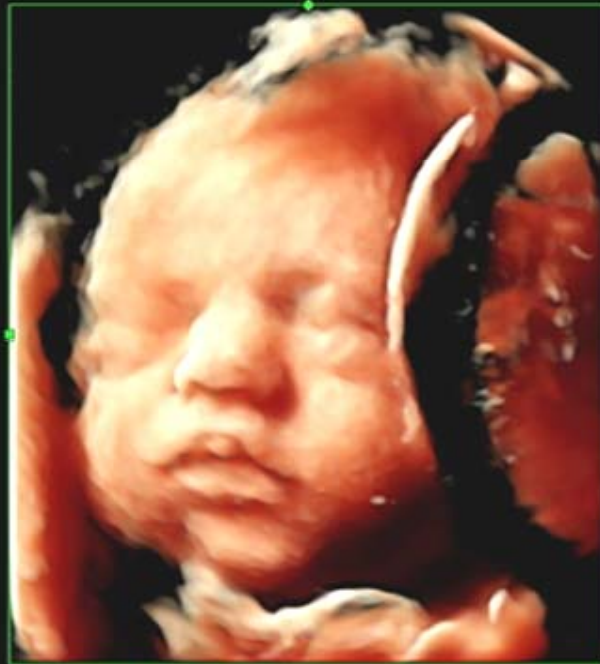
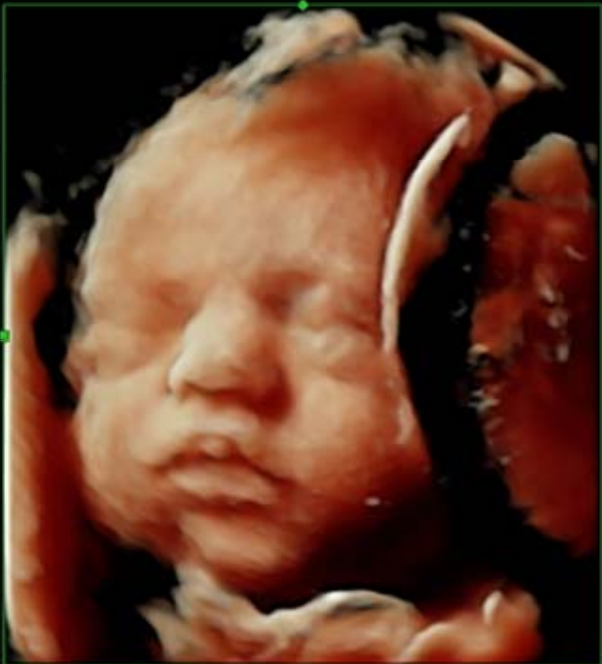
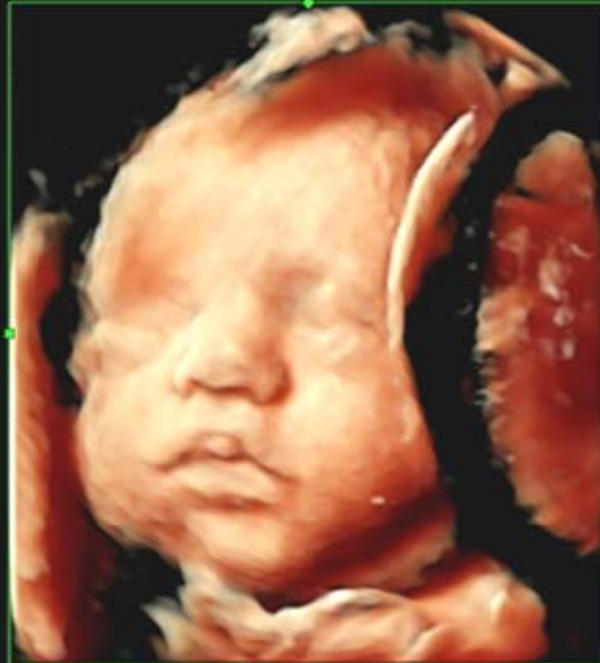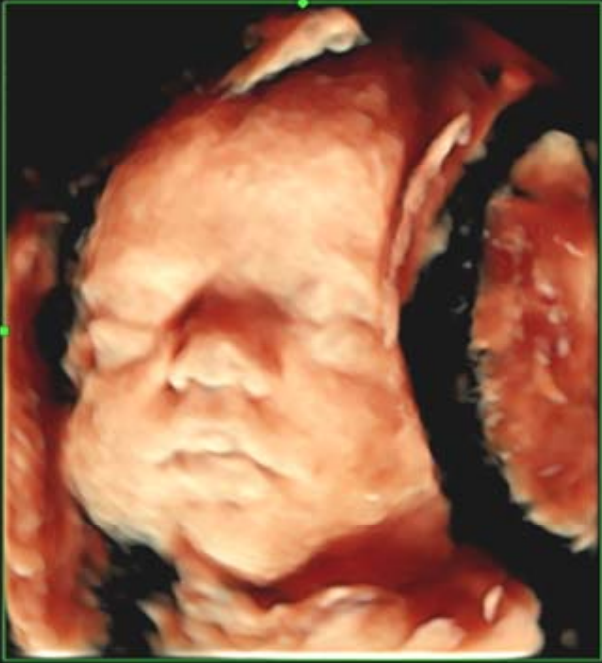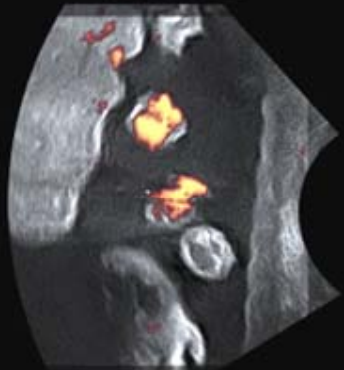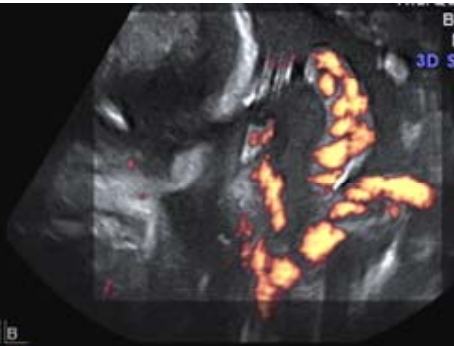
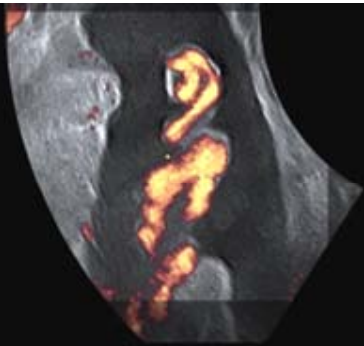




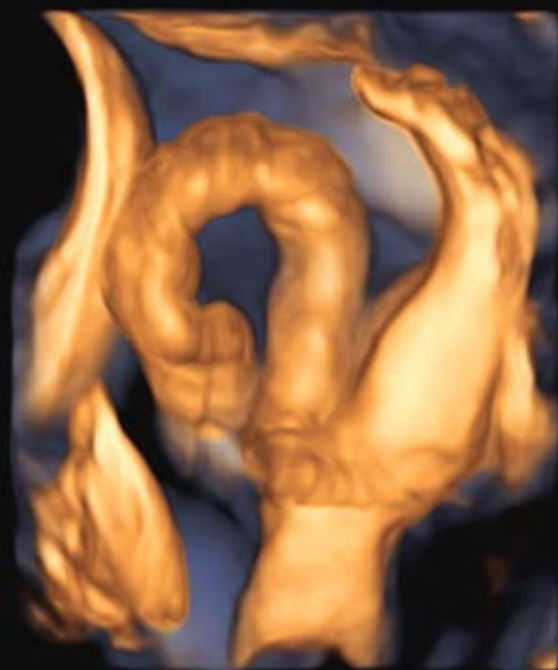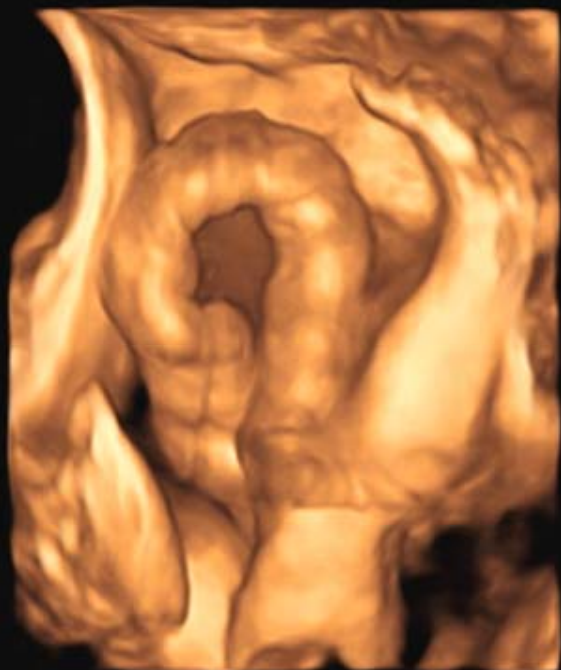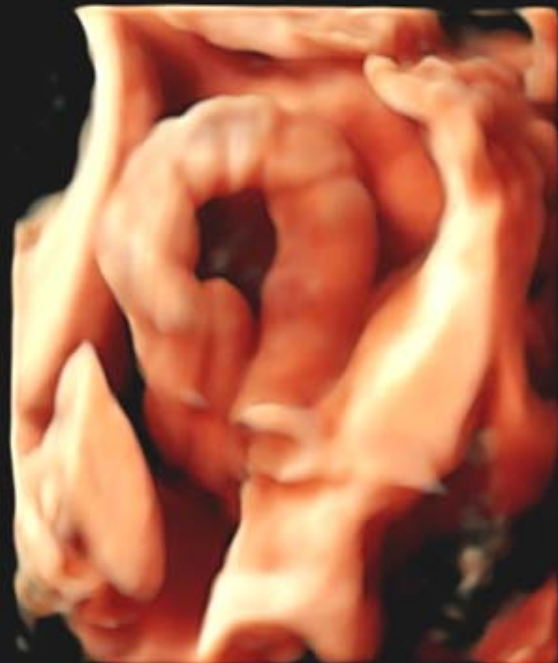
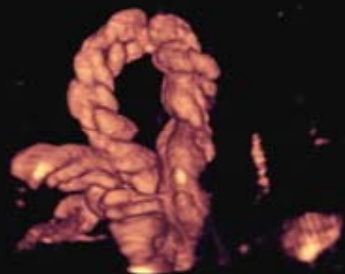


**34  
SEMANAS**



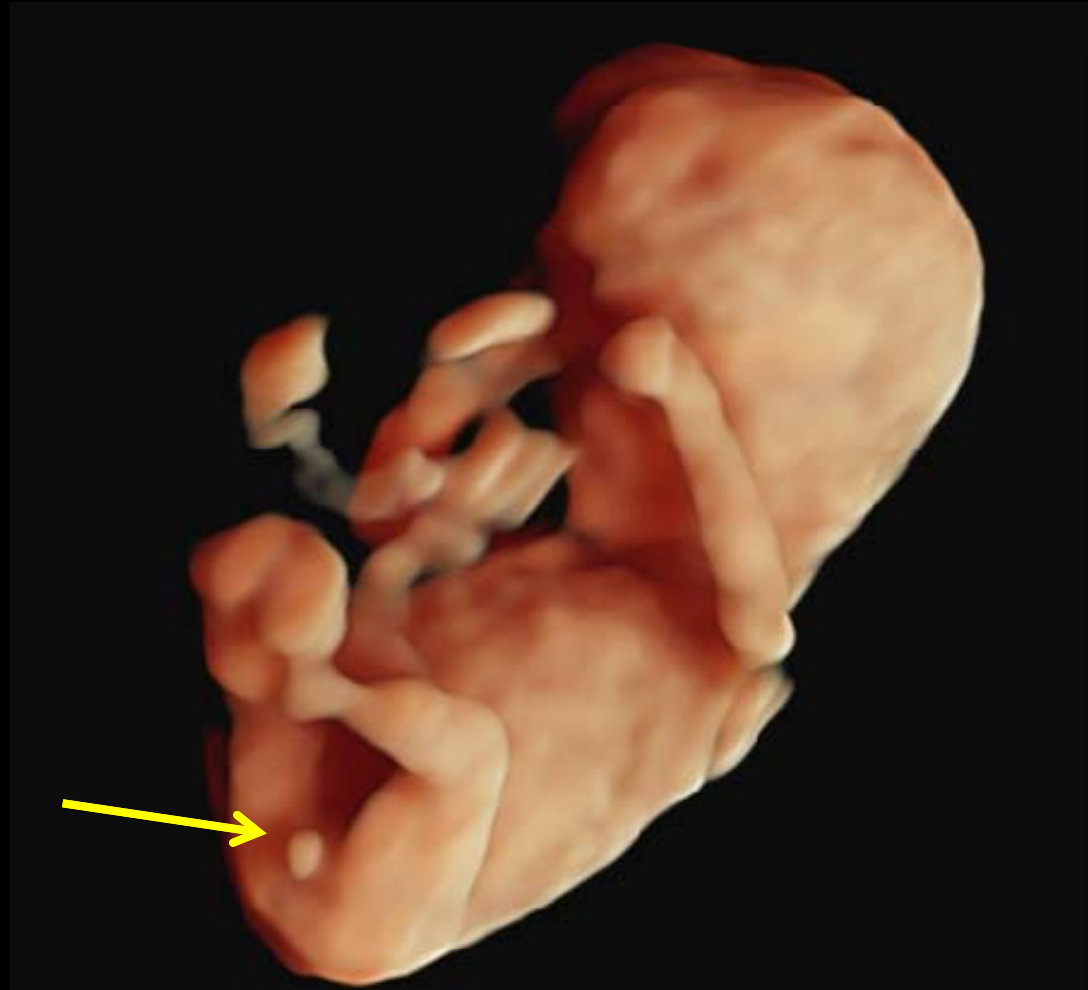


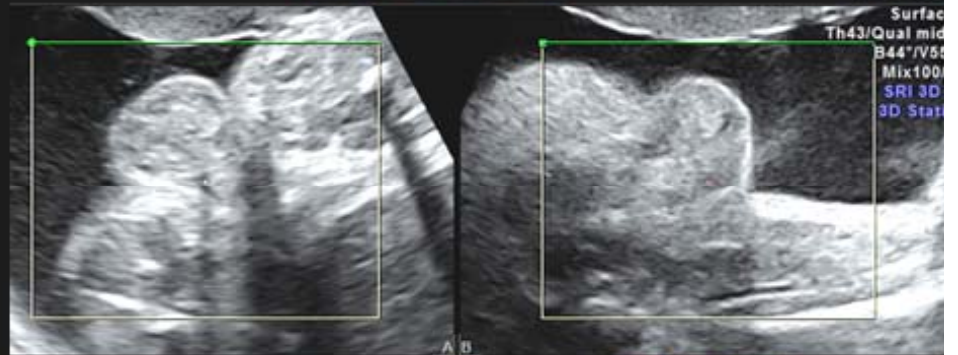
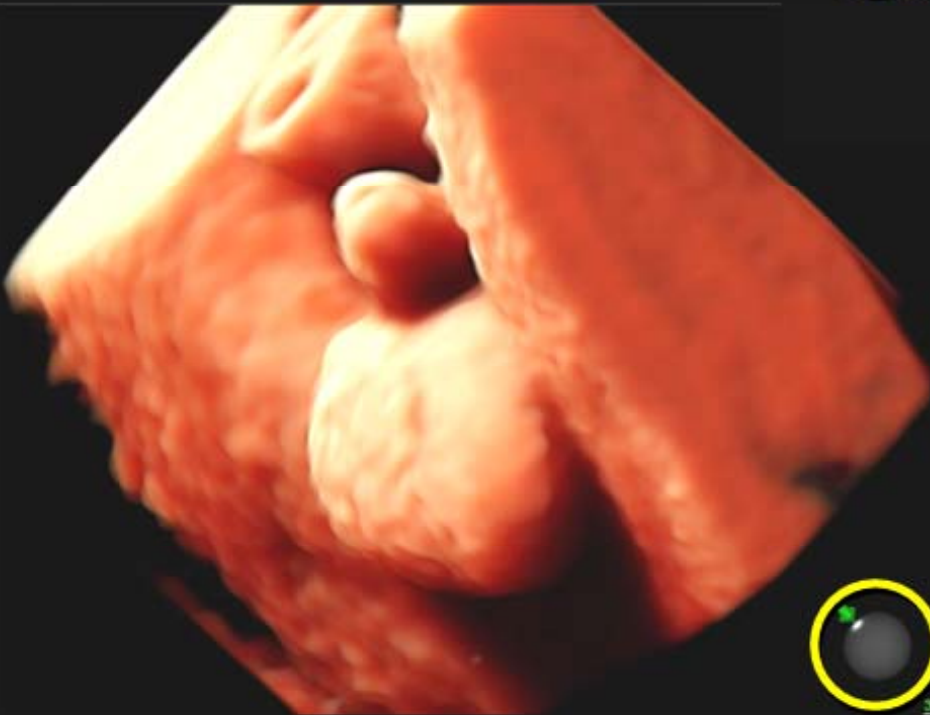
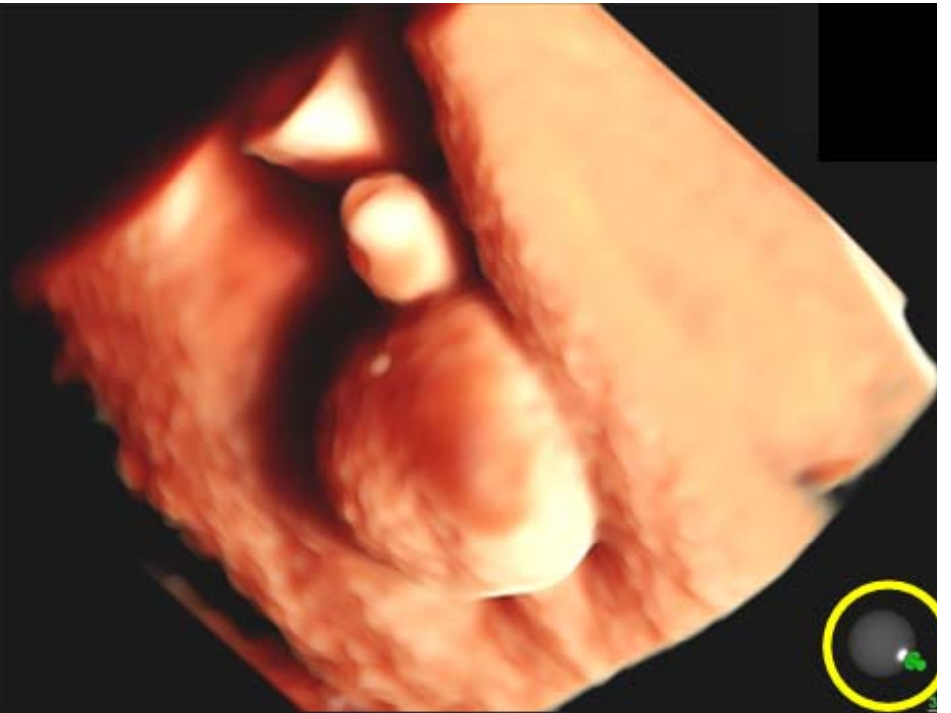
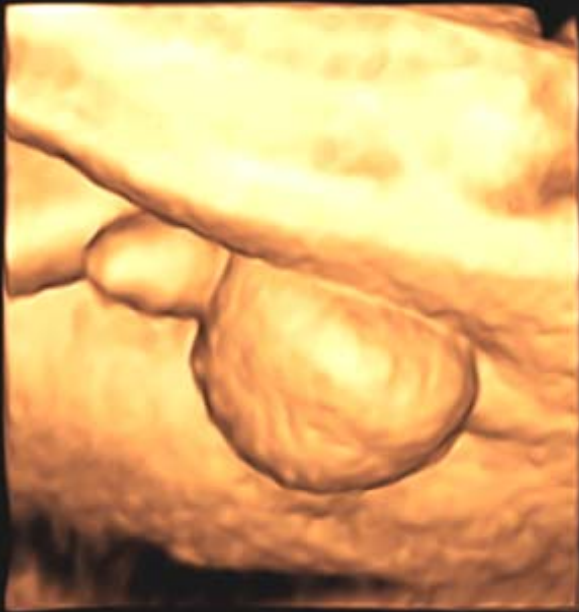
A/B  
C/SD



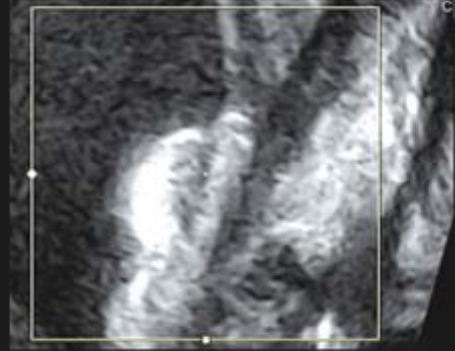
# TUBERCULUM GENITALIS

**13  
SEMANAS**

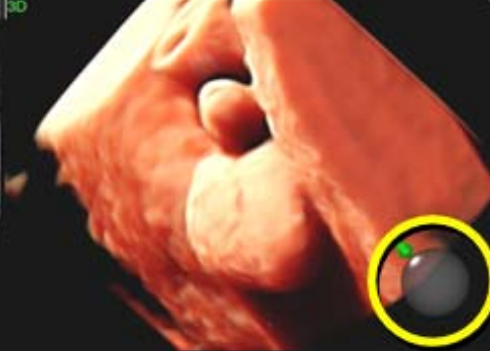


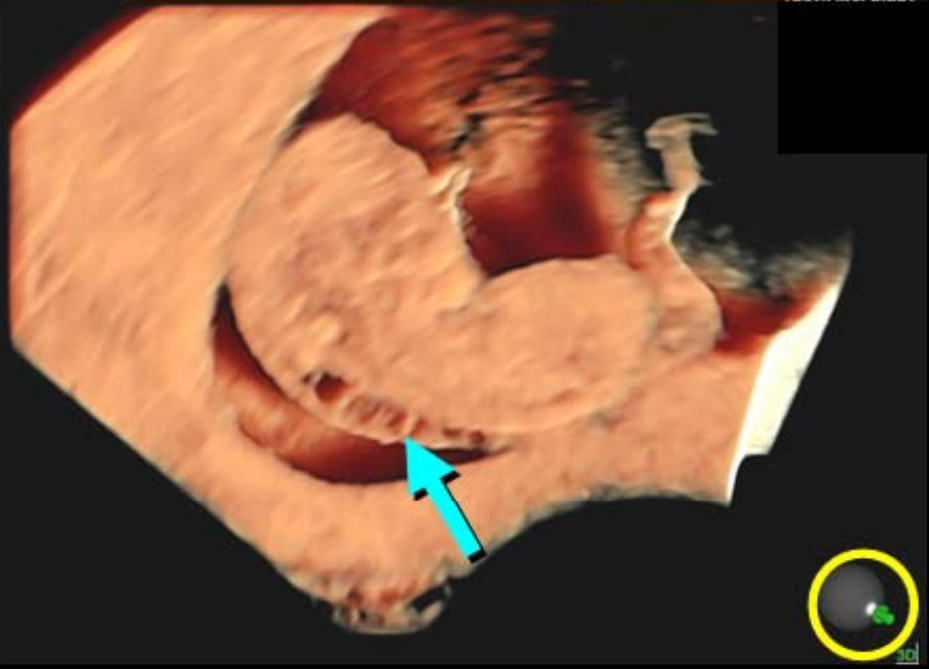
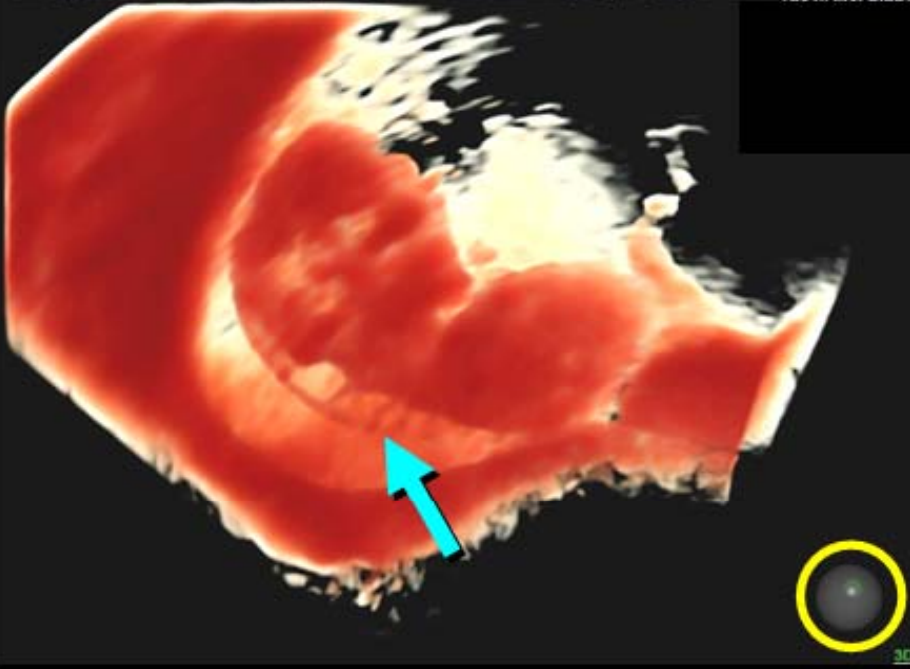
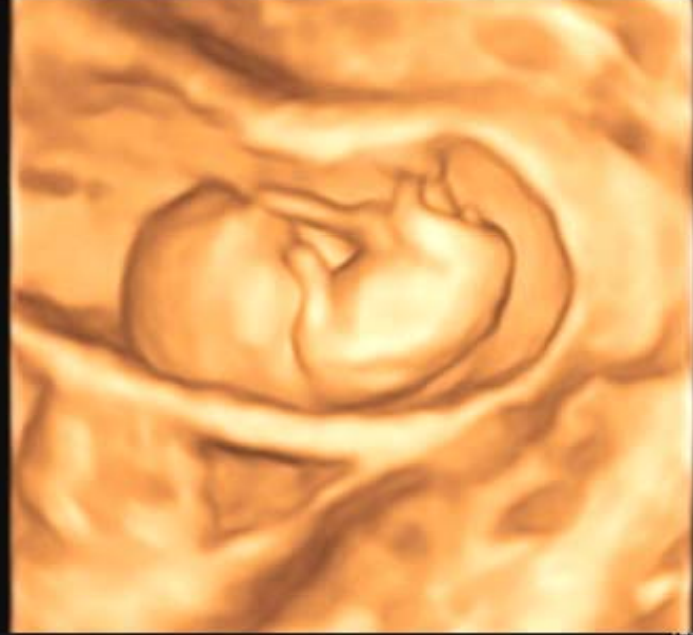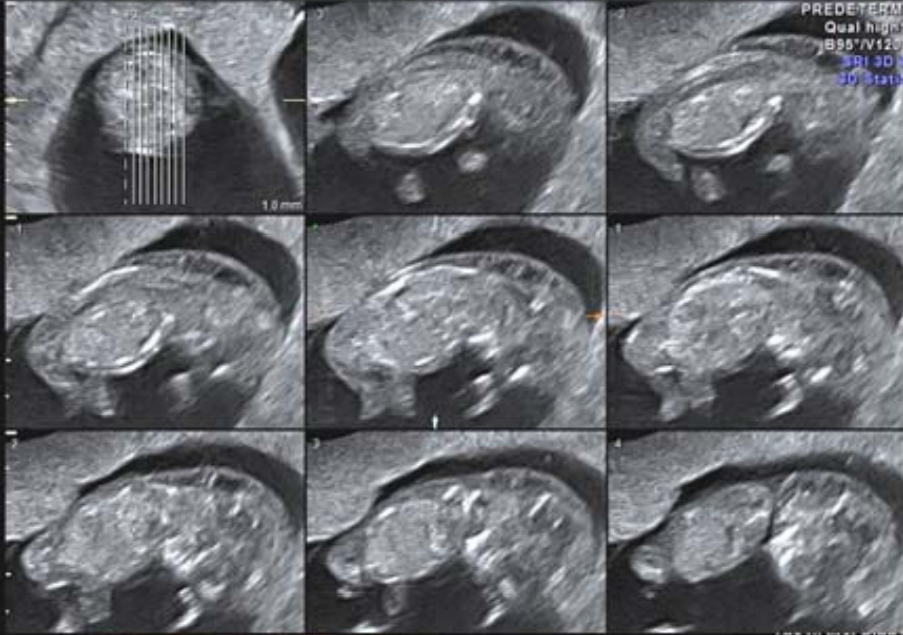


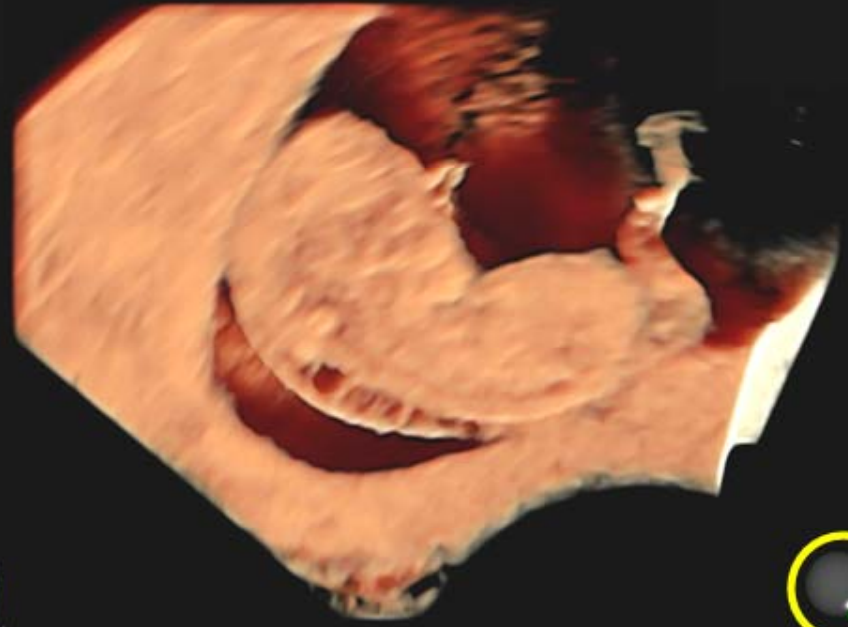
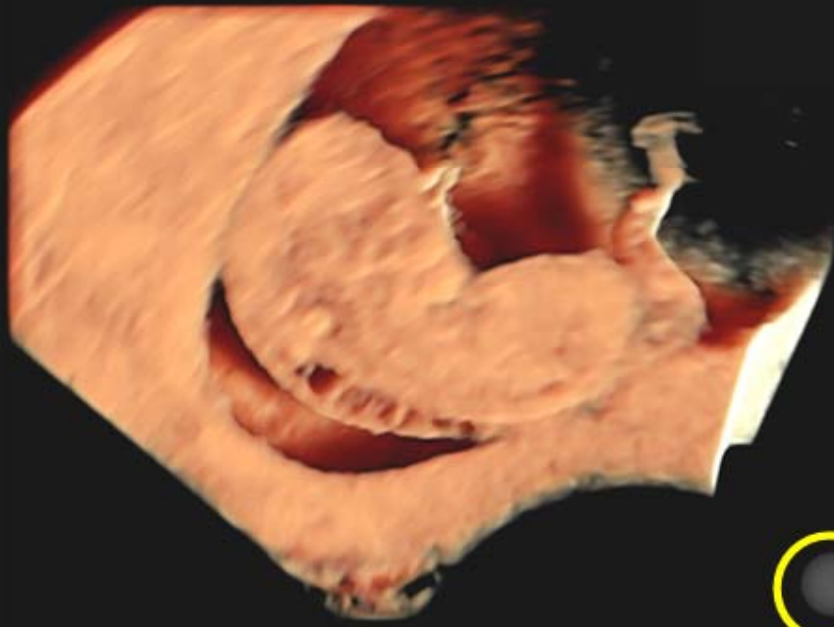
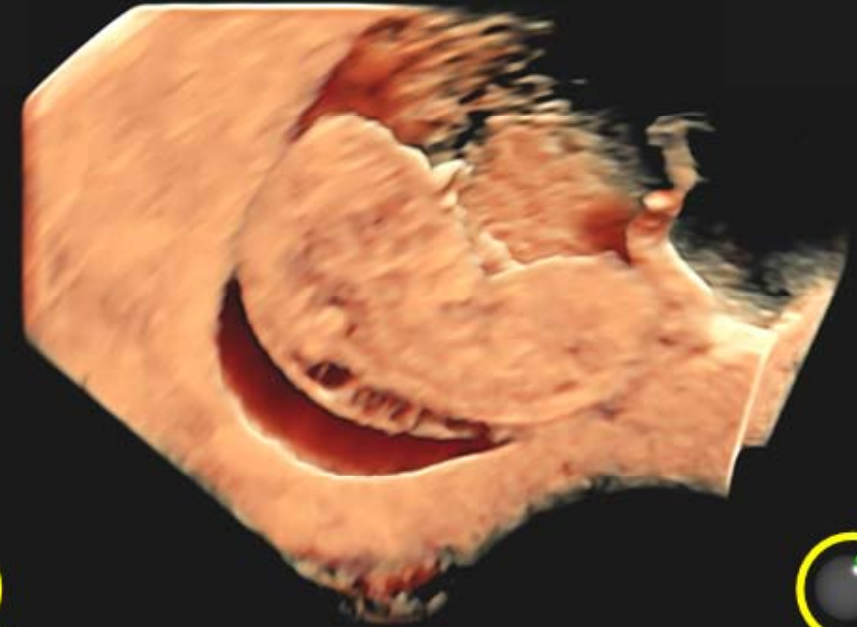
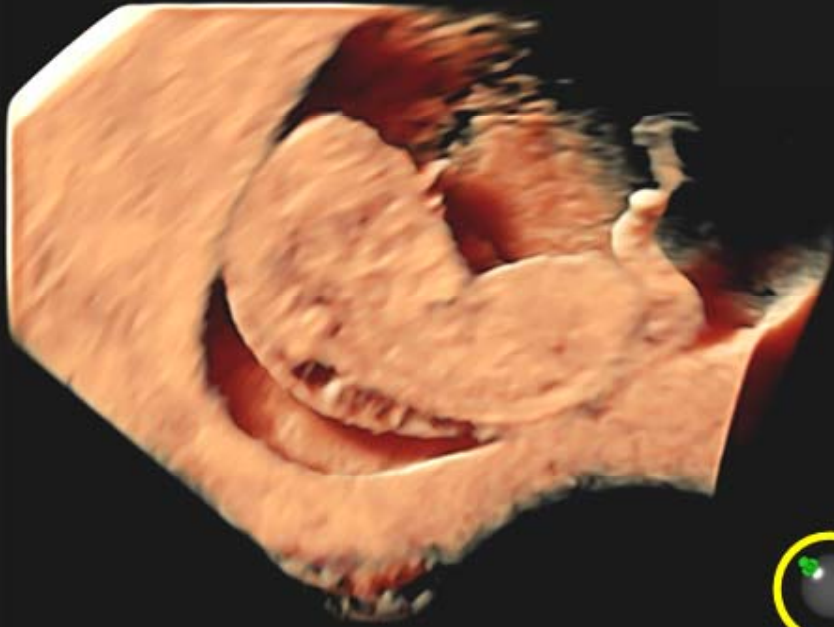Surfac  
Th43/Qual mic  
B44\*/V55  
Mix100  
SRI 3D  
3D Stat



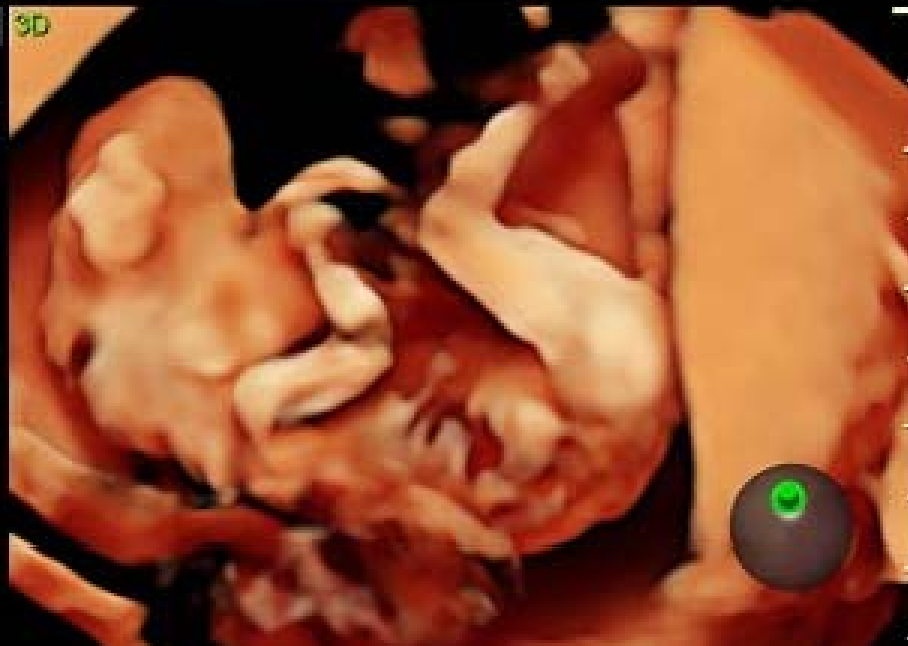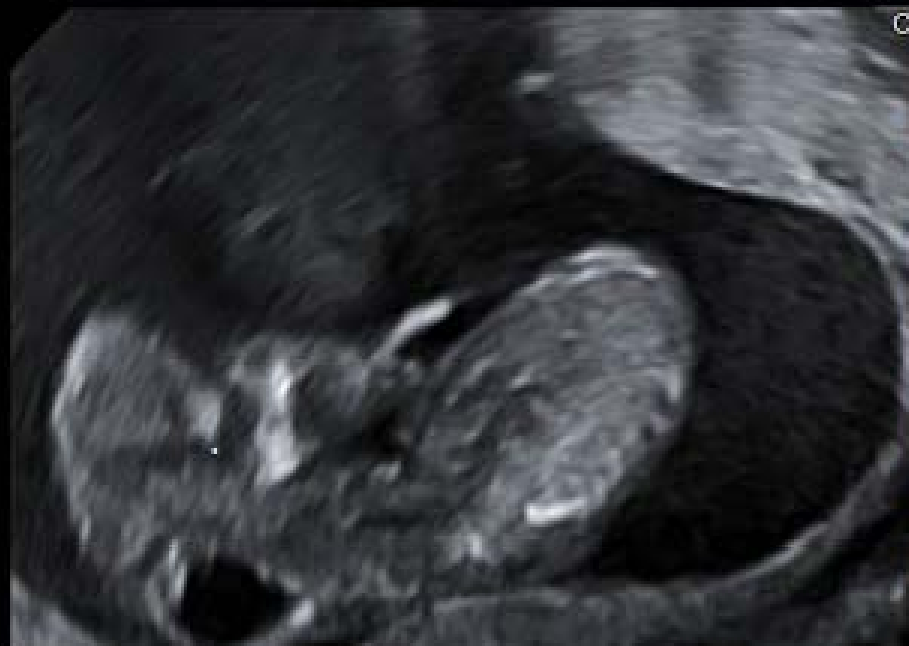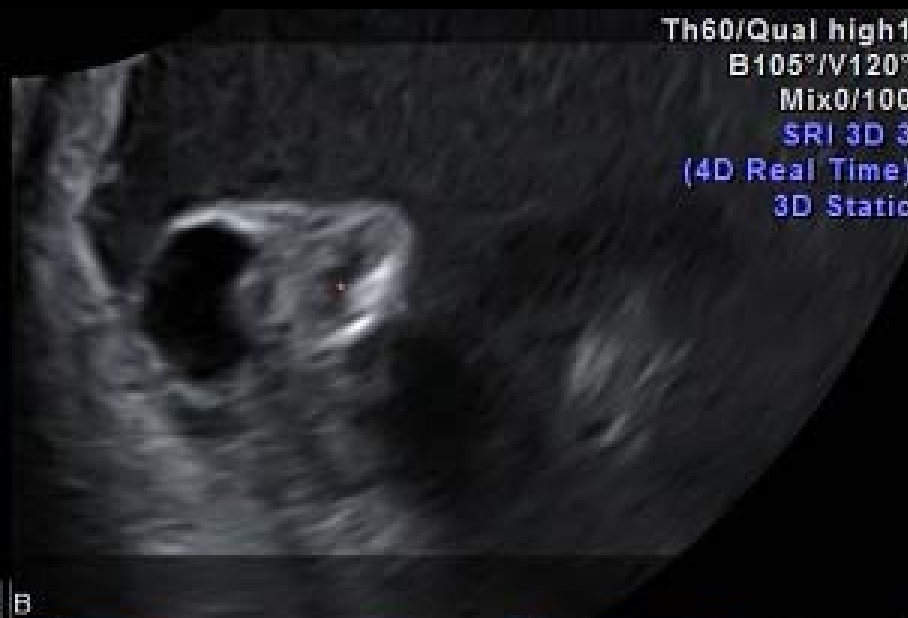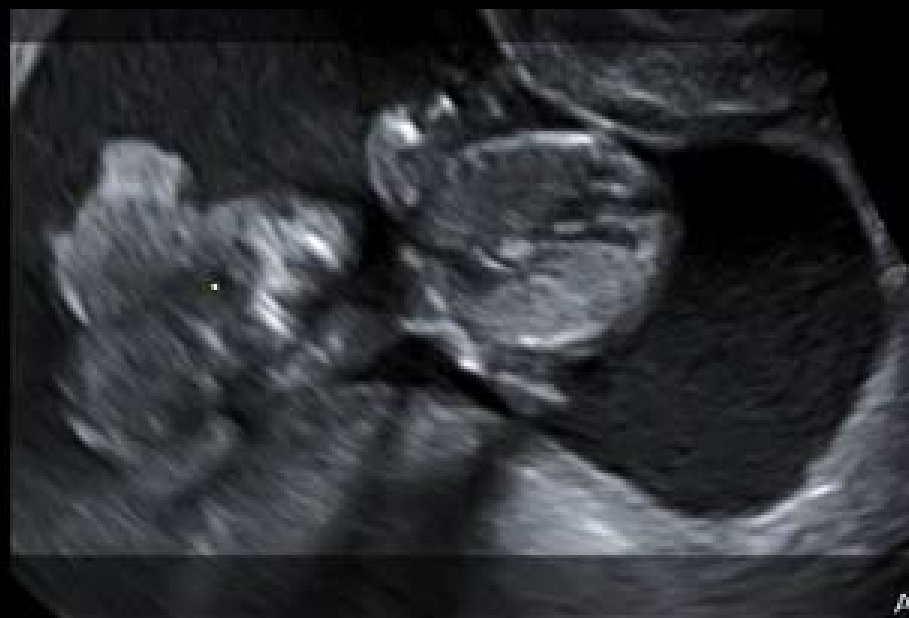A B  
C



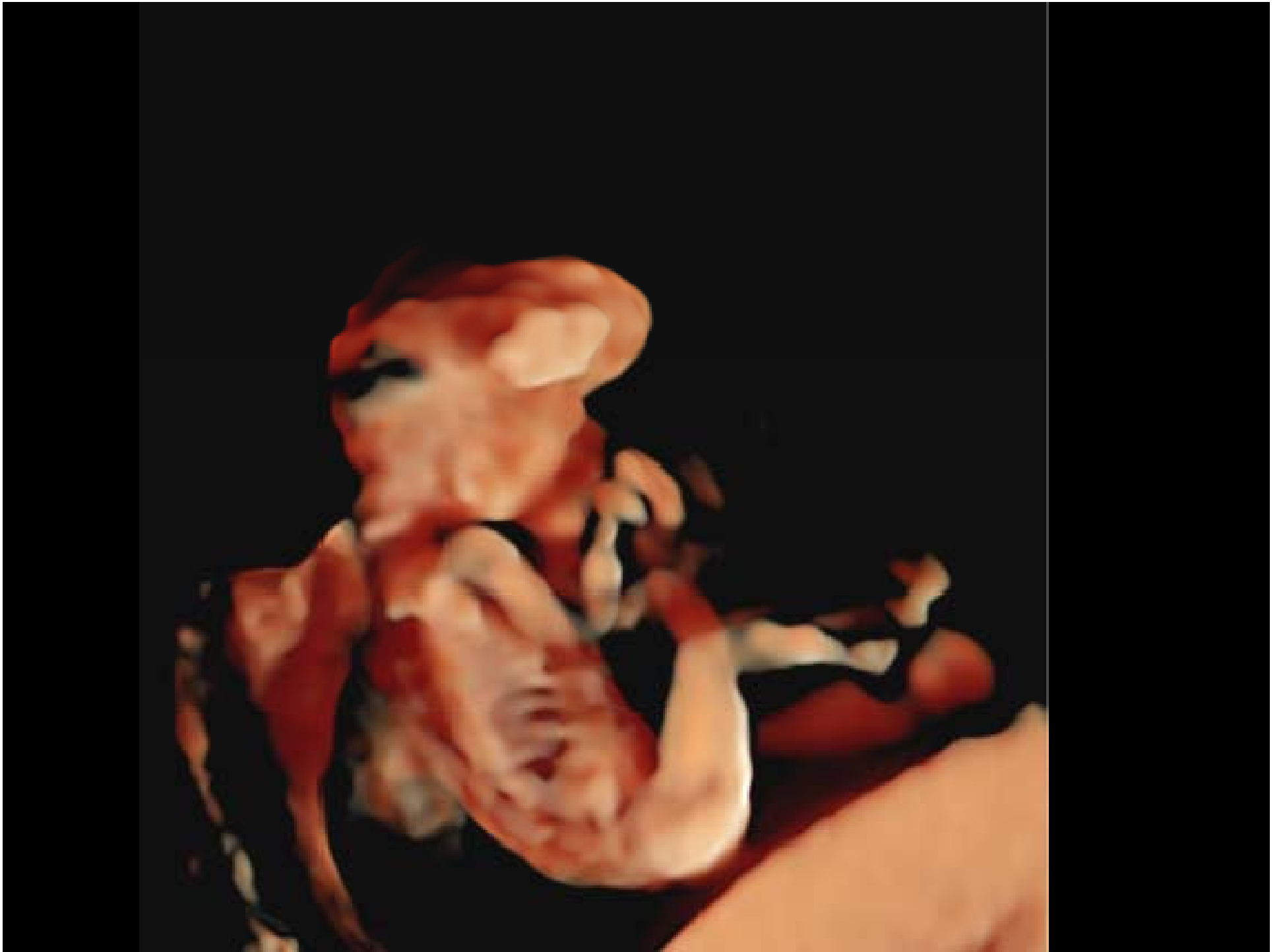


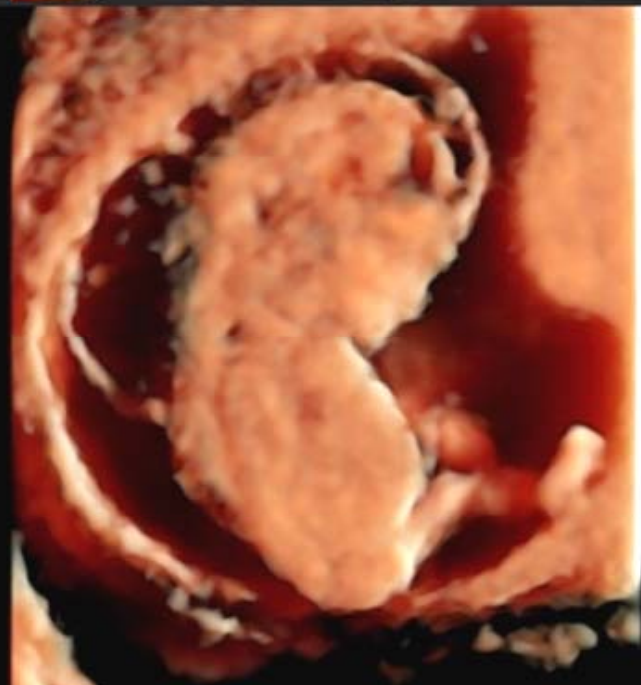
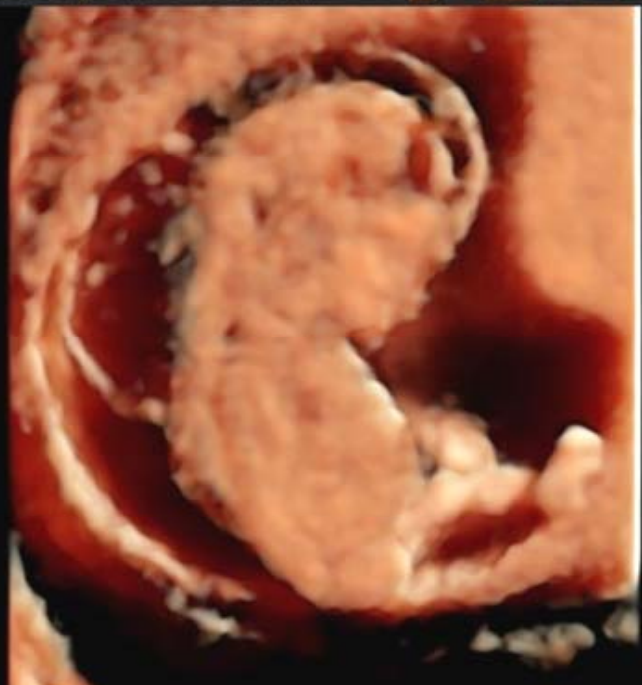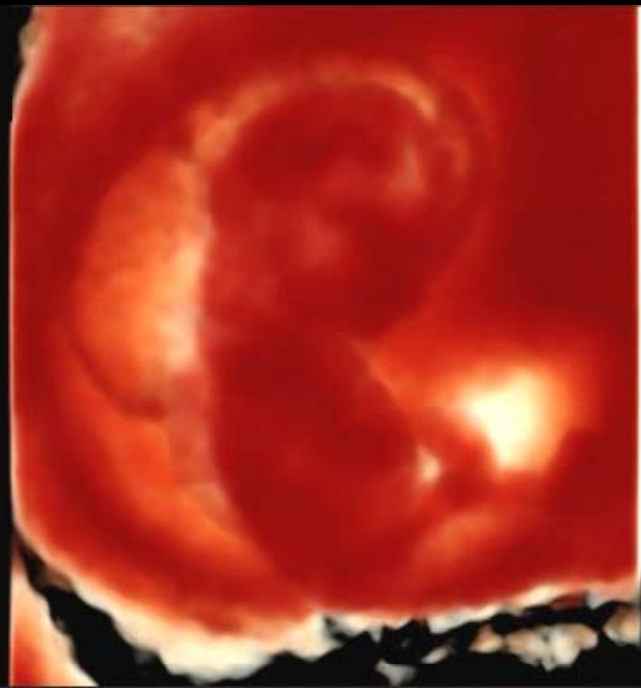
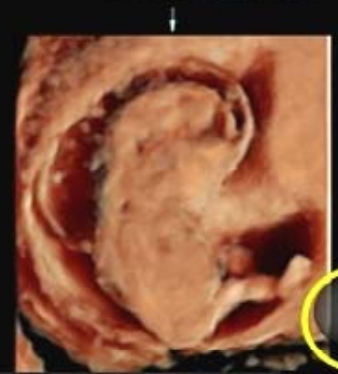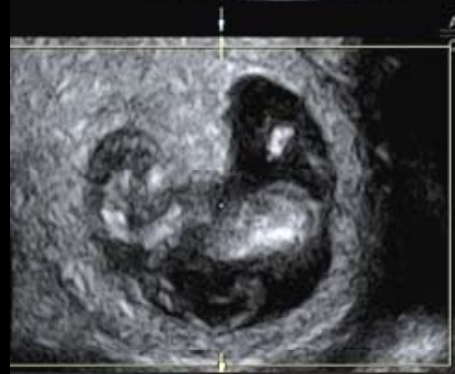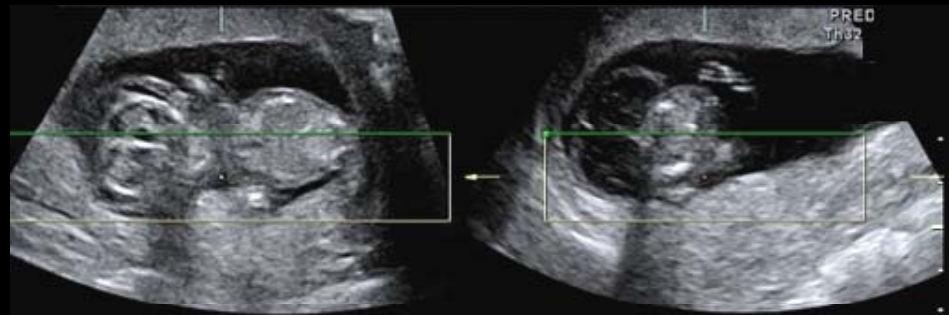





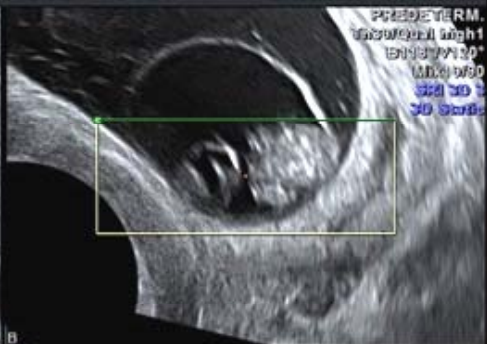
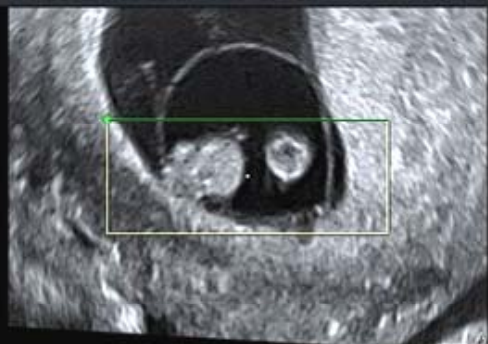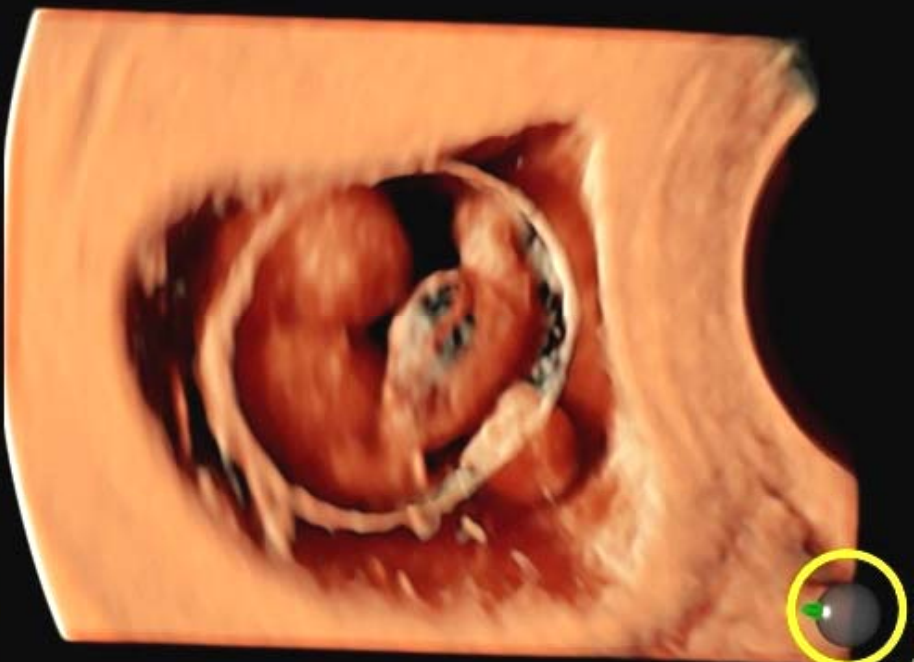
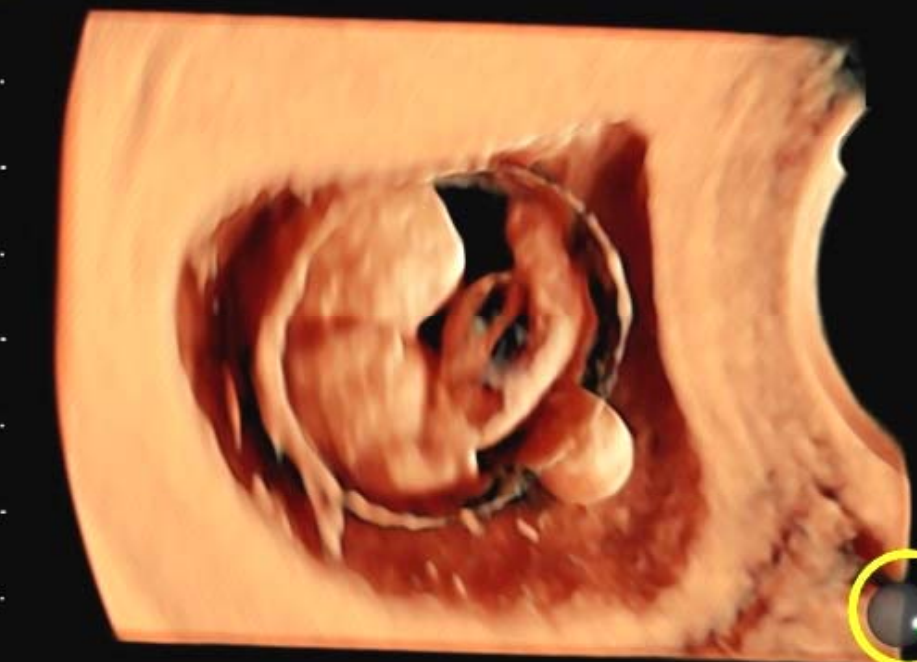
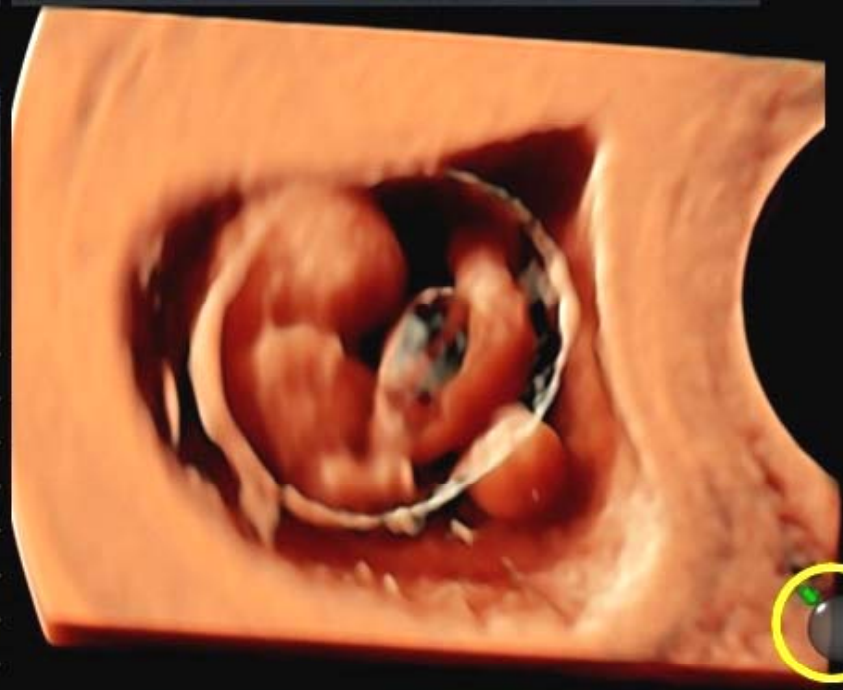
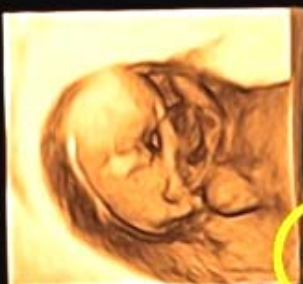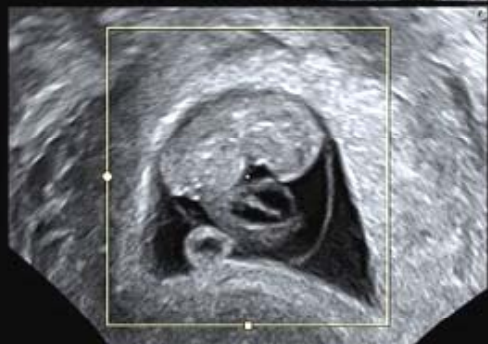A  
B  
C  
3D

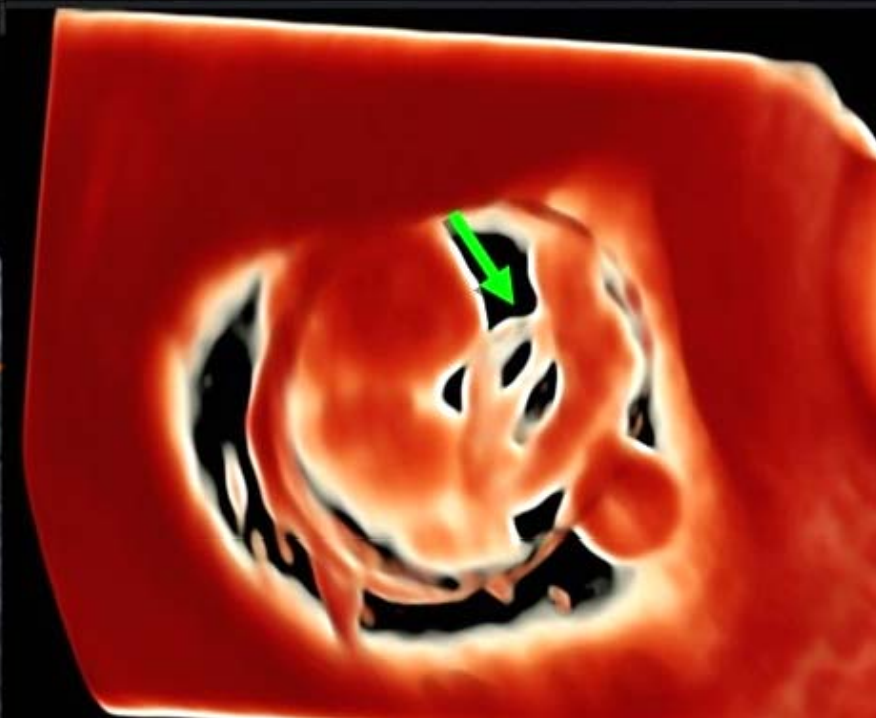
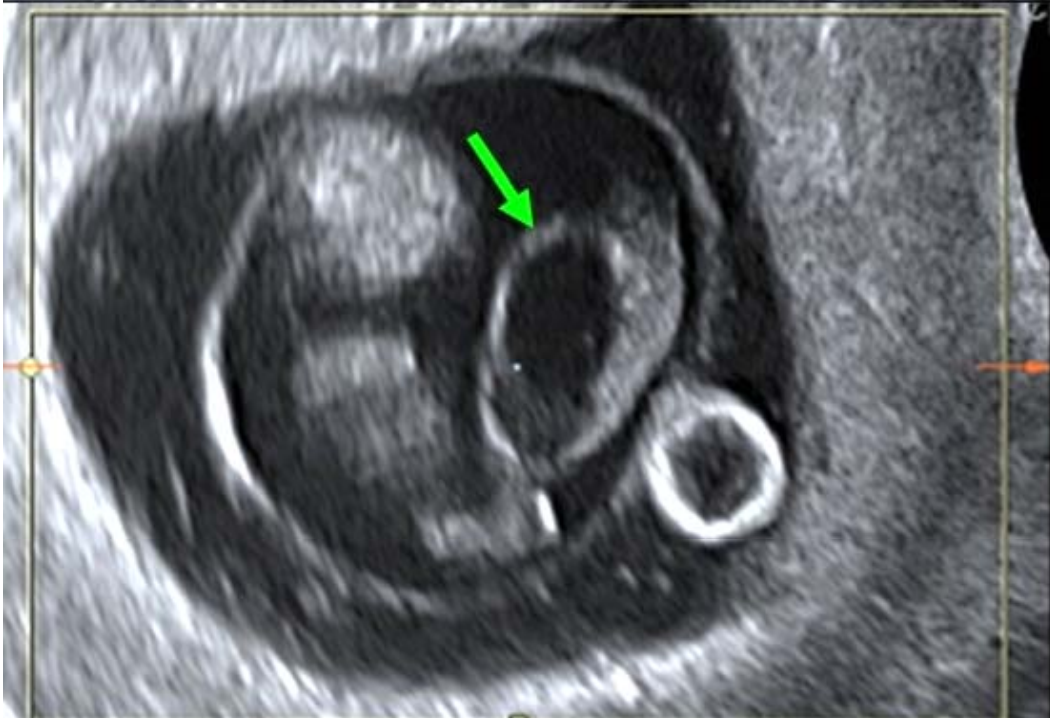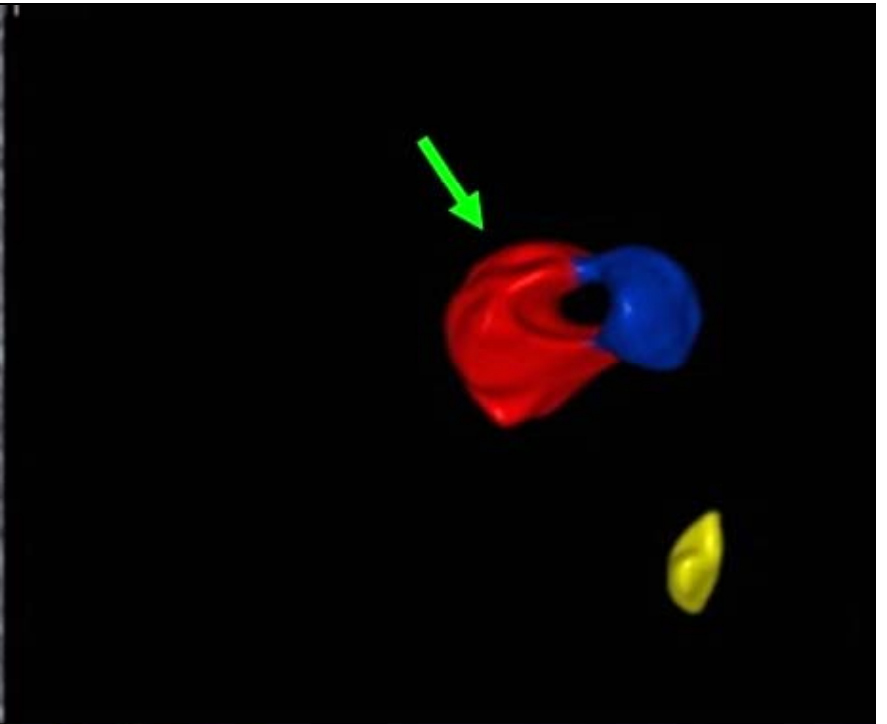
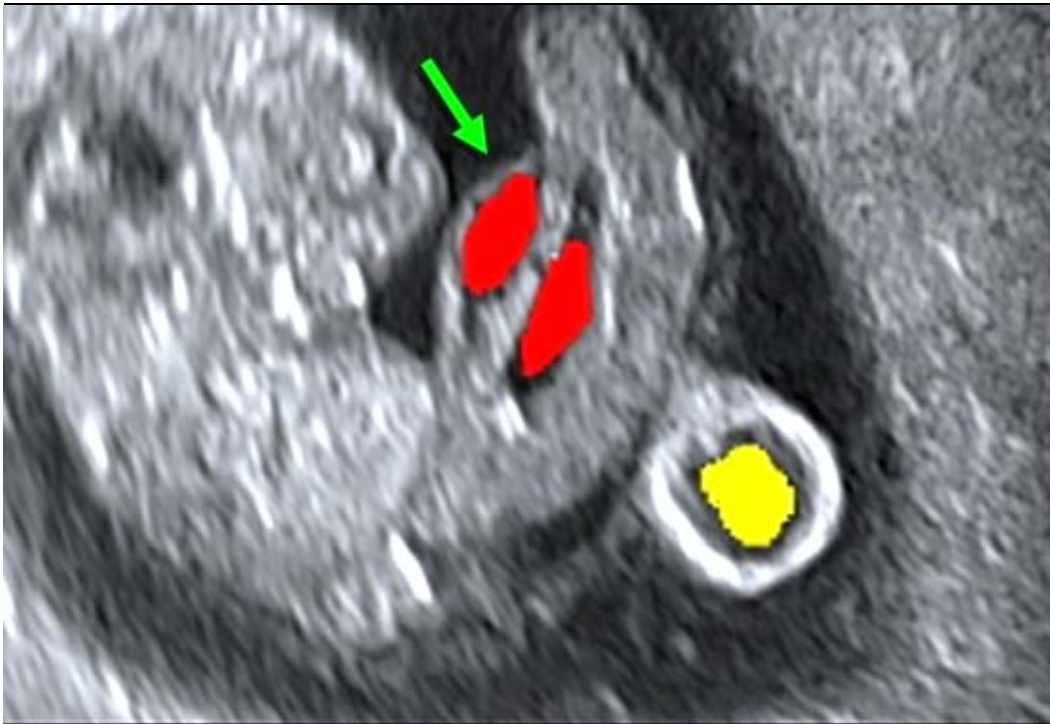


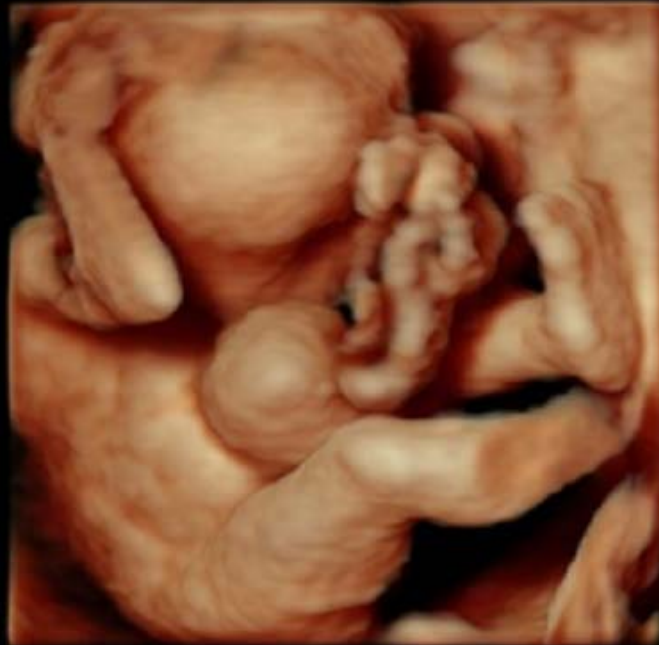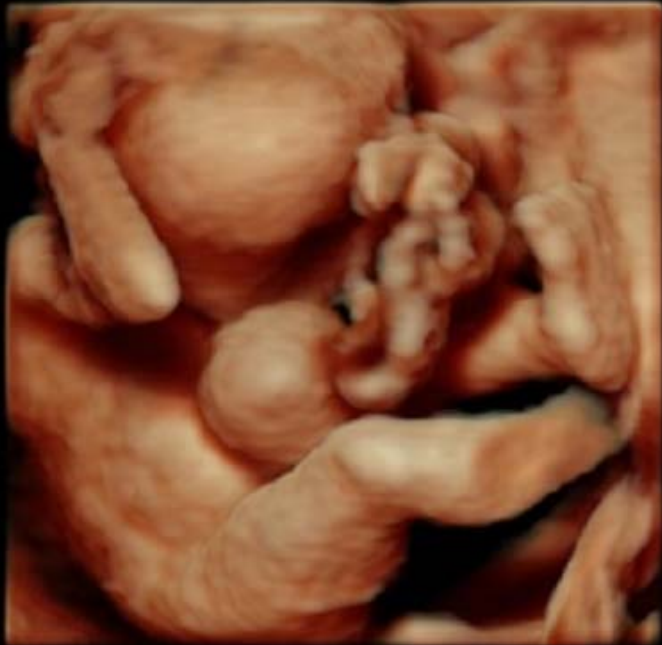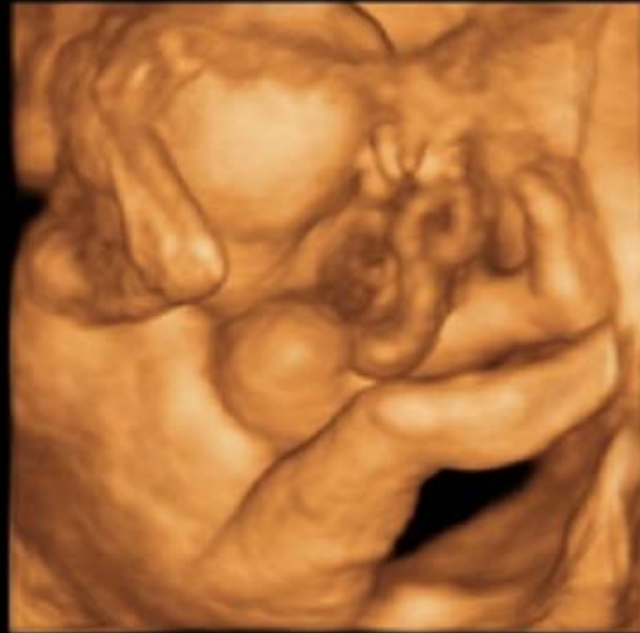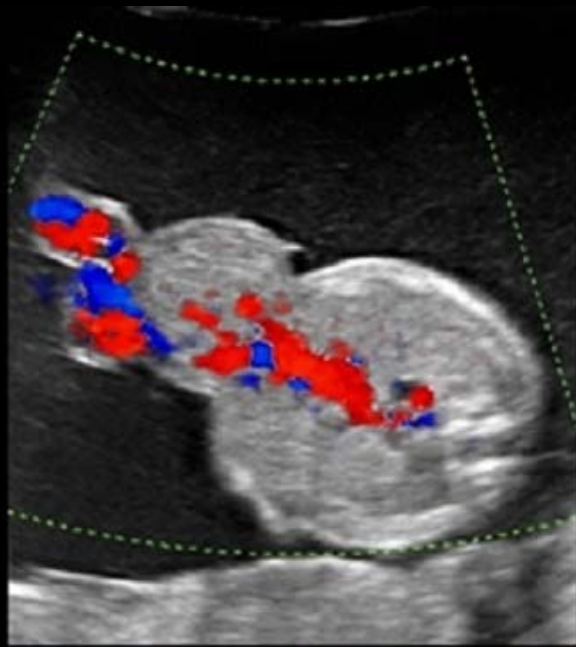


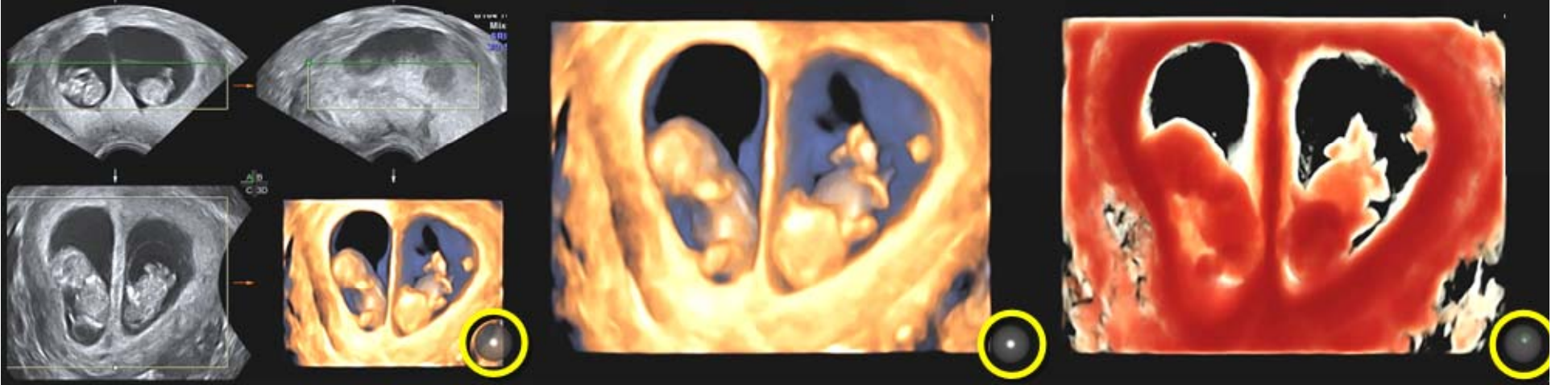


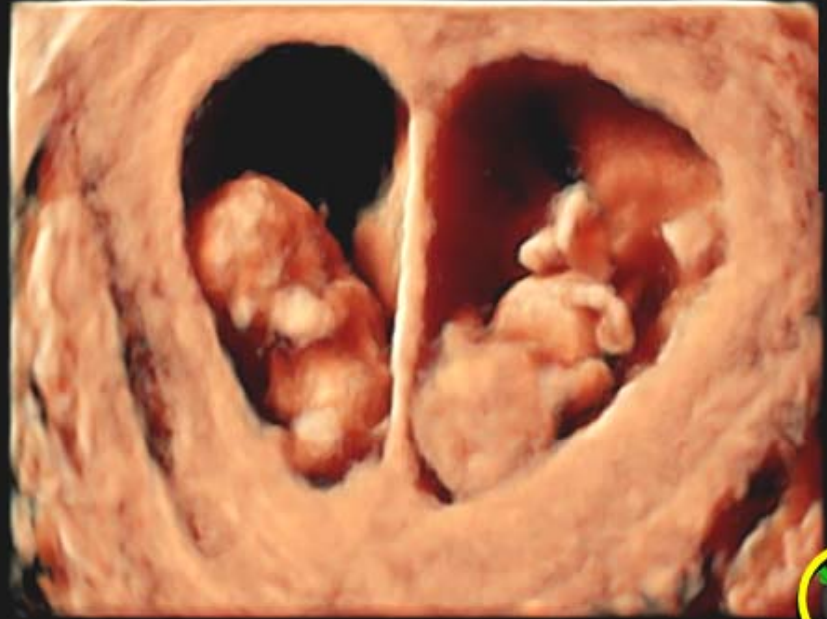
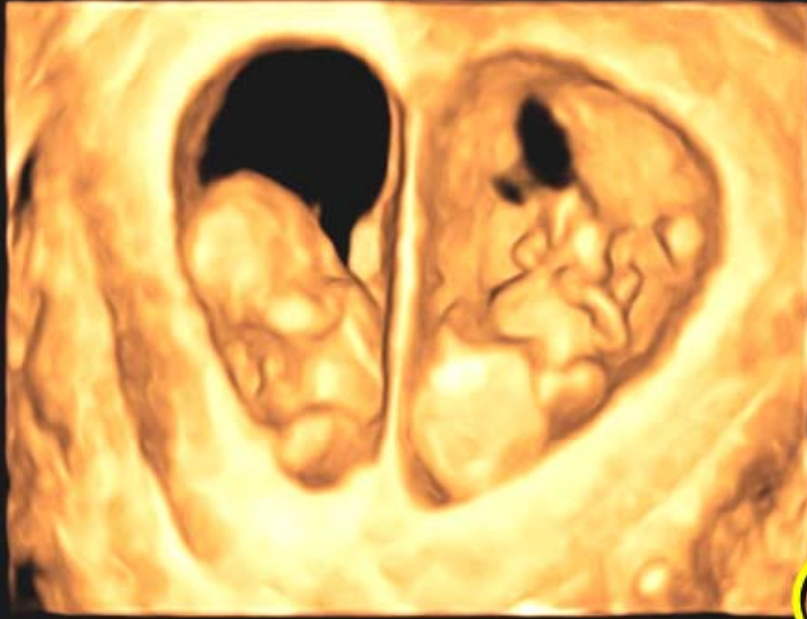
PRETERM  
Axial T1  
T1W1/130°  
MR/0/030  
S11 30 1  
30 Start



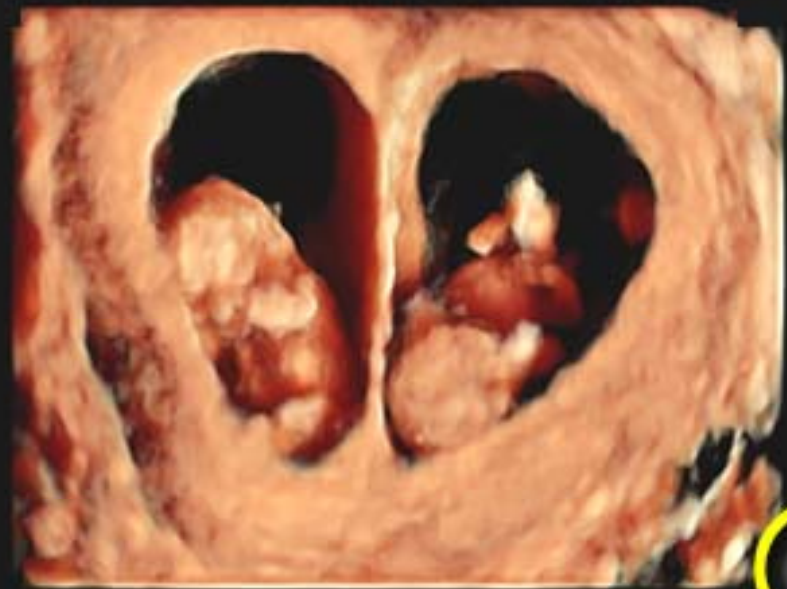
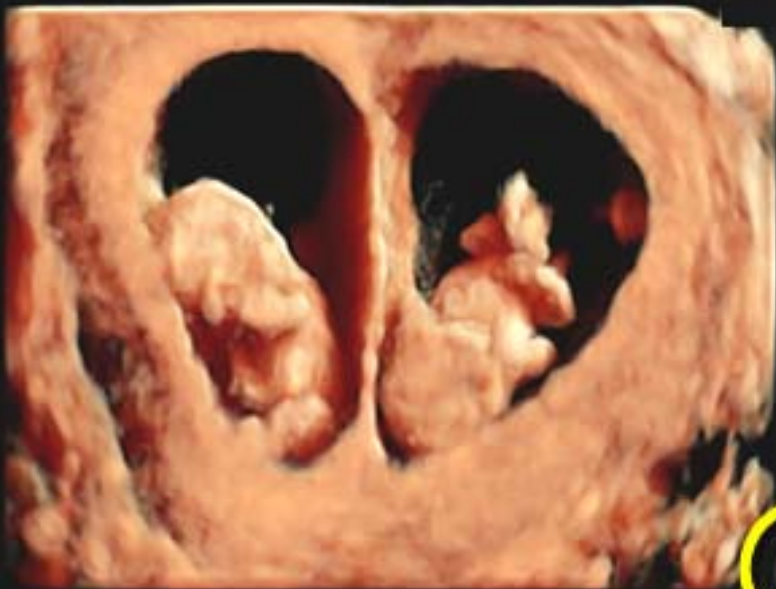
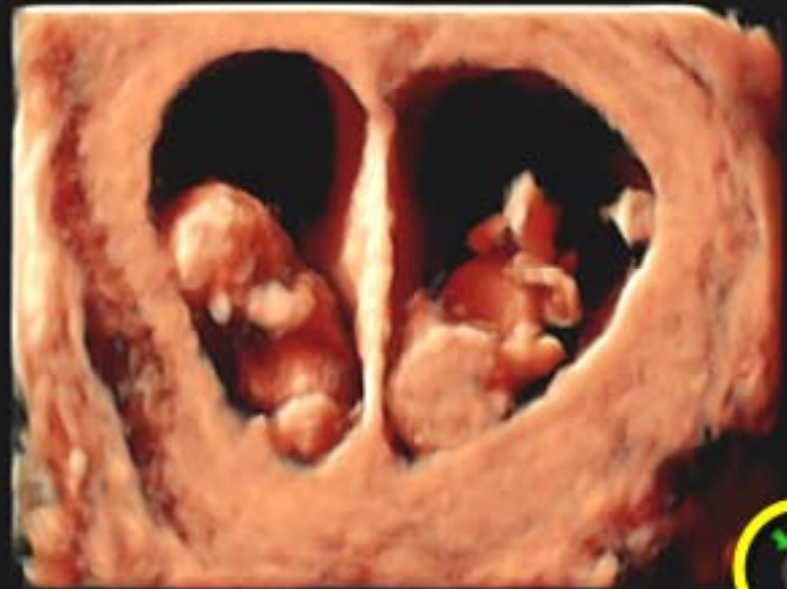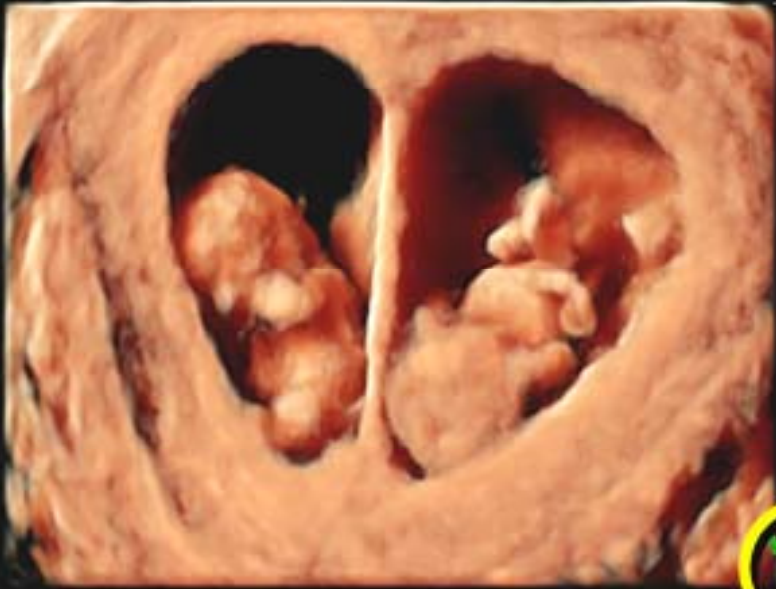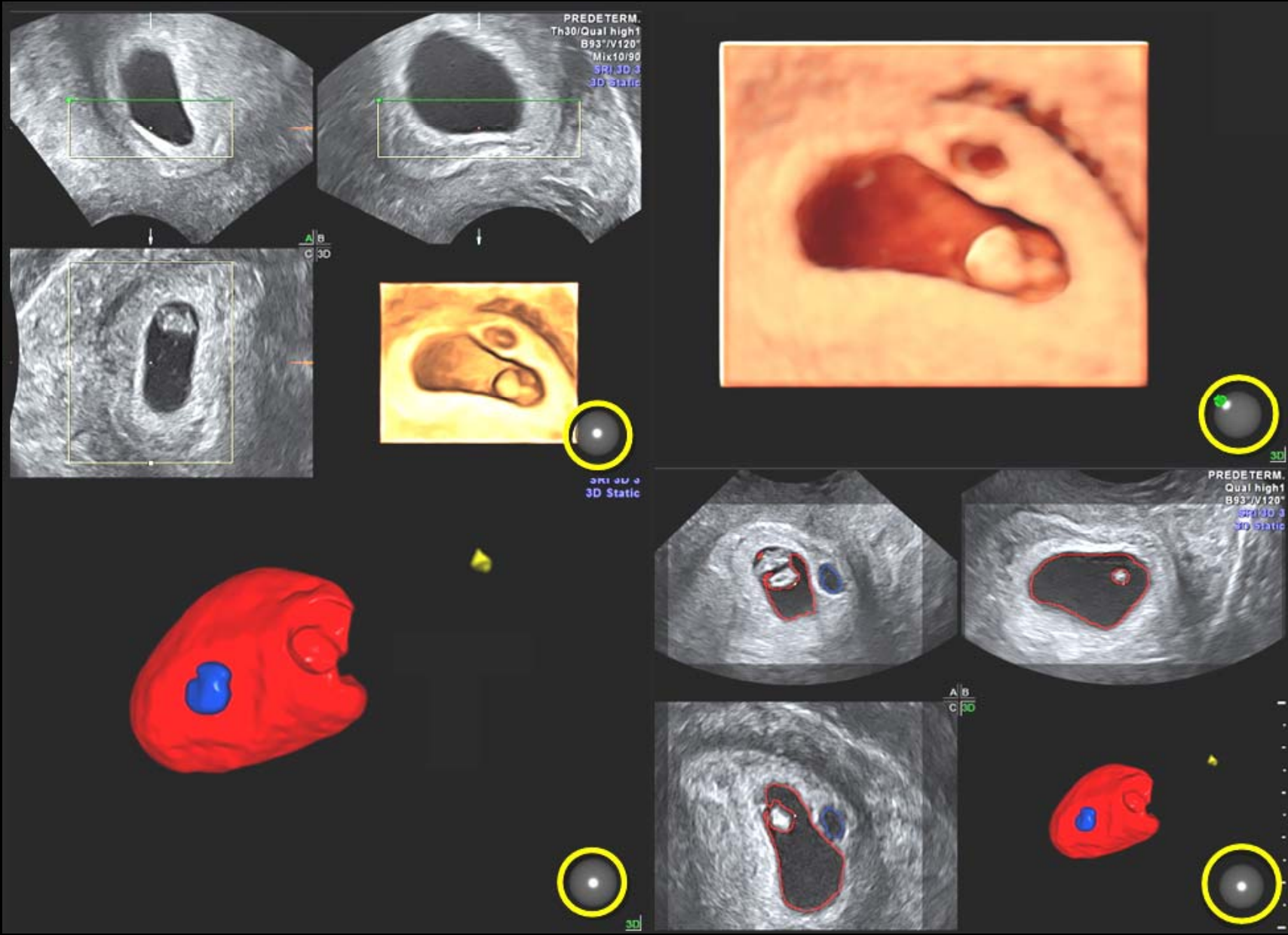





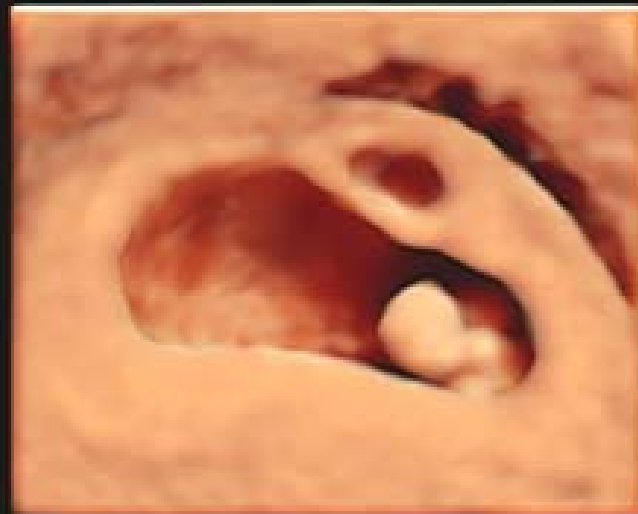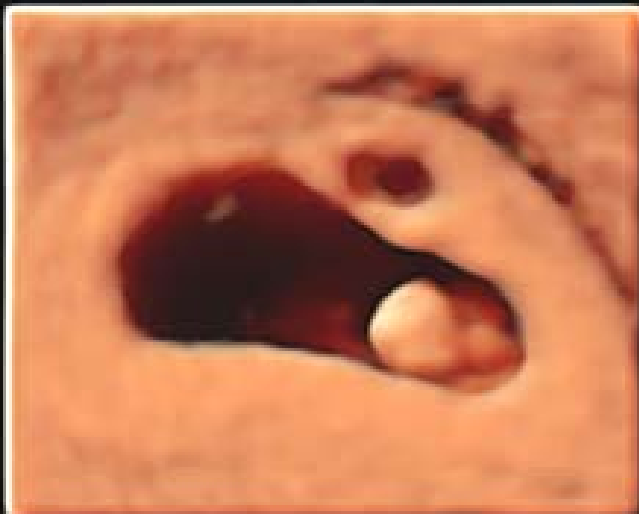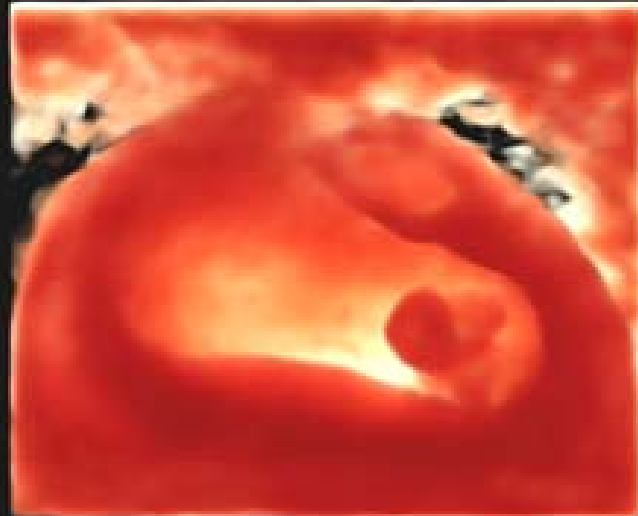
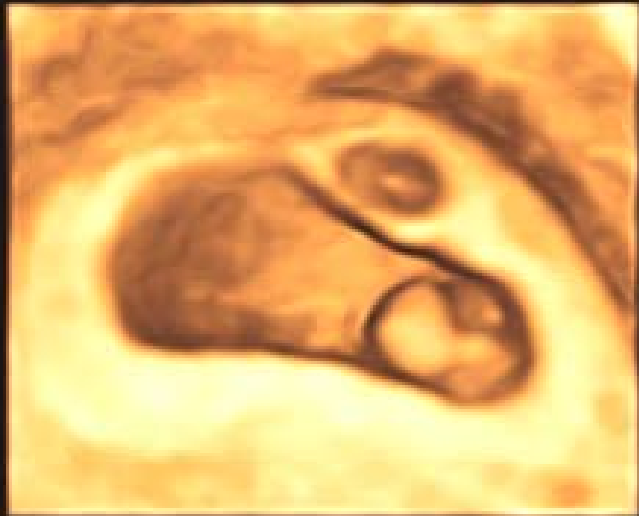




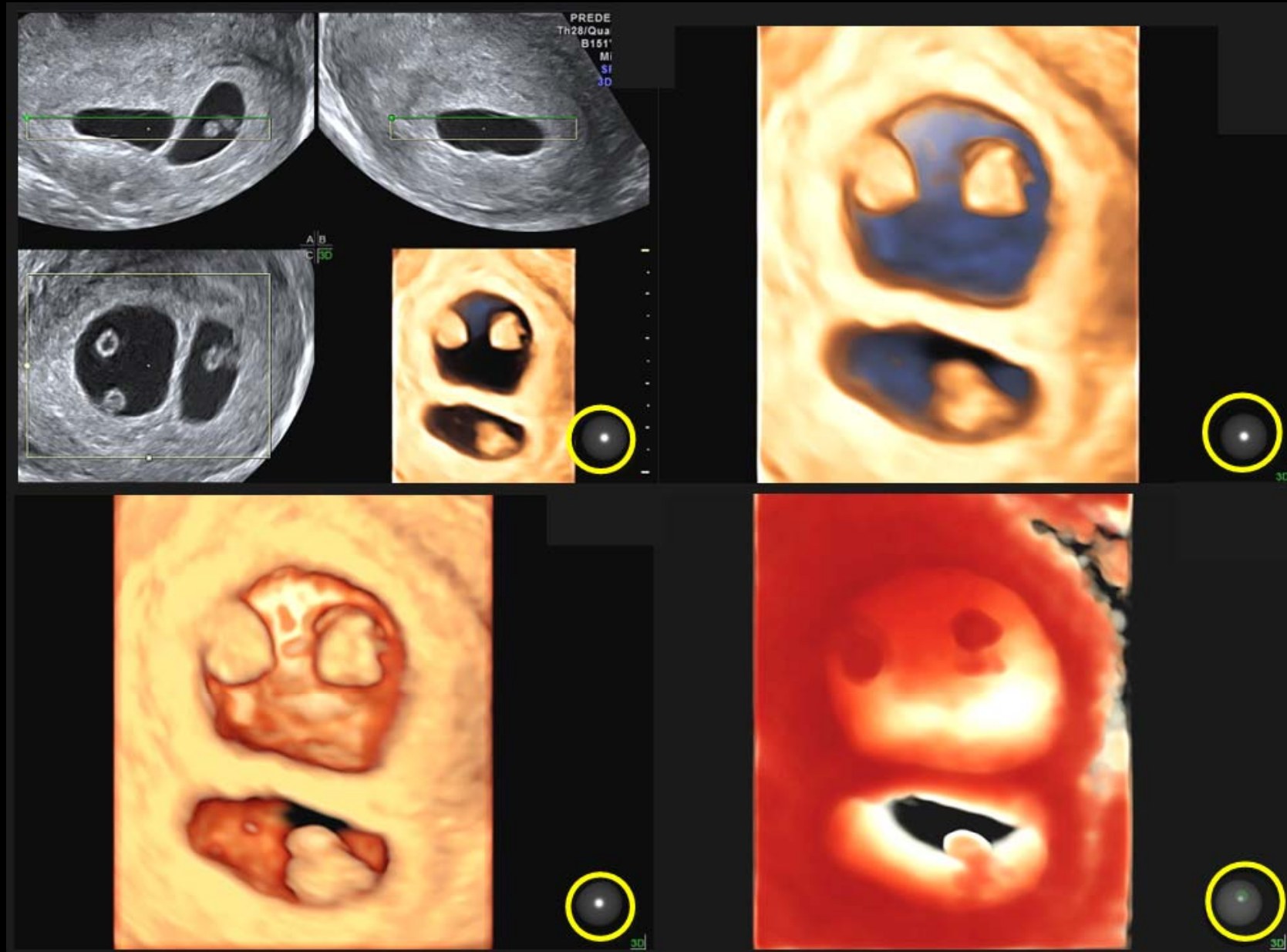




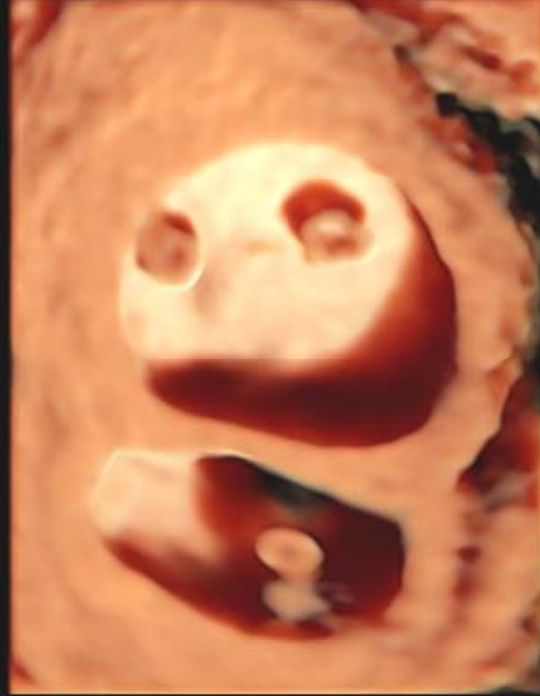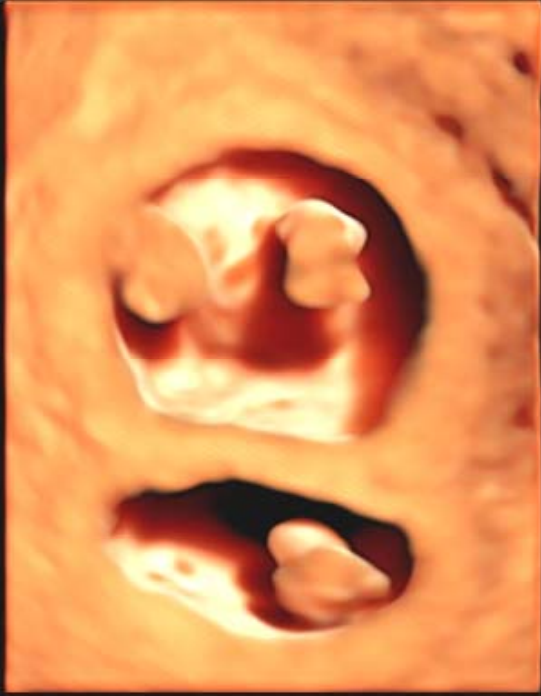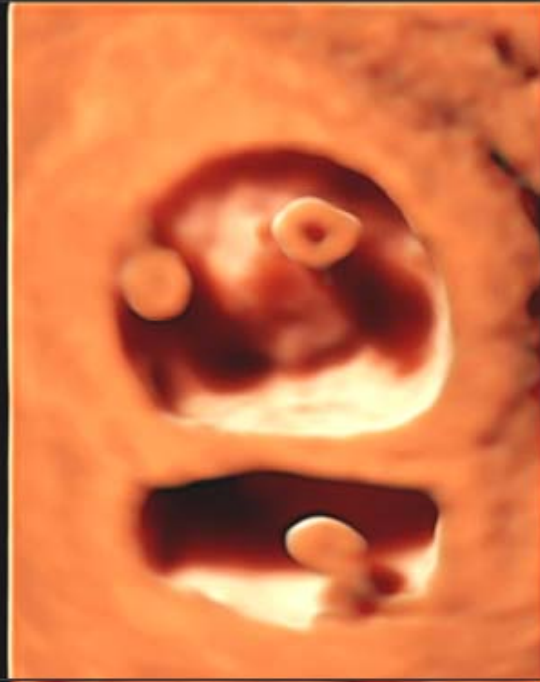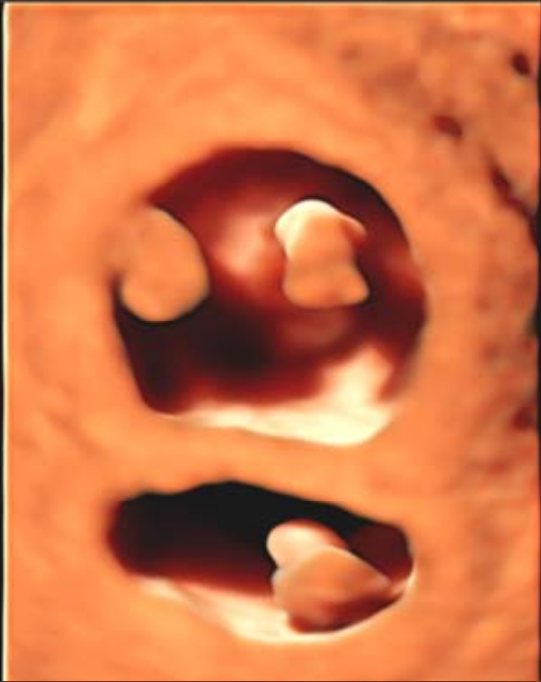Gemelar y wanishing

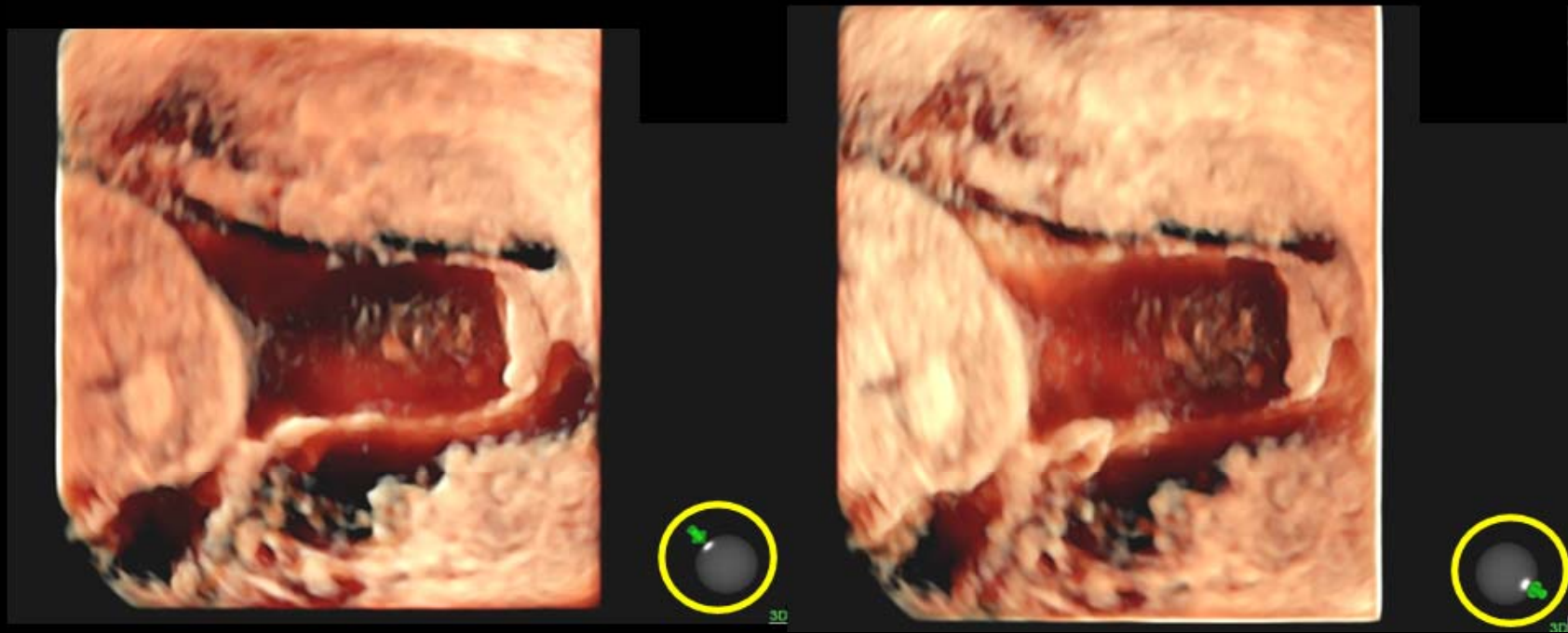
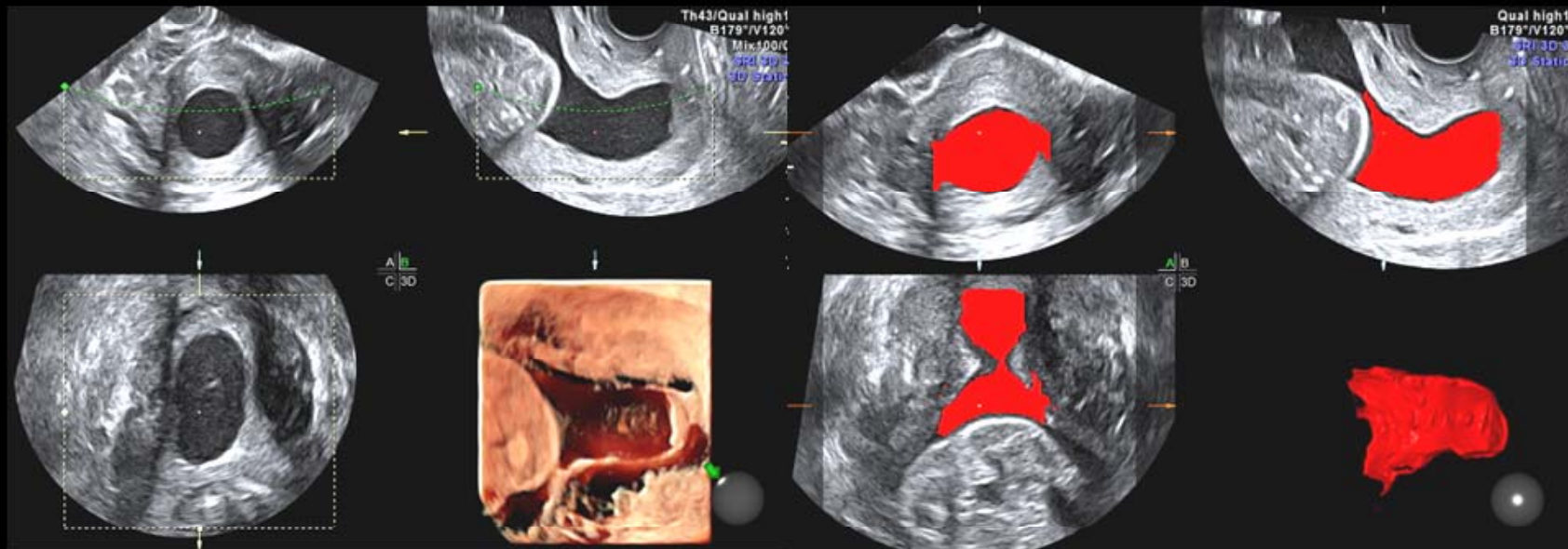


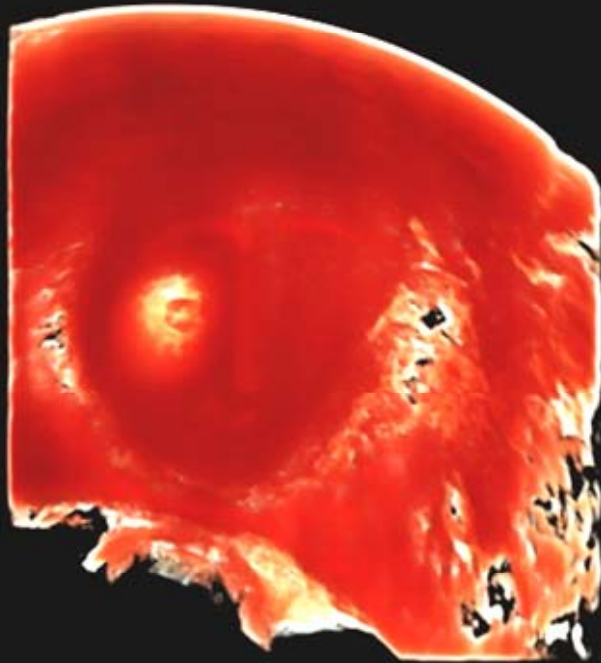
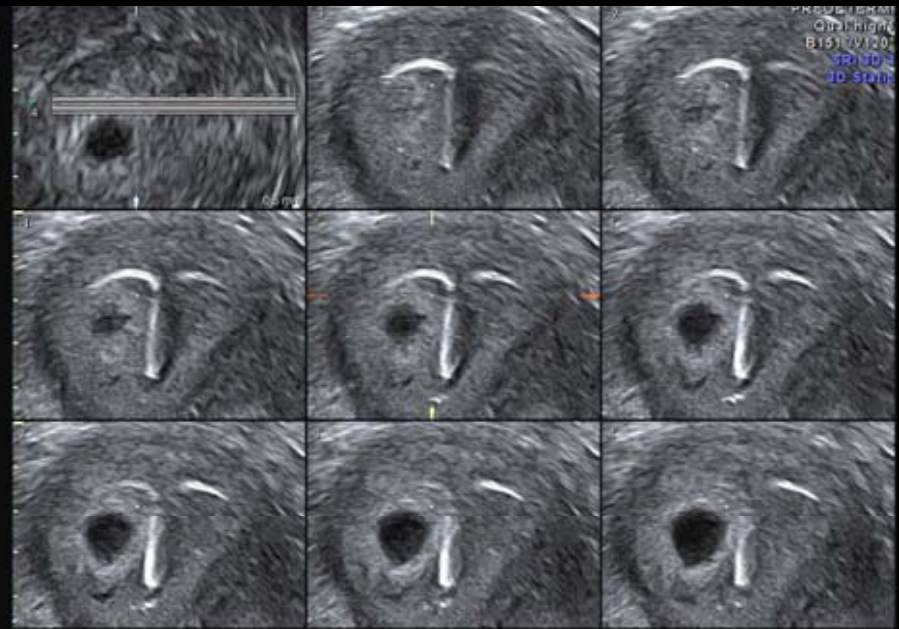
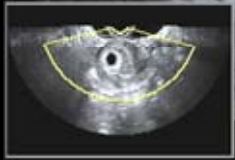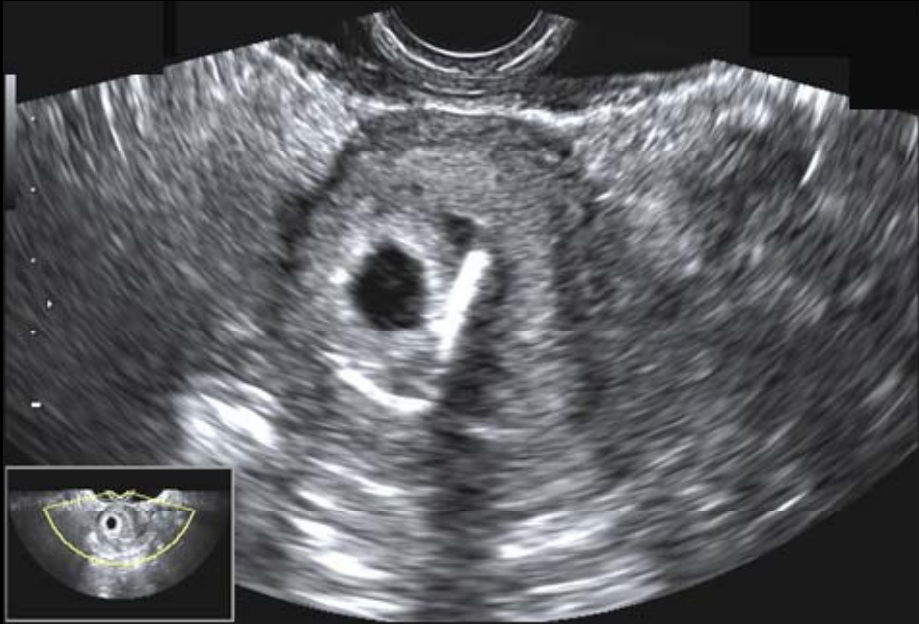# TRILLIZOS ICSI



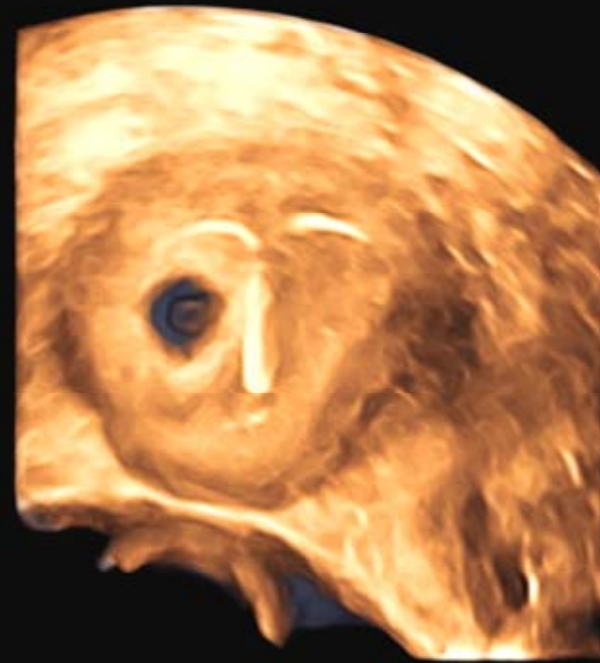


# INCOMPETENCIA CERVICAL





30

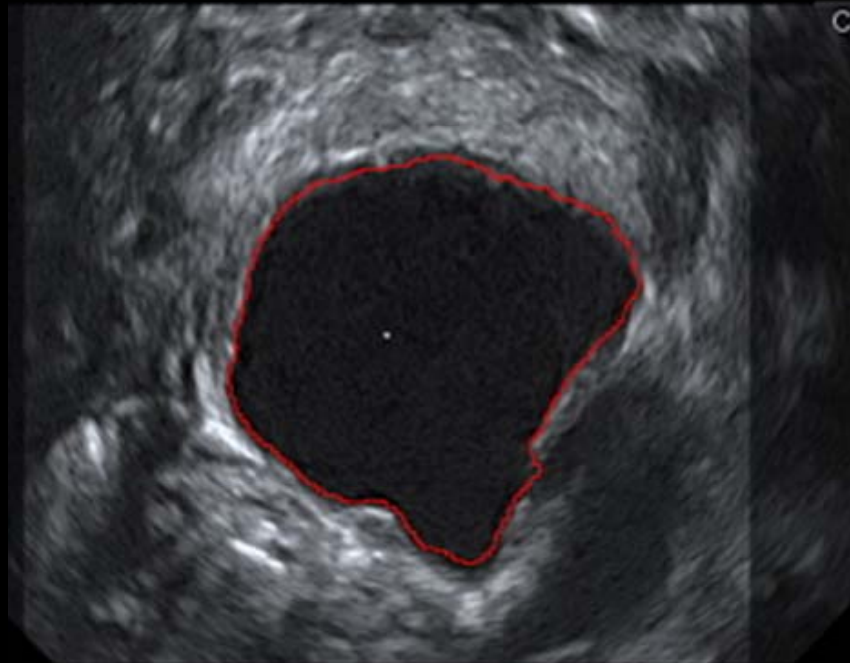
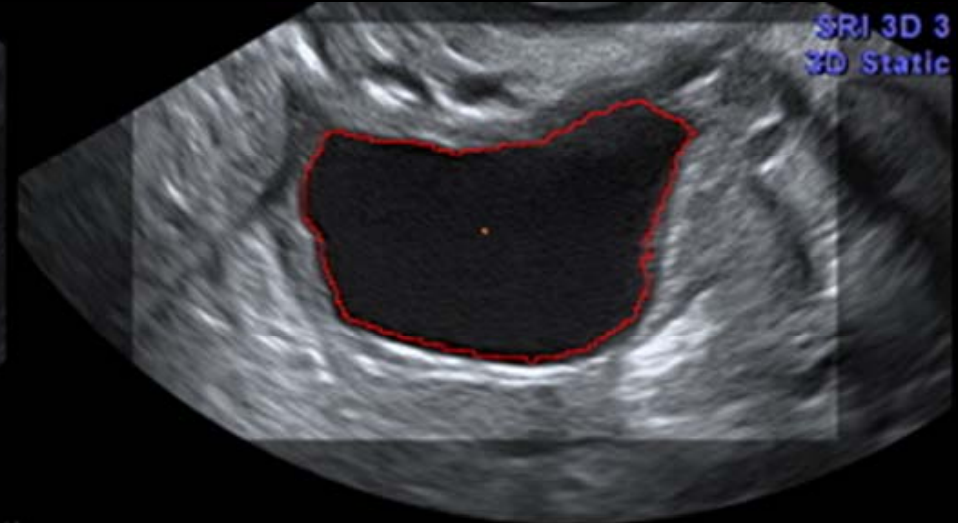
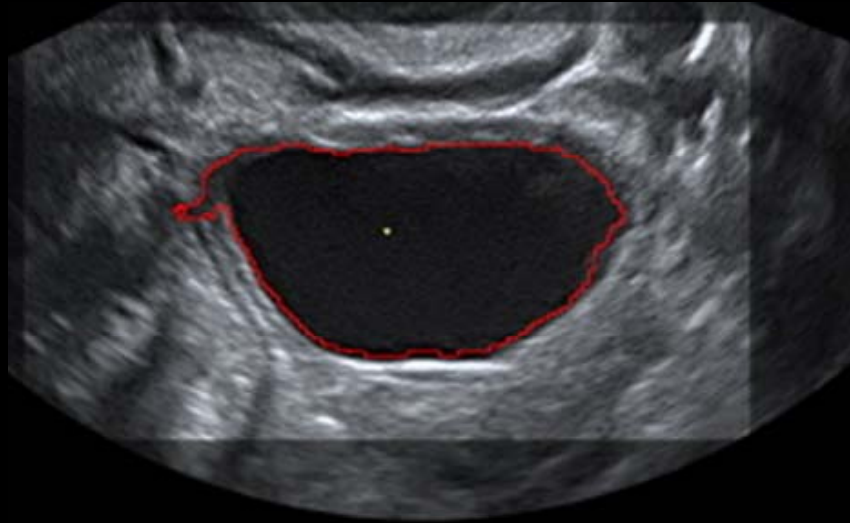
DIU




30

# HIDROSALPINX




A | B  
C | 3D

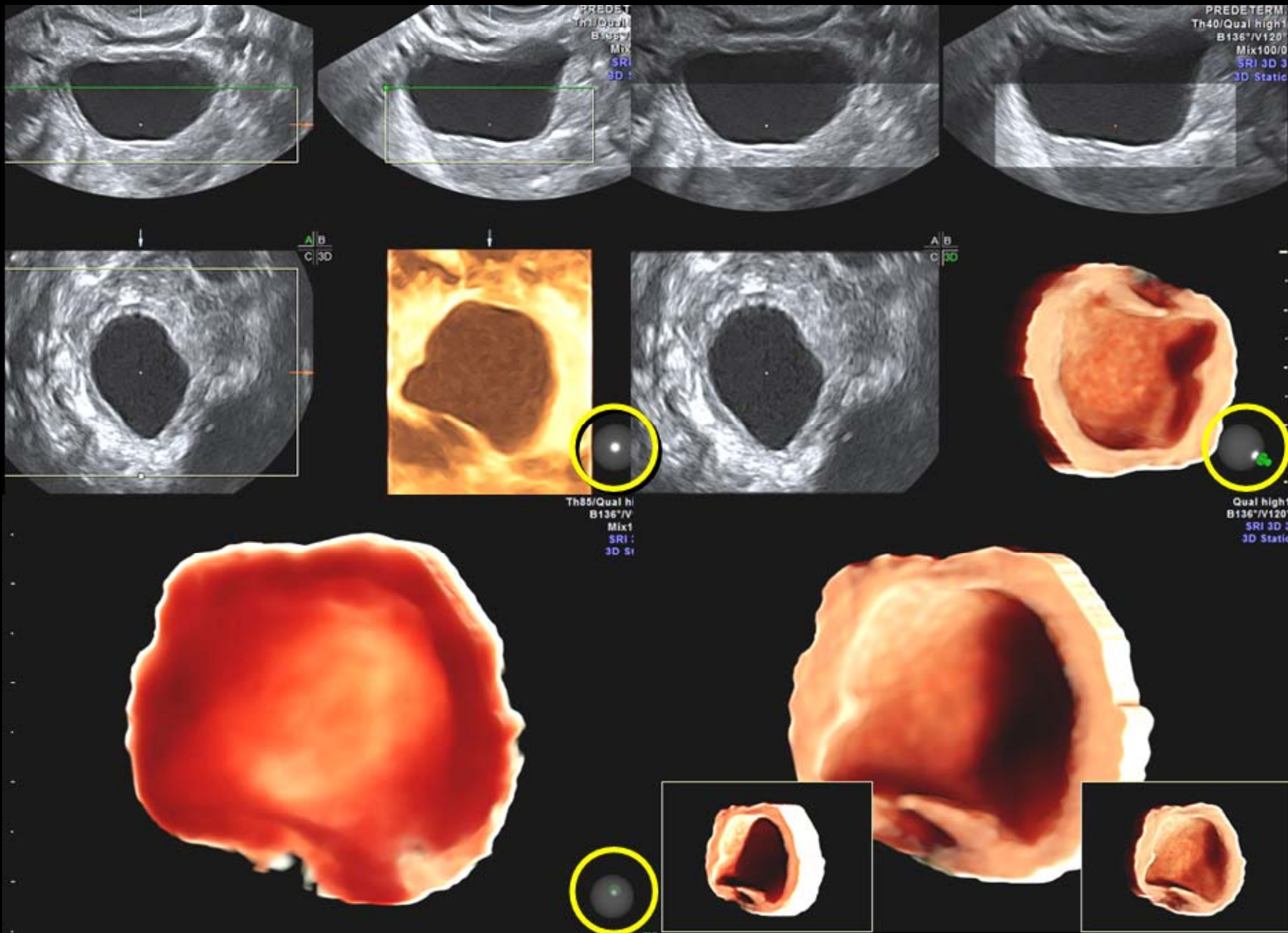


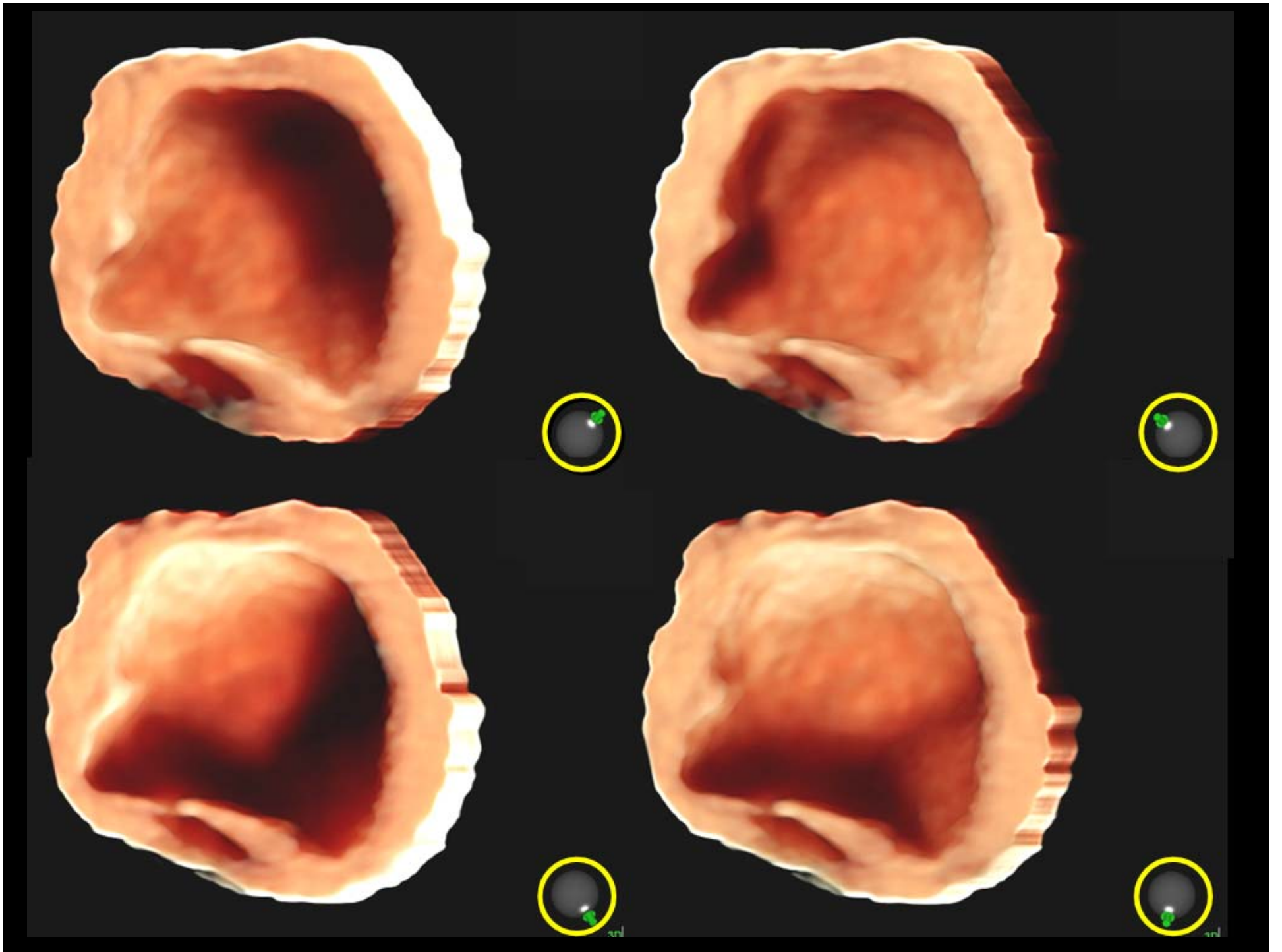


# QUISTE PURO

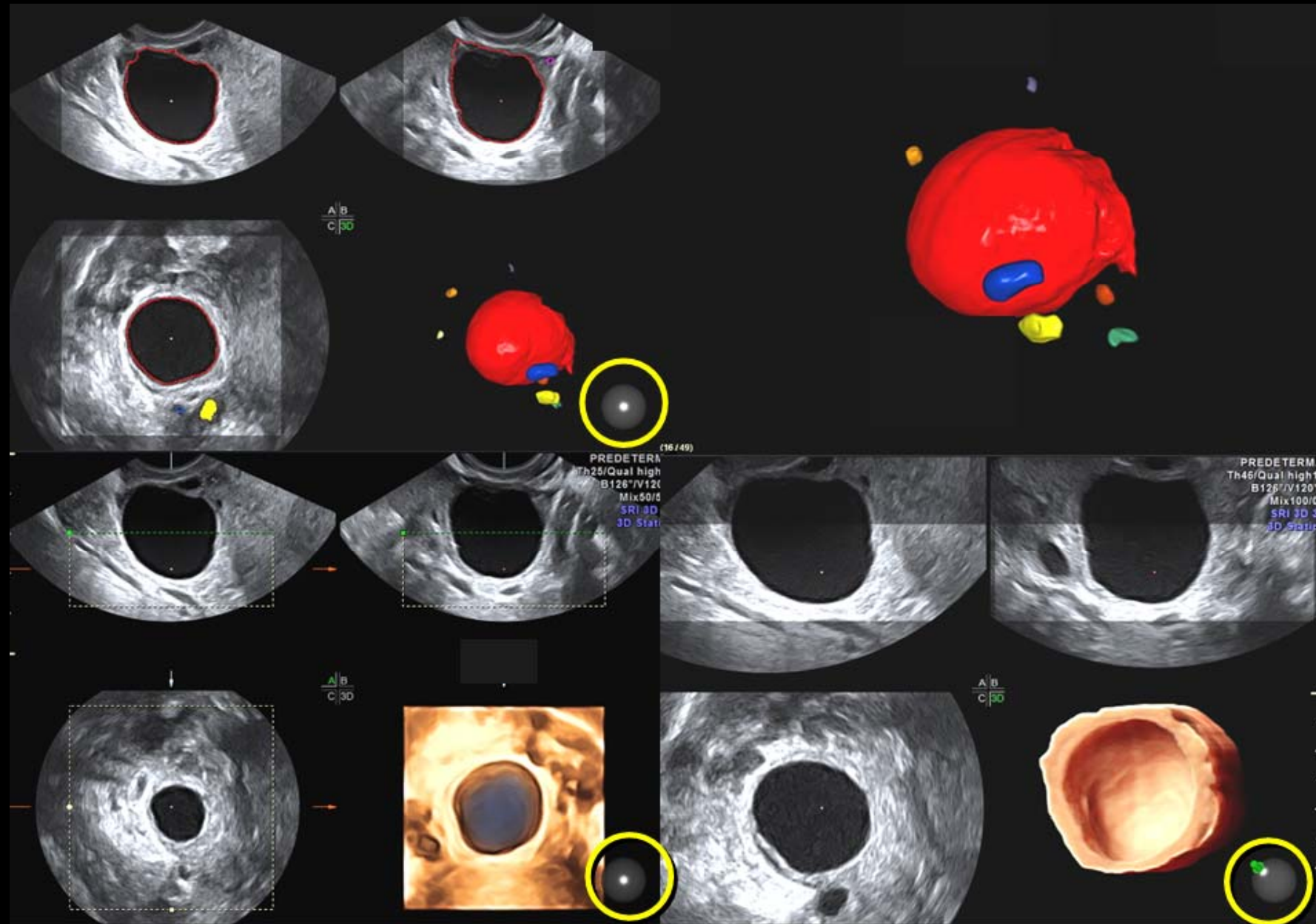


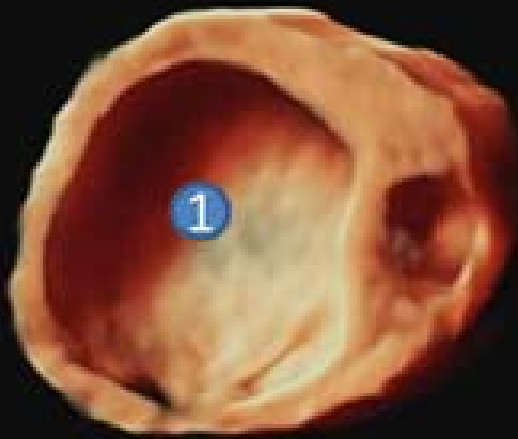
# QUISTE PURO



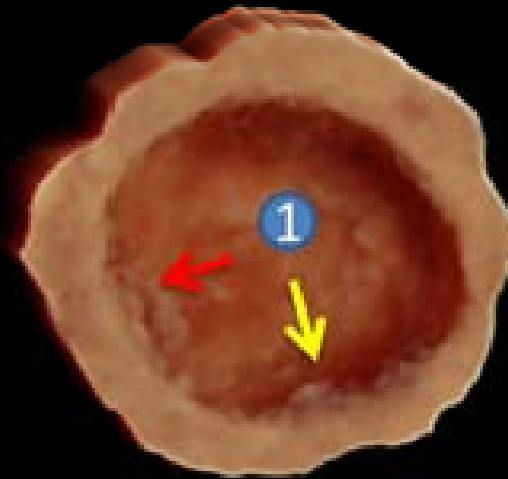


# FOLICULOGENESIS

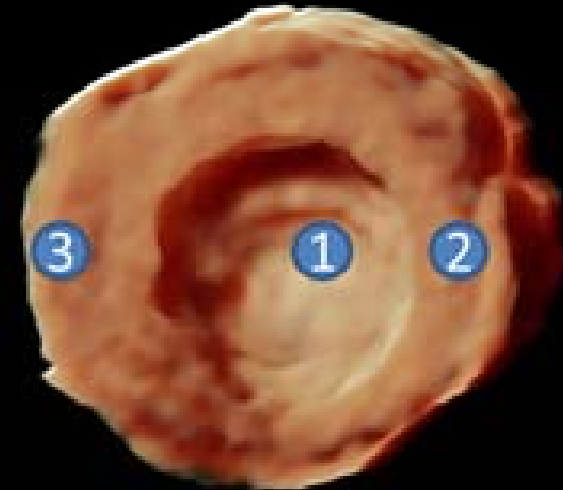



A

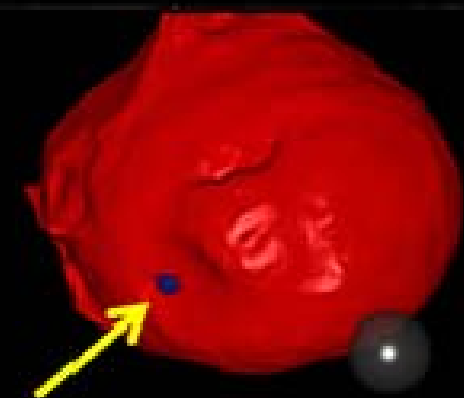
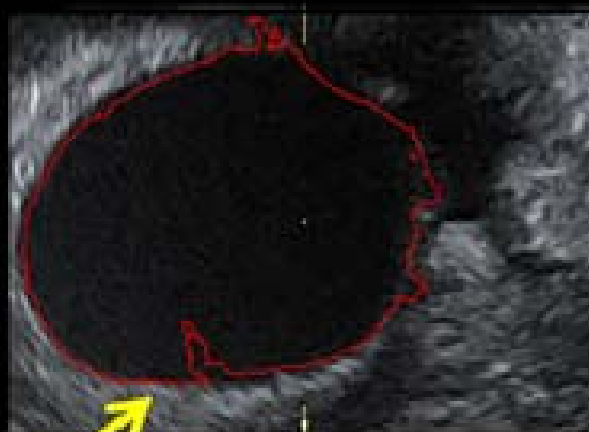
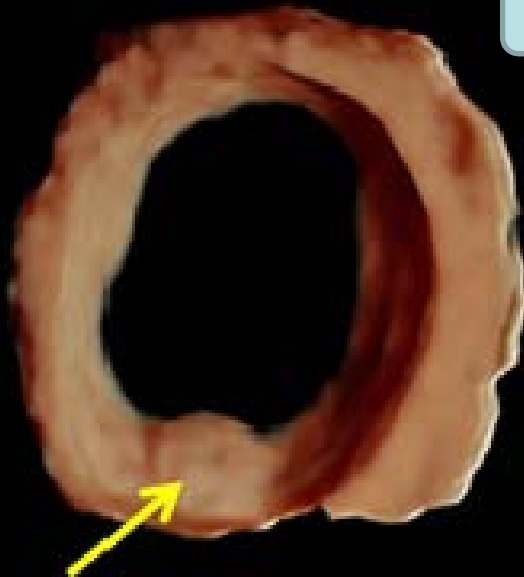
B

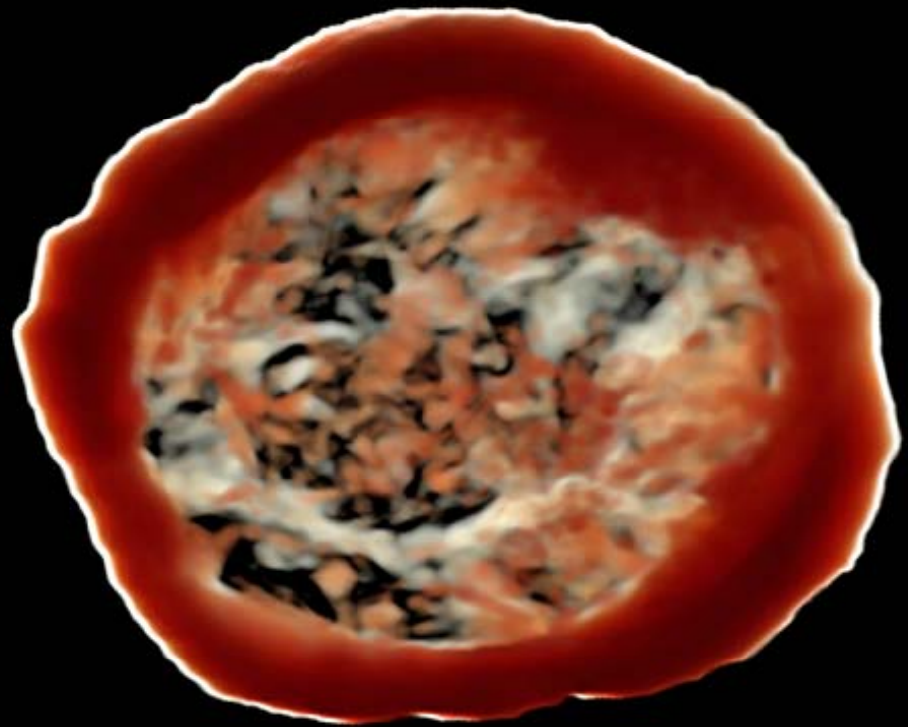
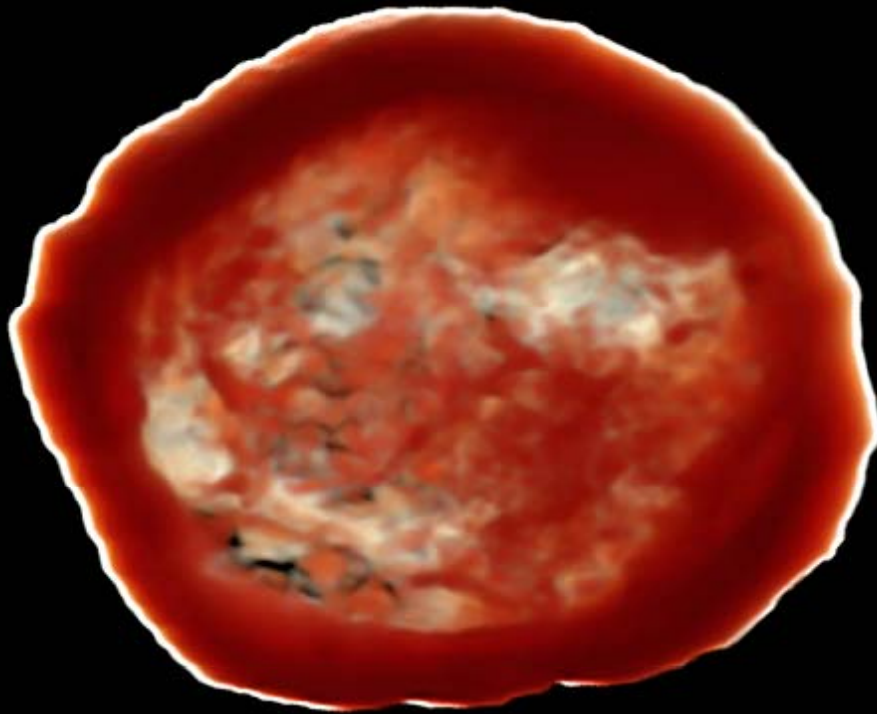


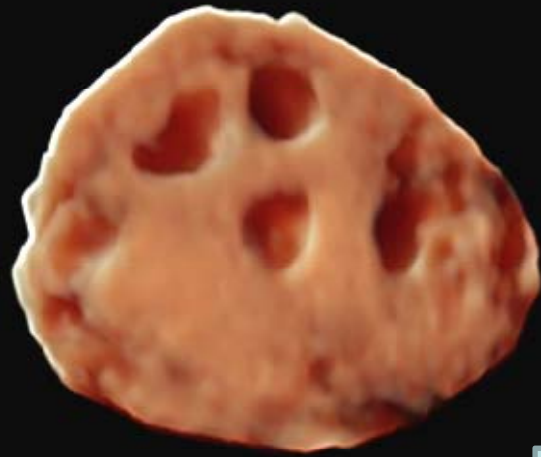C

**ROSENSTRAUCH DORN UND  
GRANULOSA SPALTUNG**

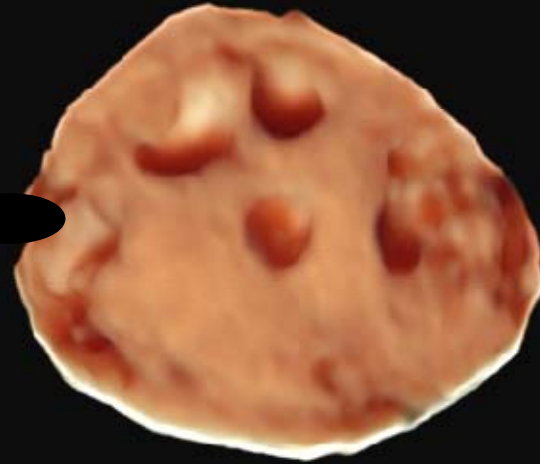


**CUERPUS LUTEUM  
RETICULARIS**

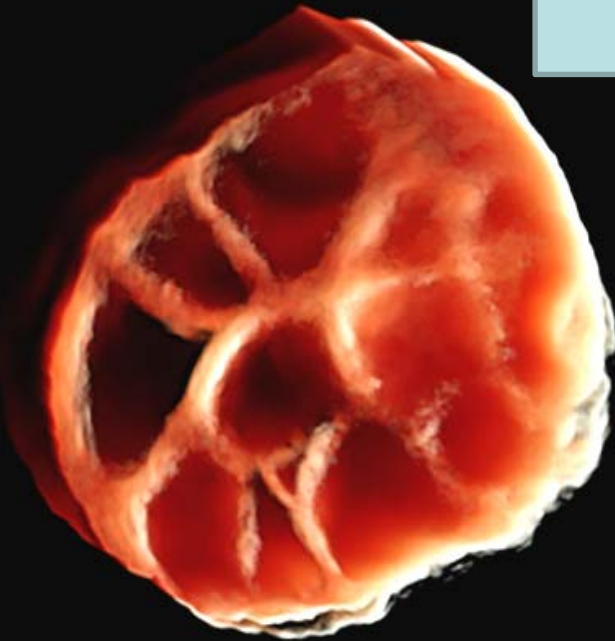




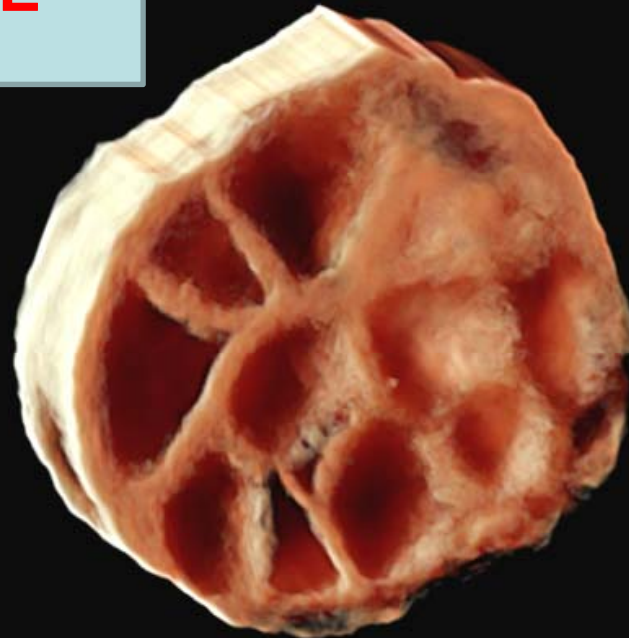A



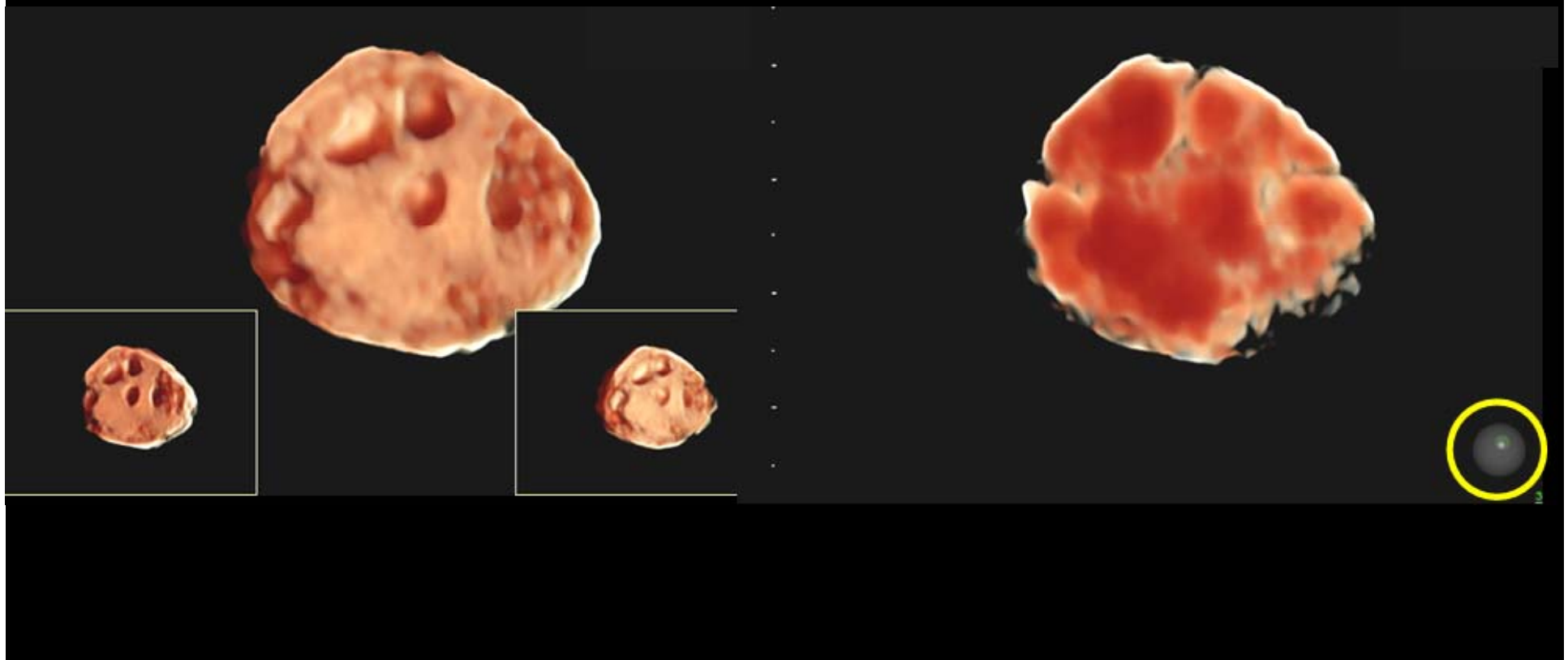
OVARIELLE  
RÜCKHALT  
NIEDRIGE  
HOCH



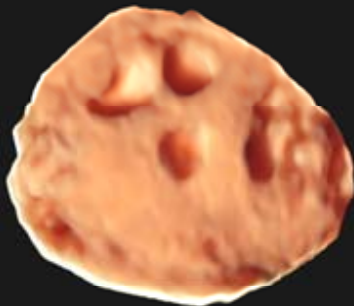
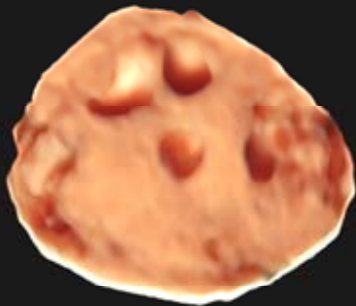
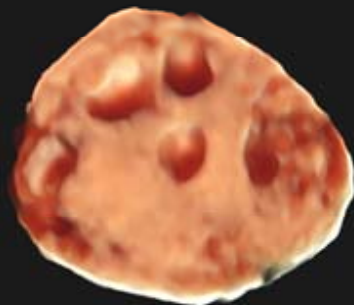
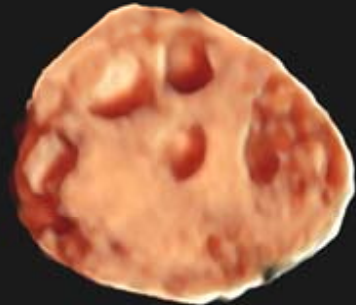
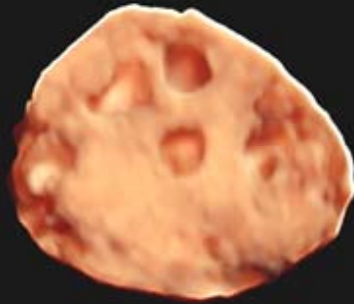
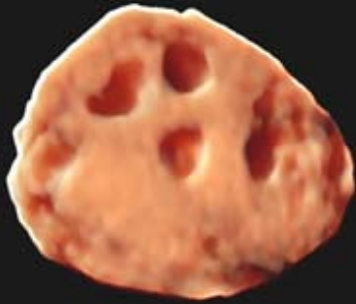B



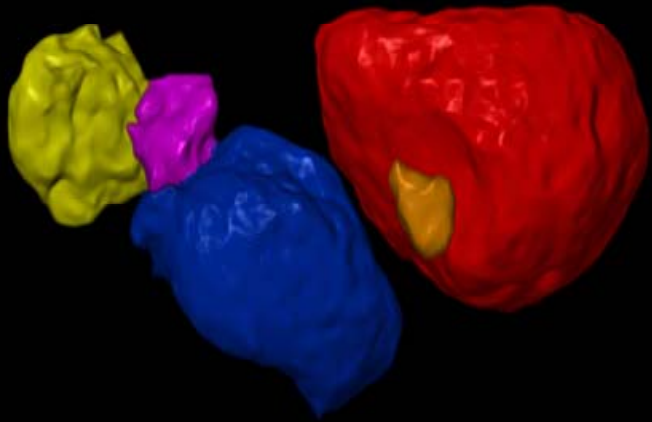
# OVARIELLE RÜCKHALT MAXIMALE BELEUCHTUNG



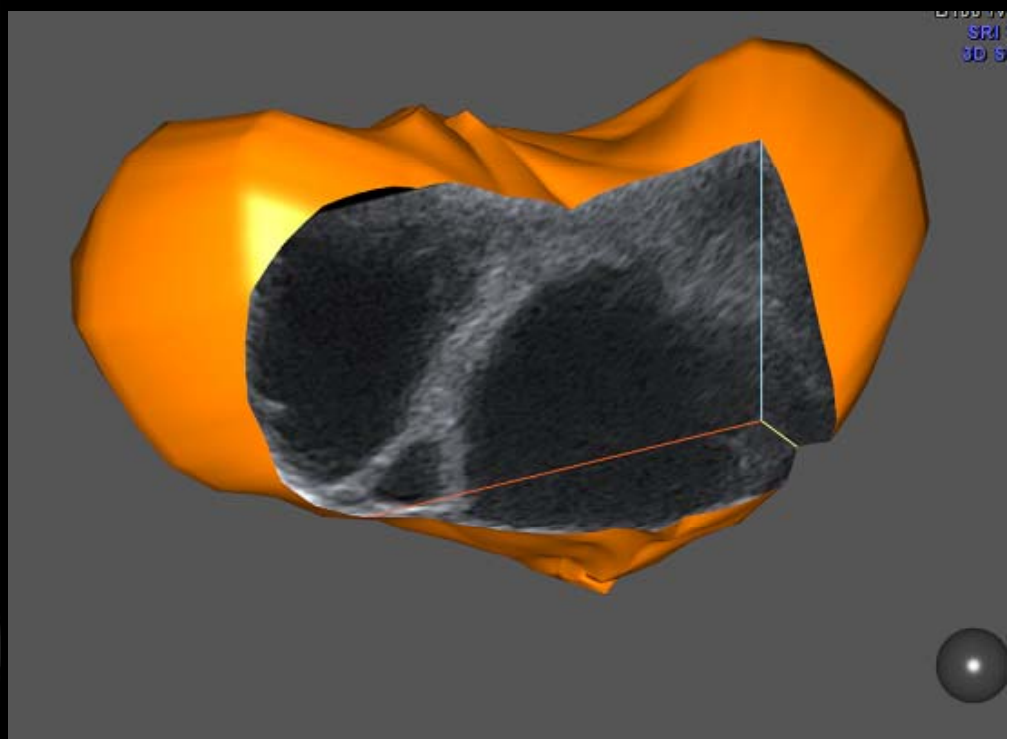




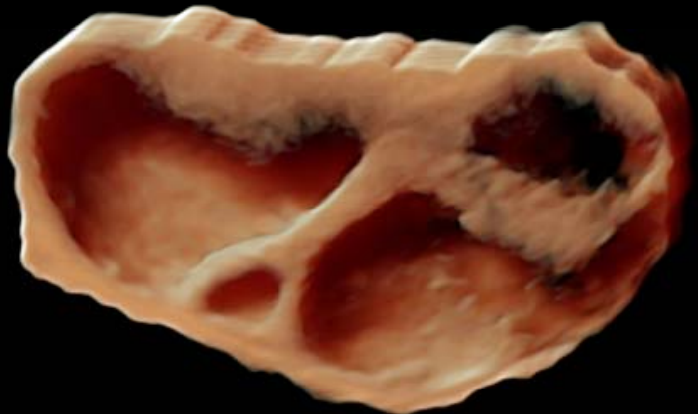
**RESERVA OVÁRICA**  
**OVARIELLE RÜCKHALT**



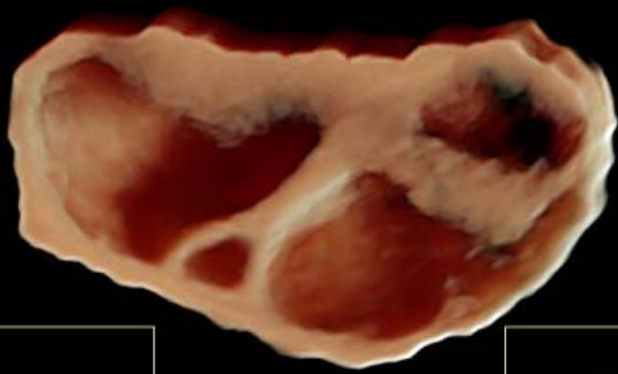
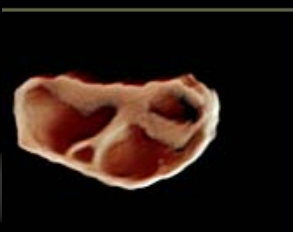
Div  
1  
3



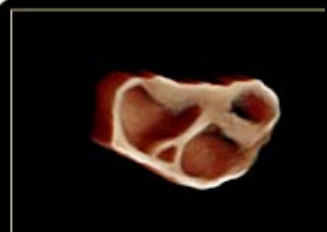Div  
SRI  
3D S

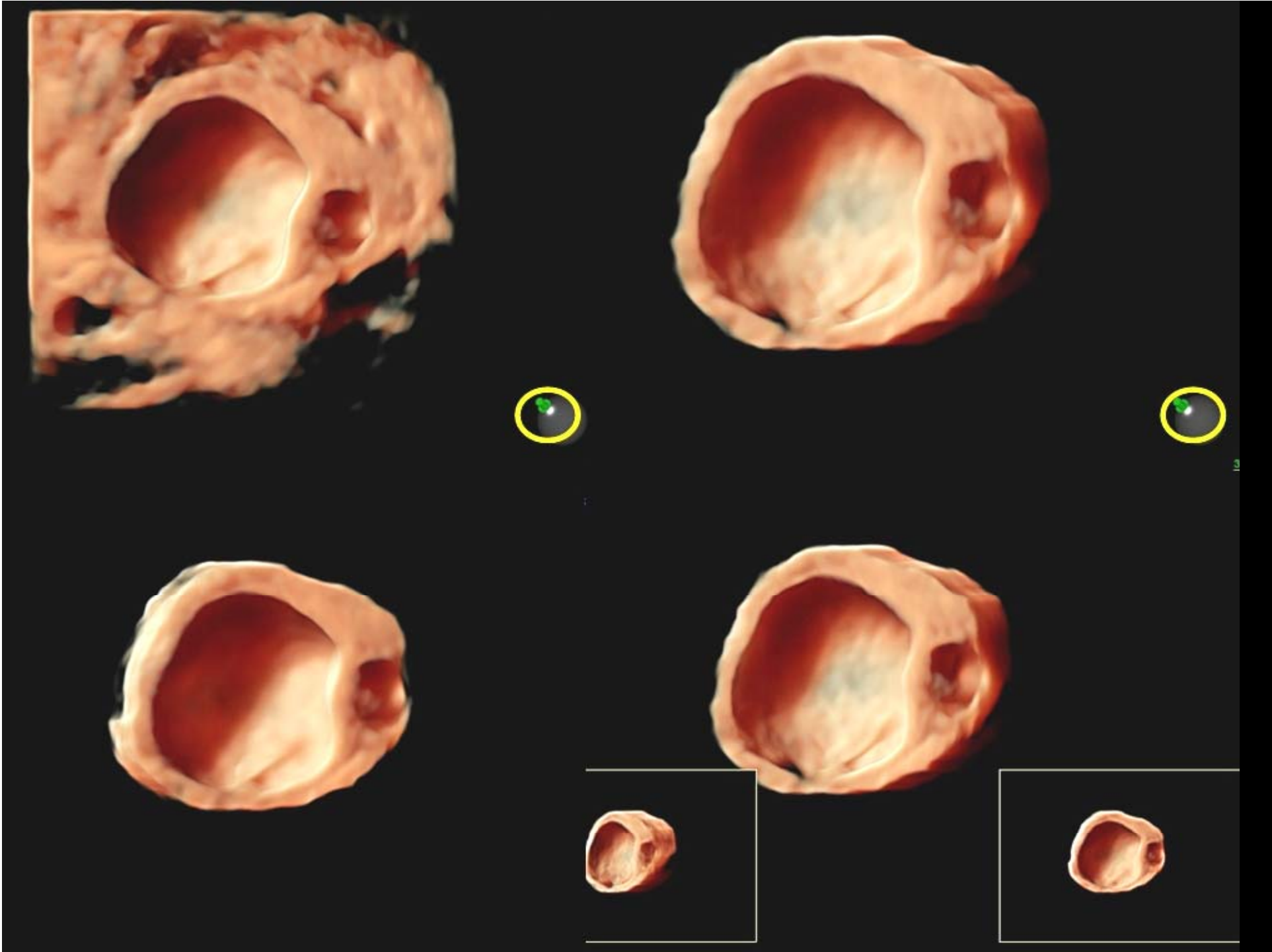


Div  
1  
3

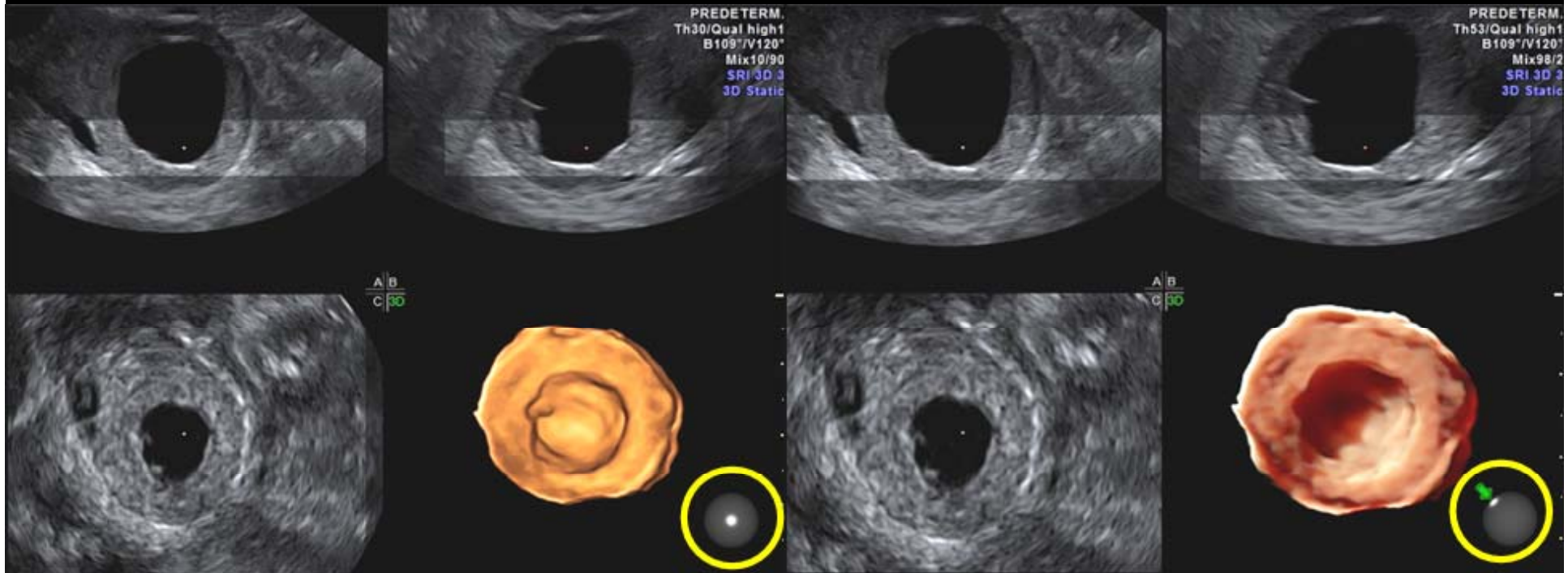


Div  
SRI  
3D S

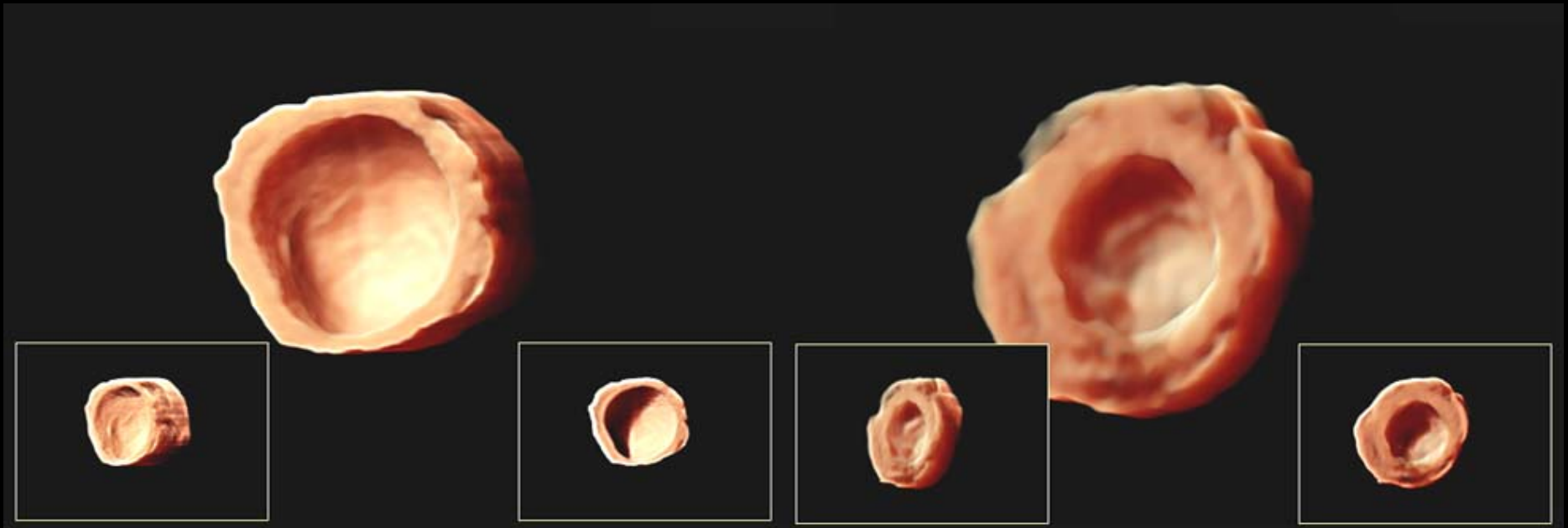



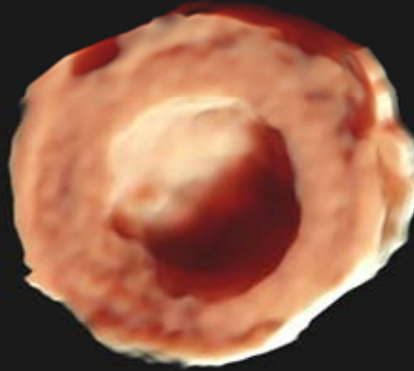
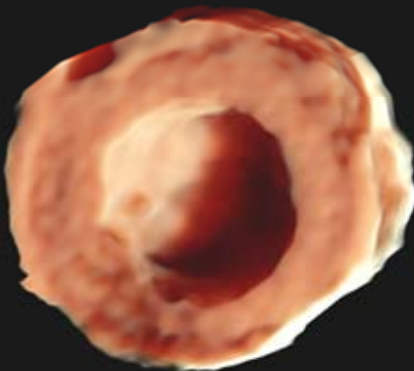
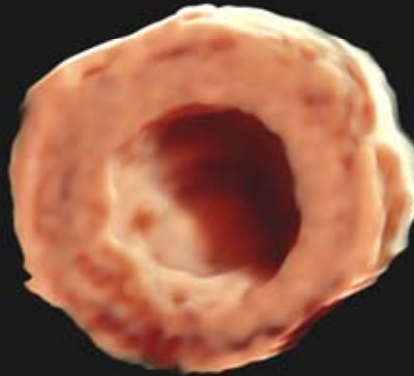
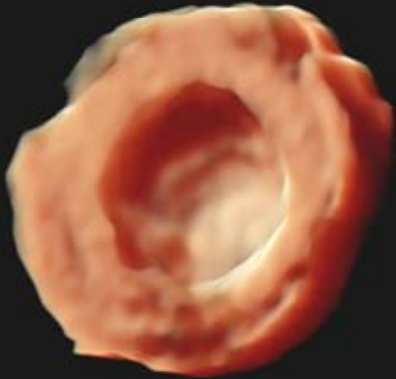
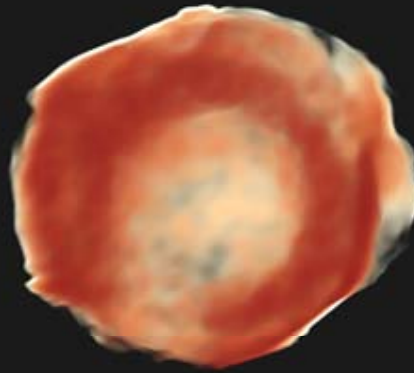
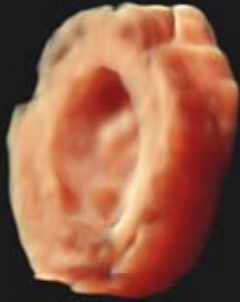
# CUERPO LÚTEO



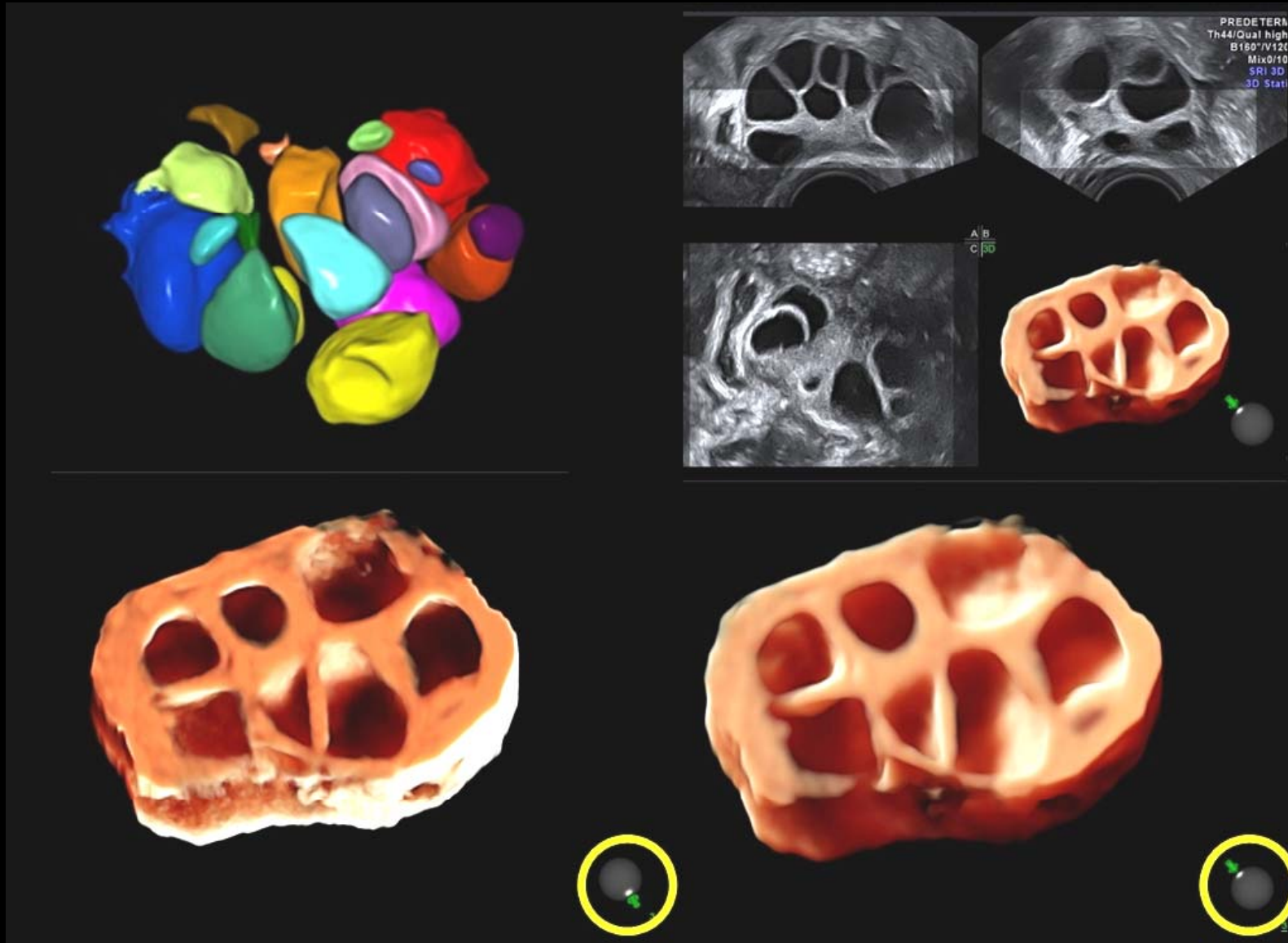
# FOLÍCULO/CUERPO LÚTEO

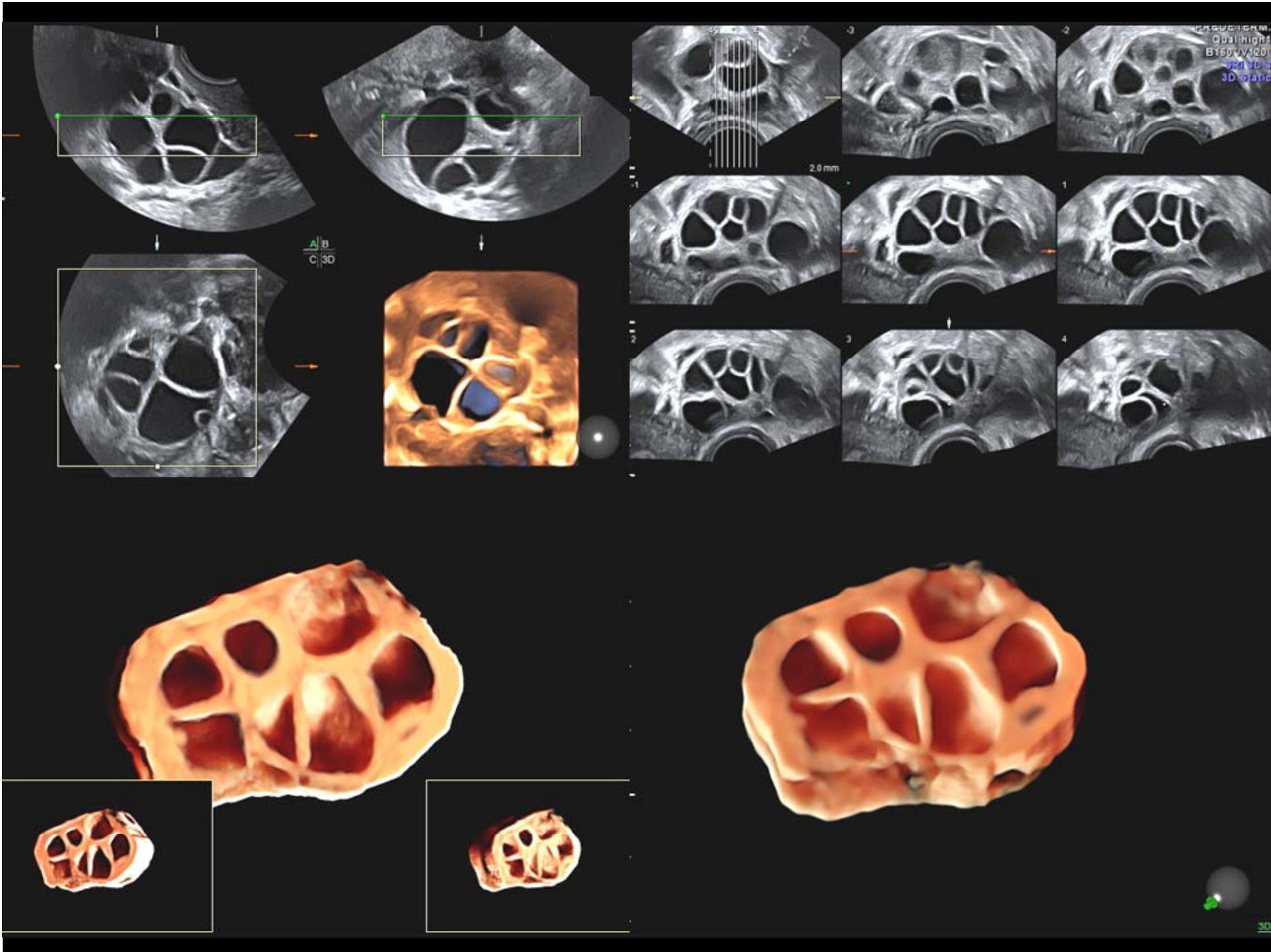


# CUERPO LÚTEO



# INDUCCIÓN OVULACIÓN

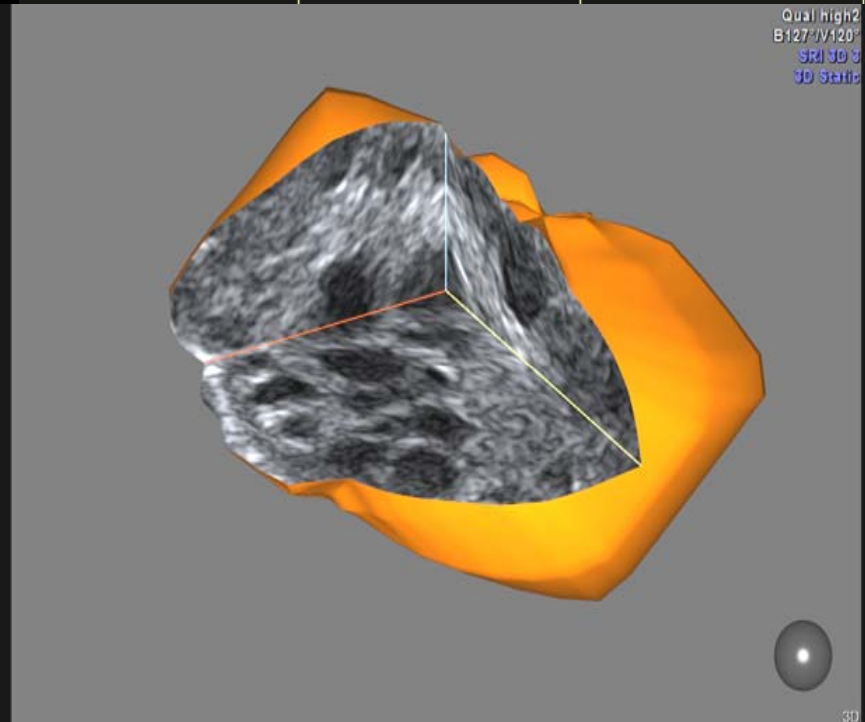
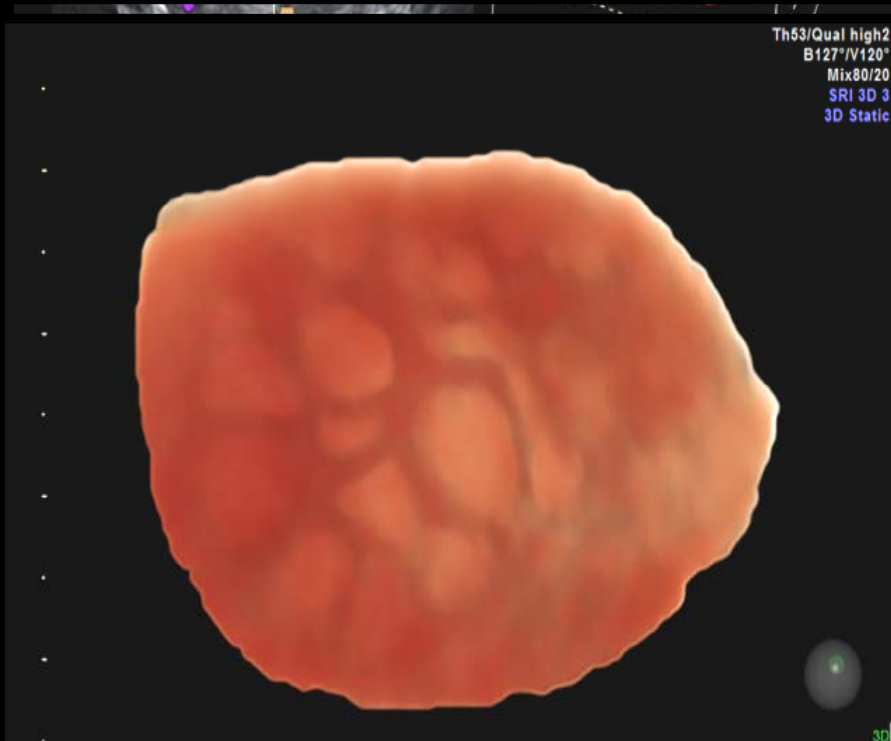
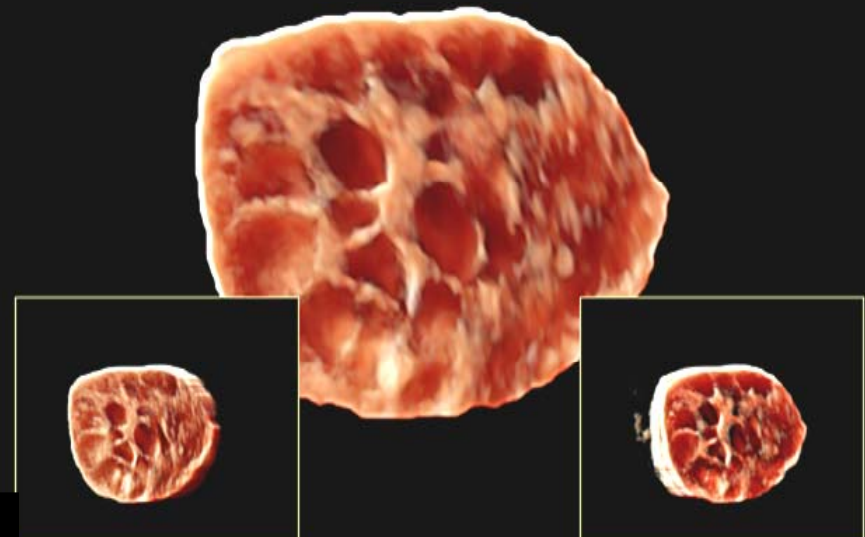
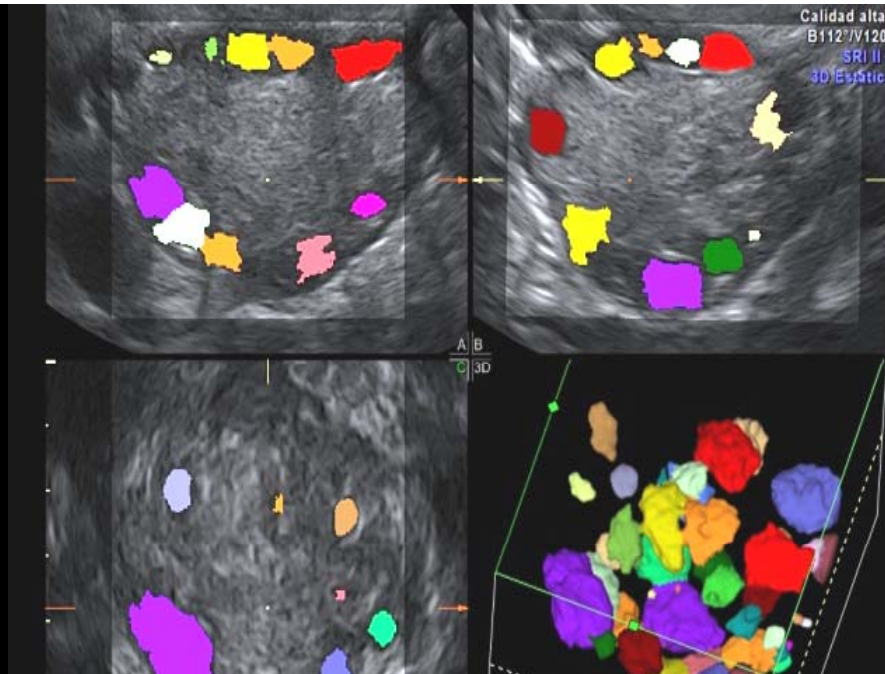




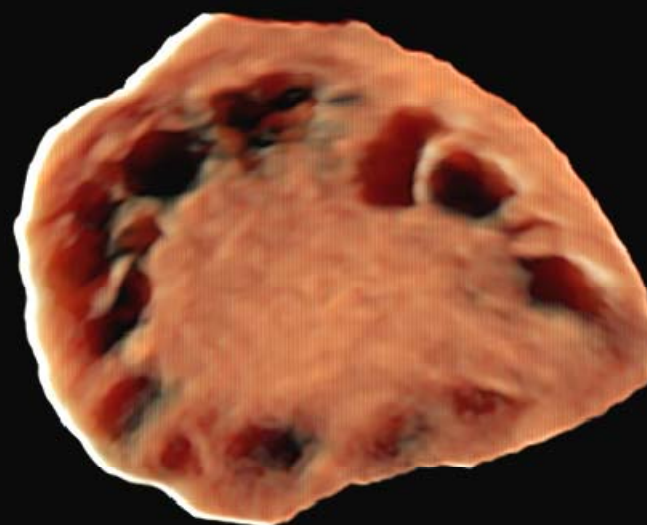
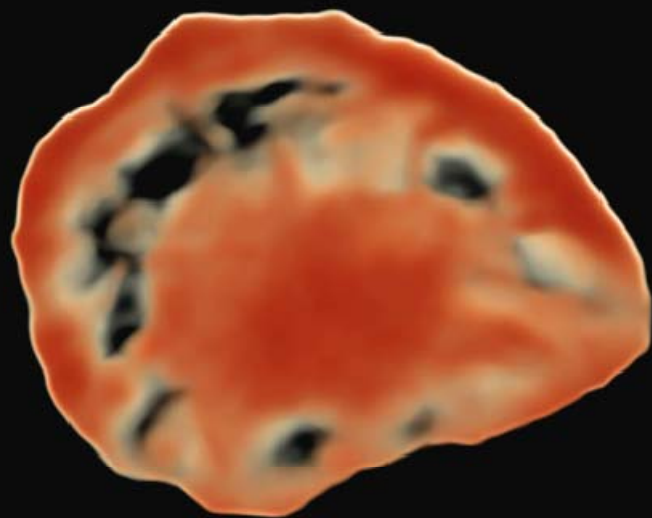

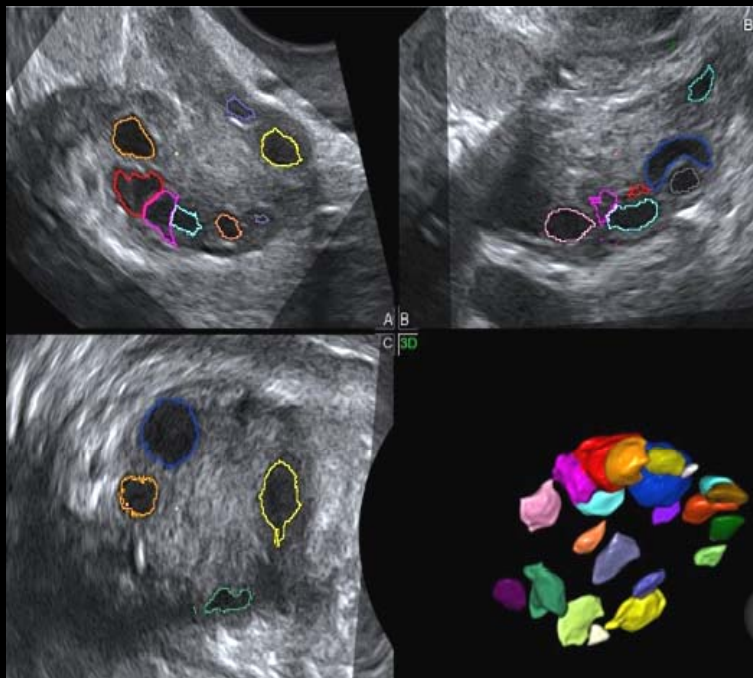


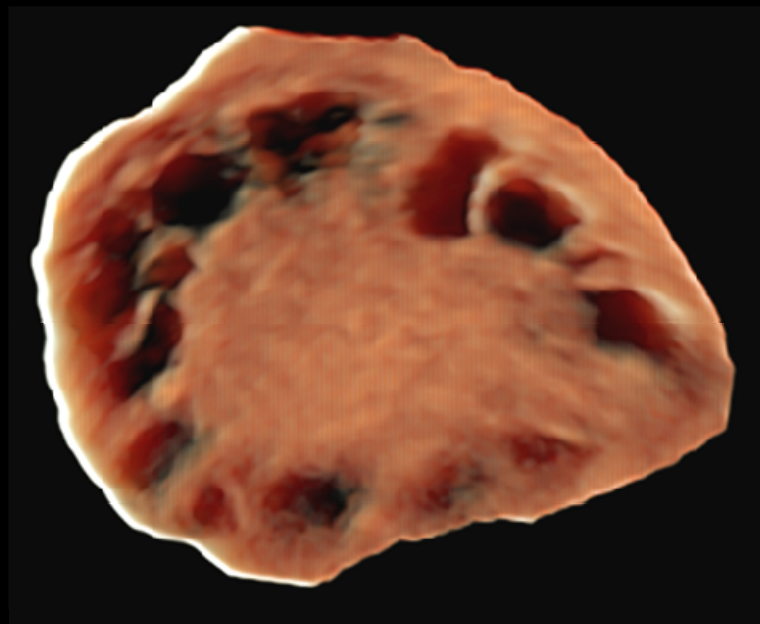
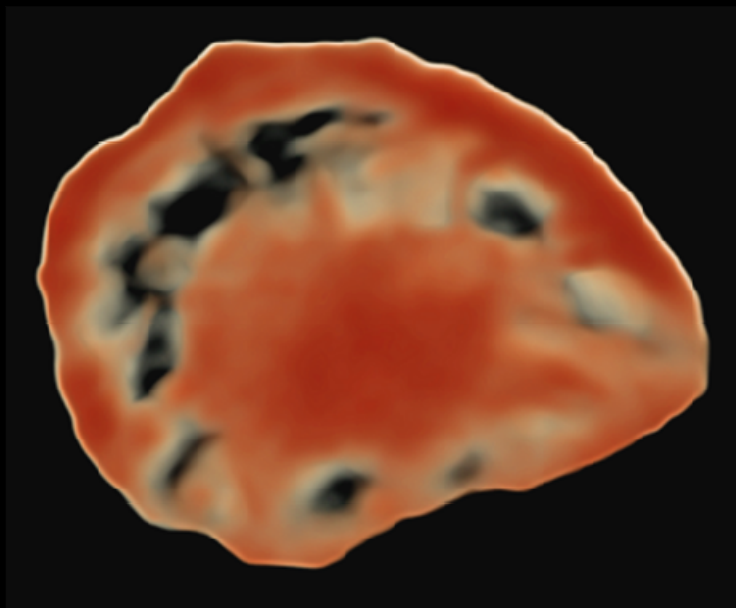
# HIPERESTIMULACIÓN

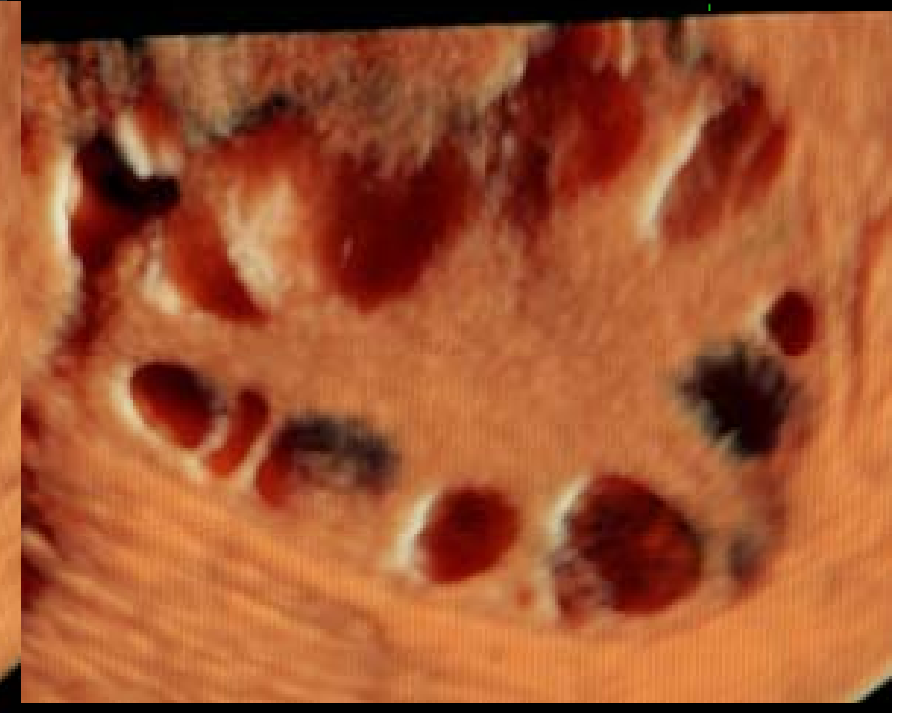
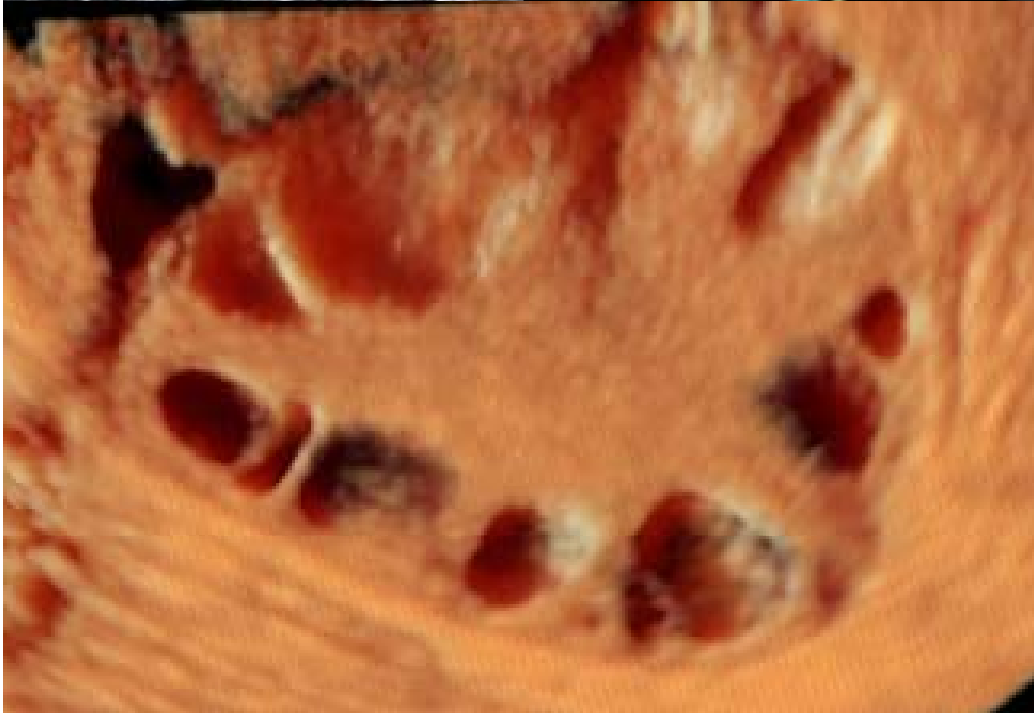
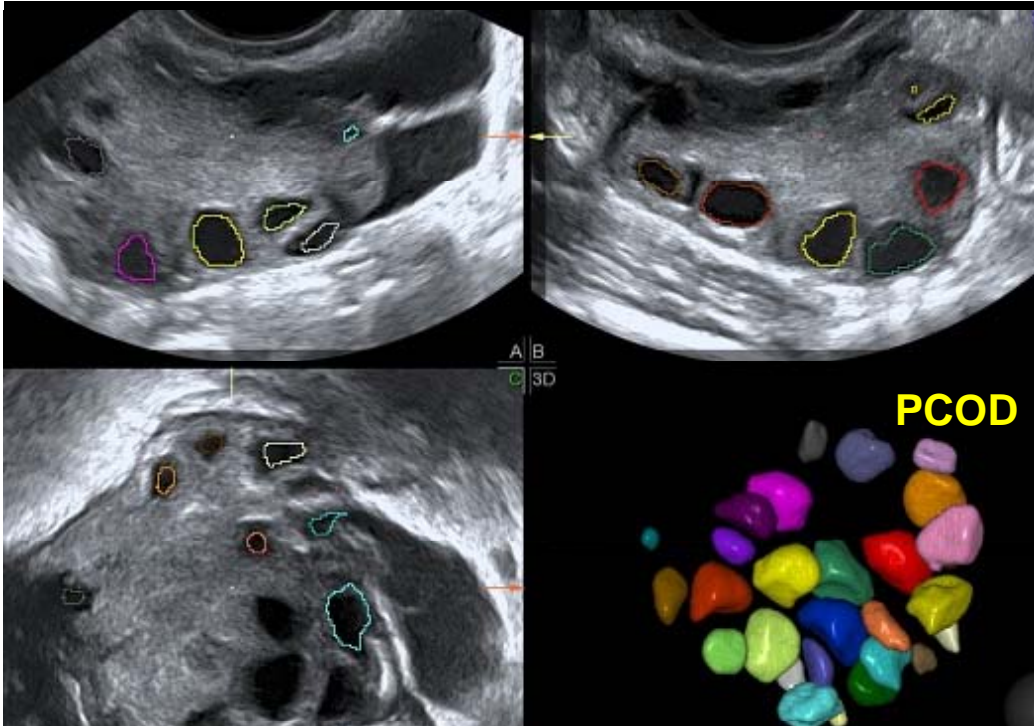
Qual high2  
B127°/V120°  
SRI 3D 3  
3D Static

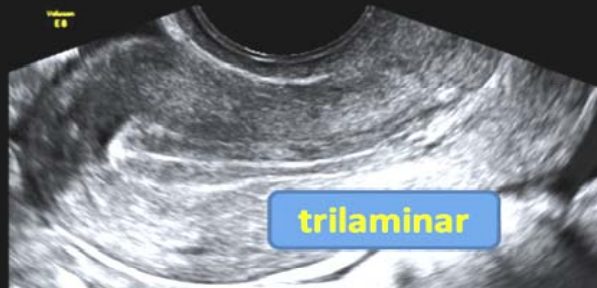

# PCOD

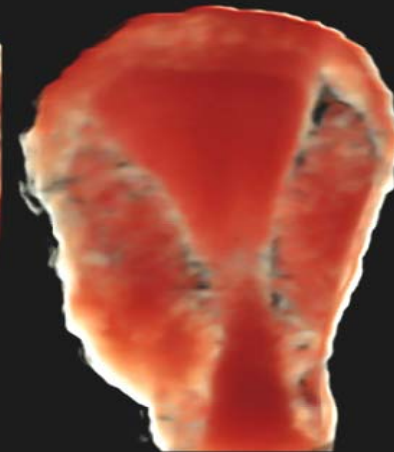
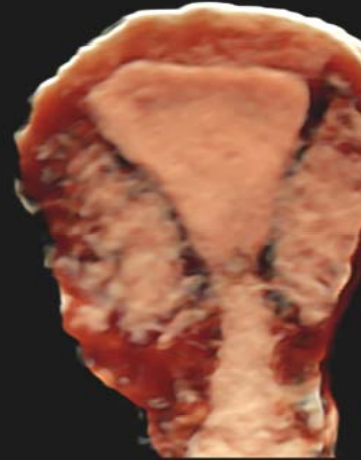
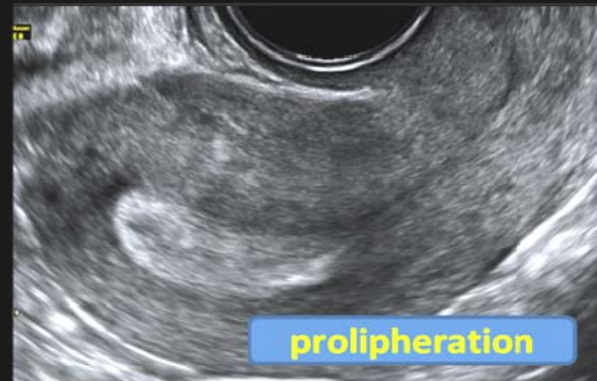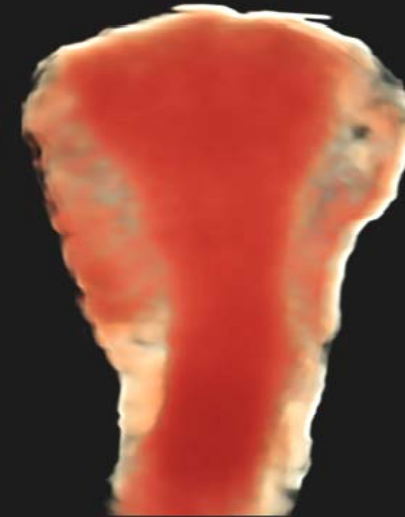

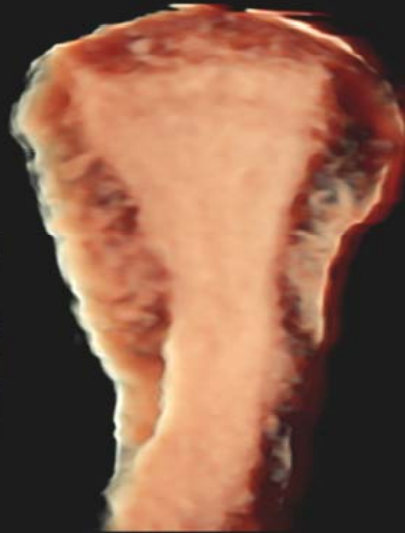


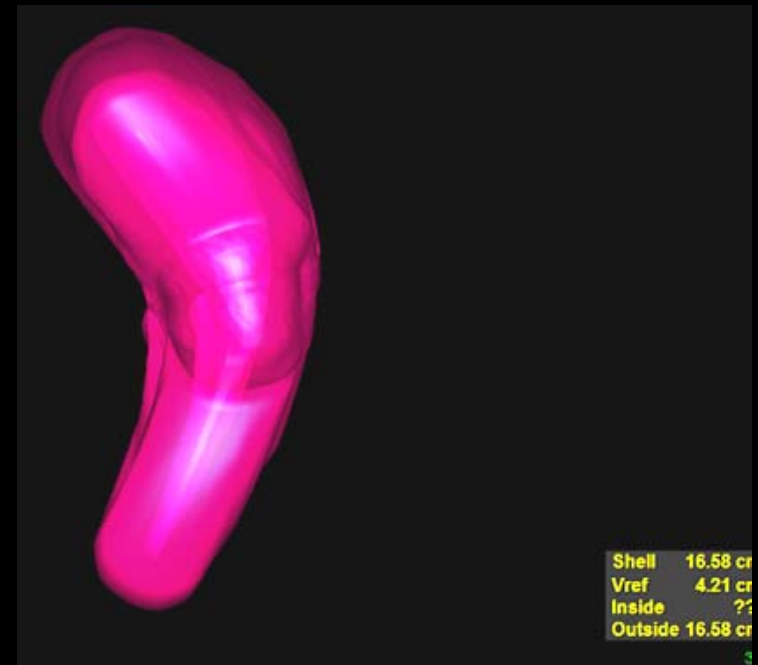
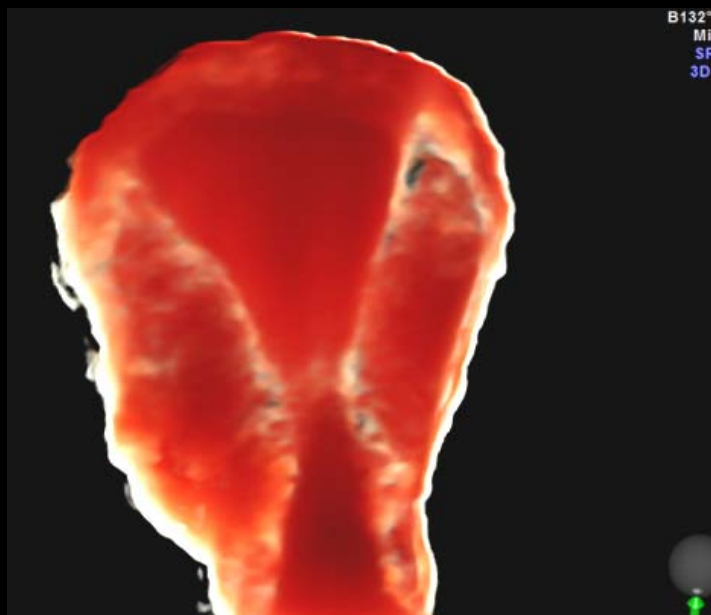
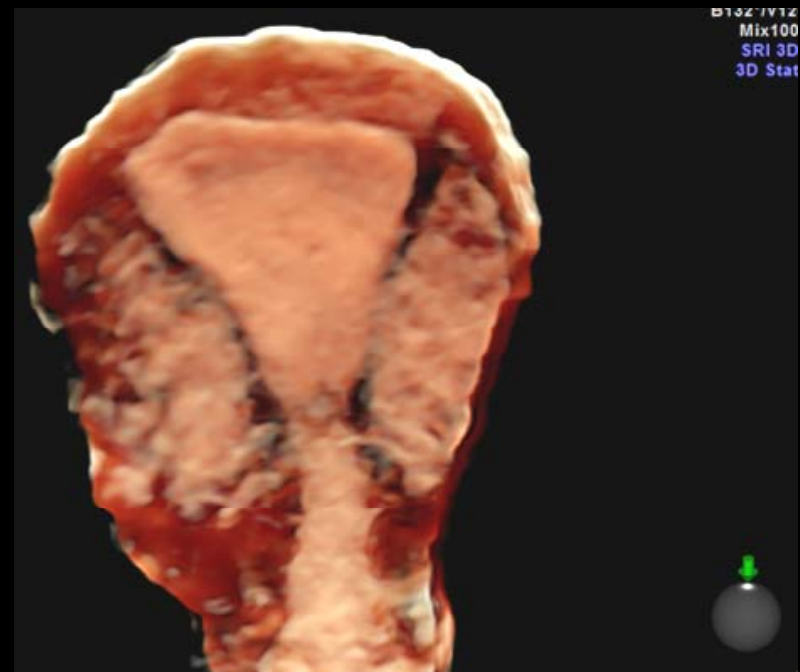
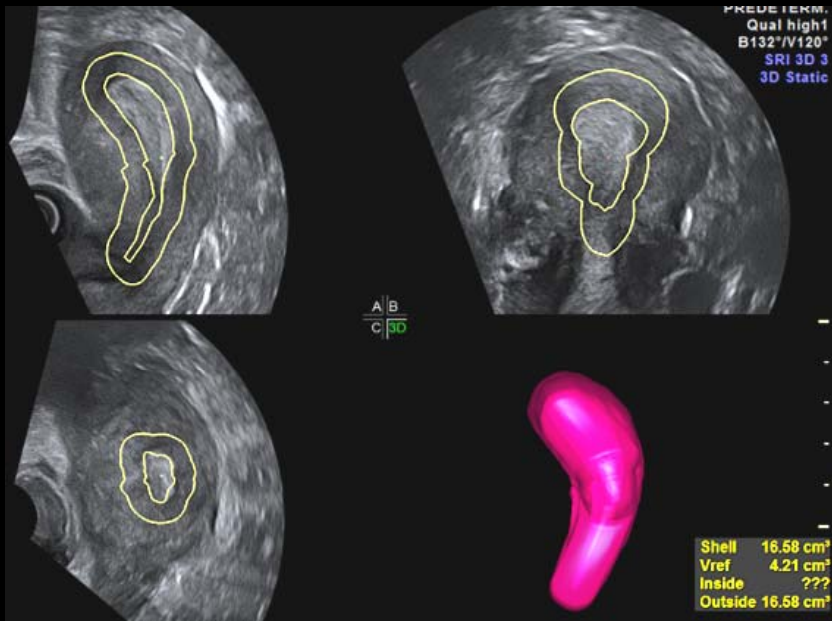




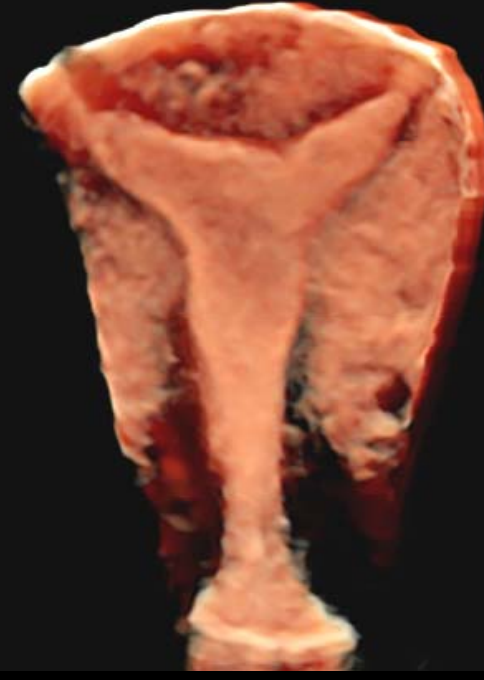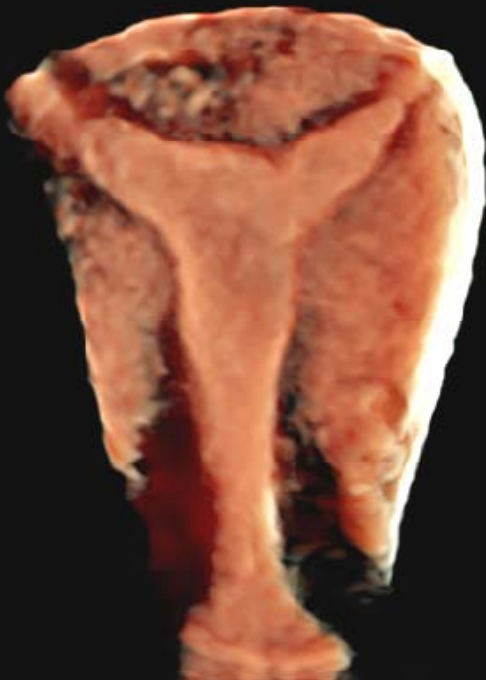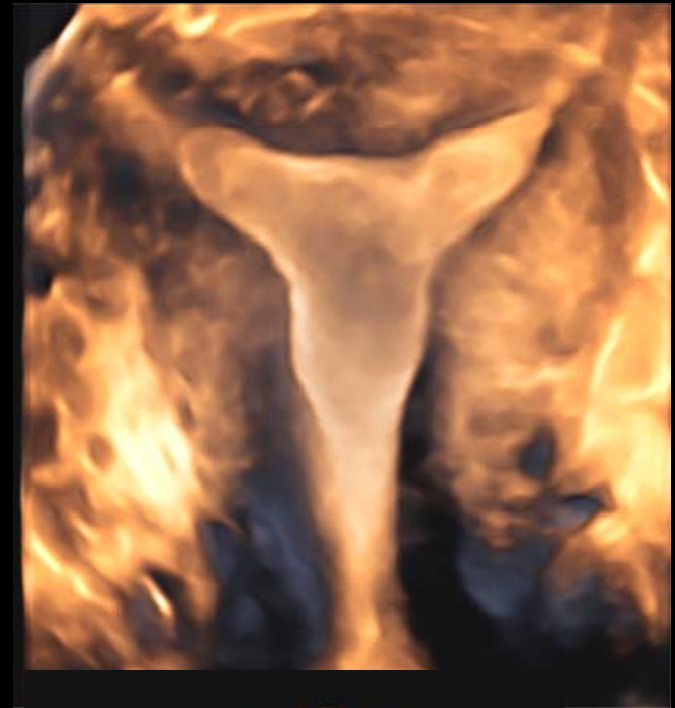
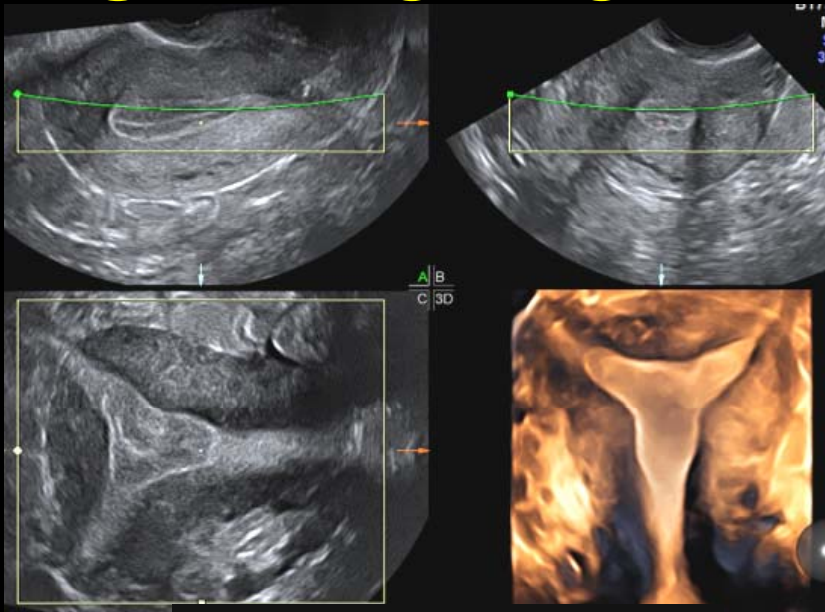
**ENDOMETRIAL E  
MORPHOLOGIE**

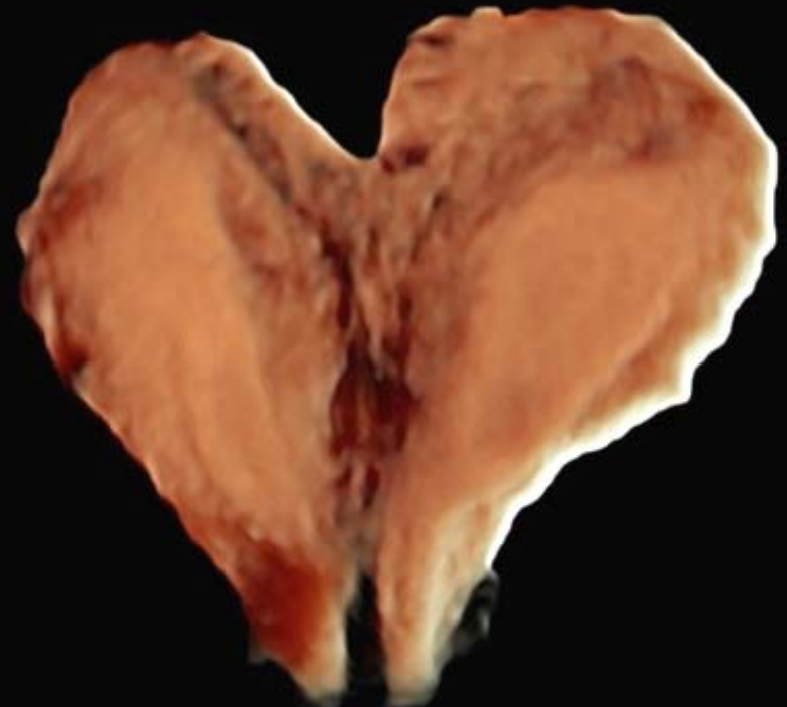
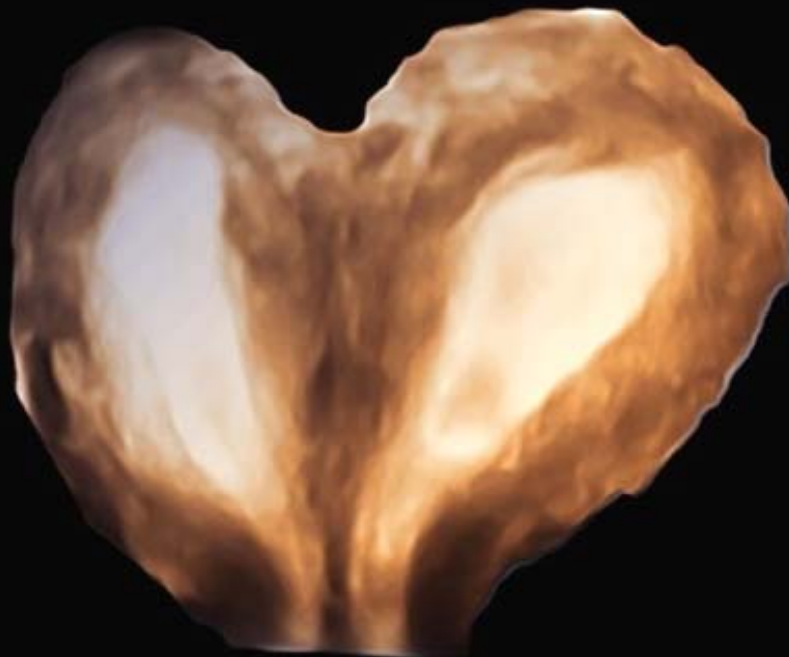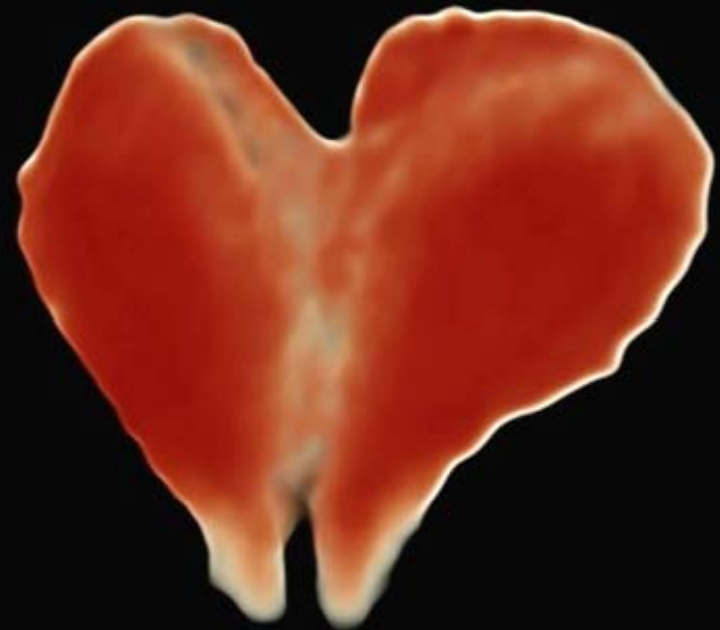
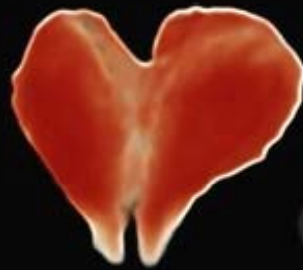
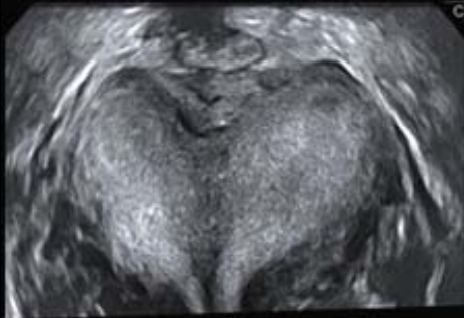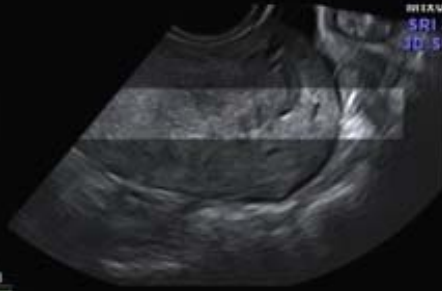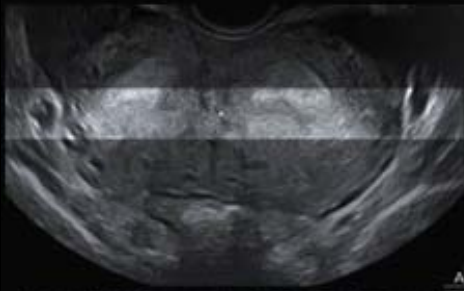


# ENDOMETRIUM



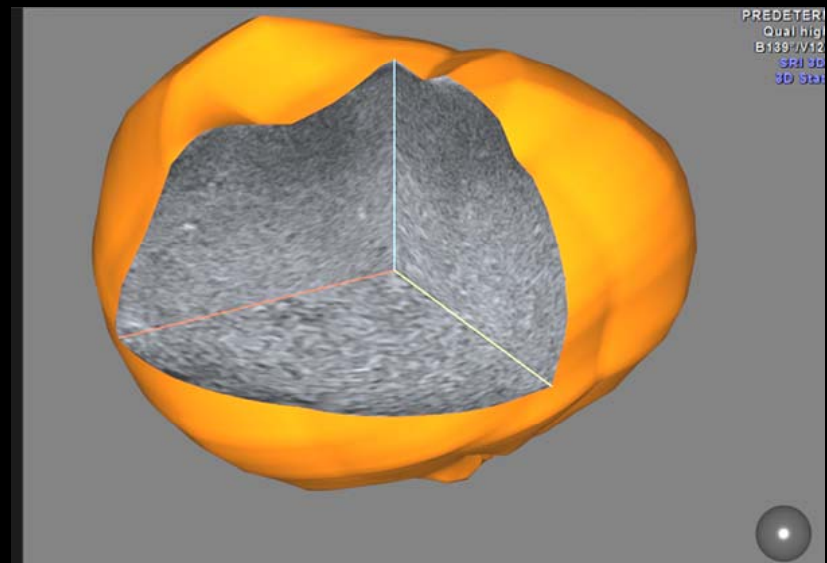
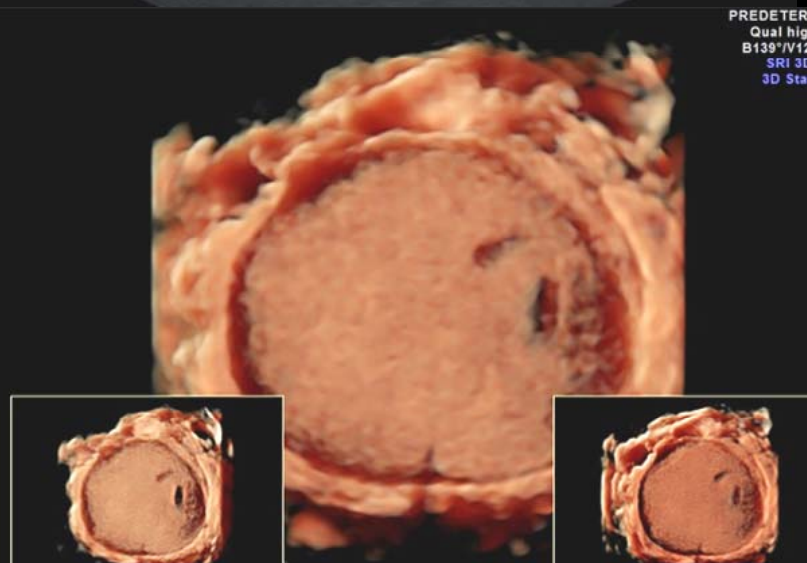
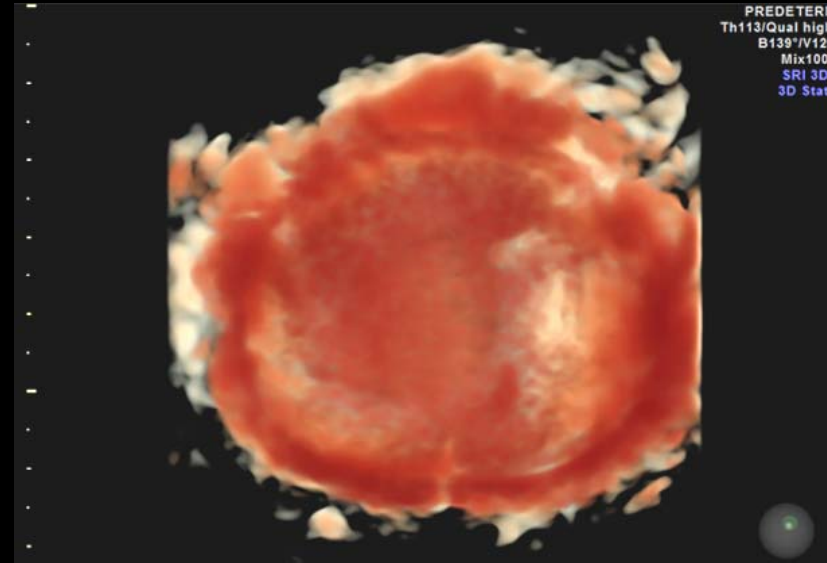
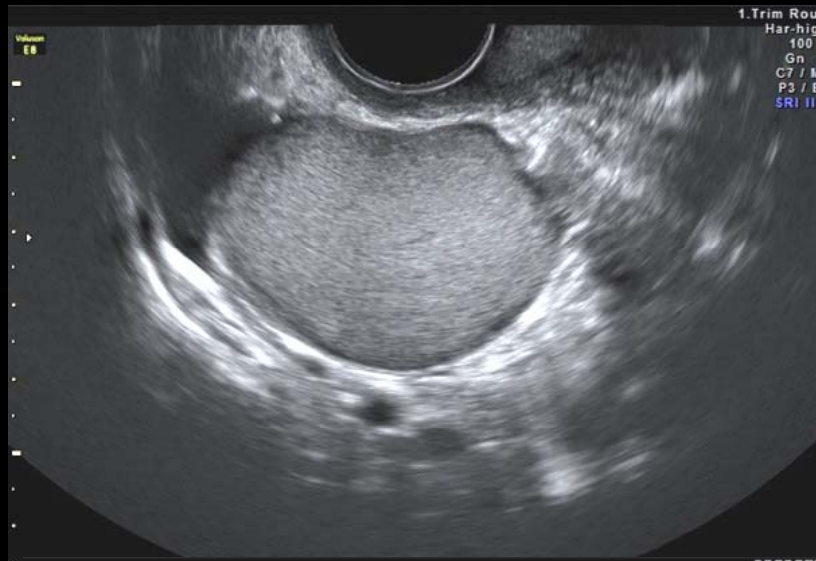
# ÚTERO NORMAL

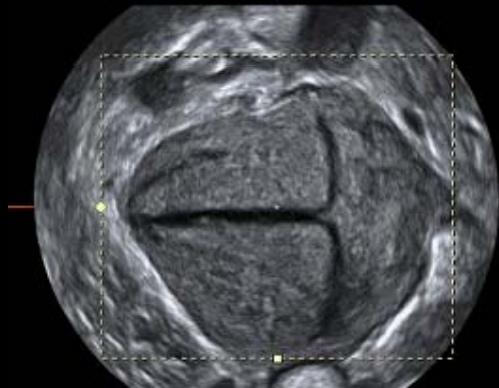
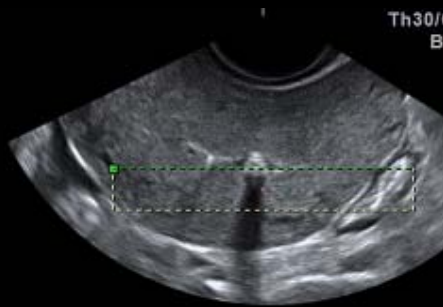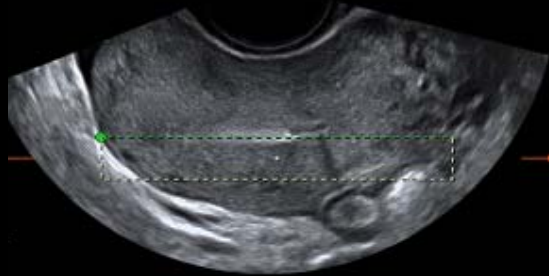
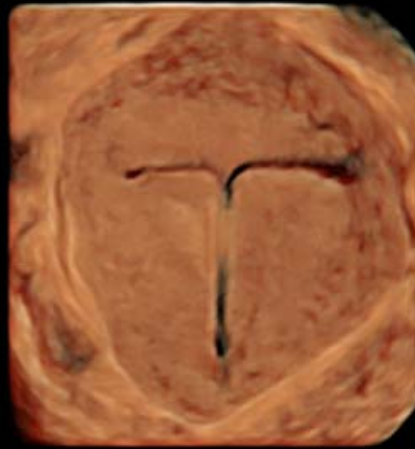
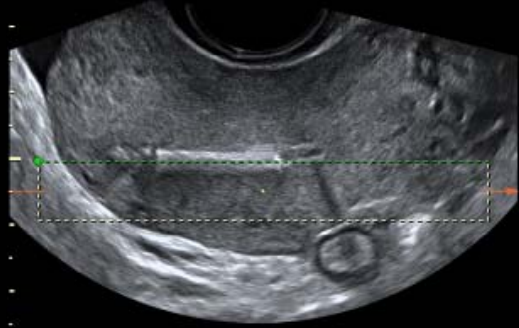




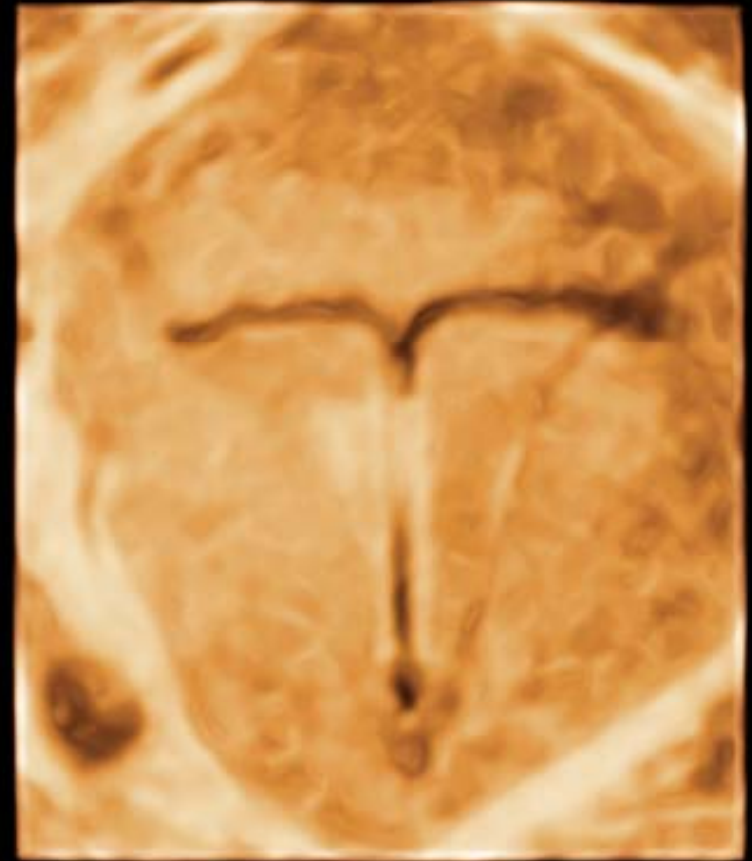
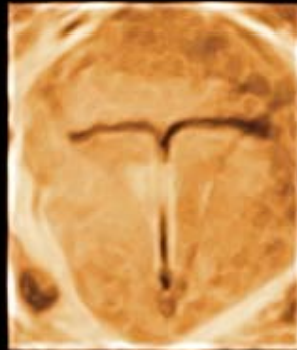


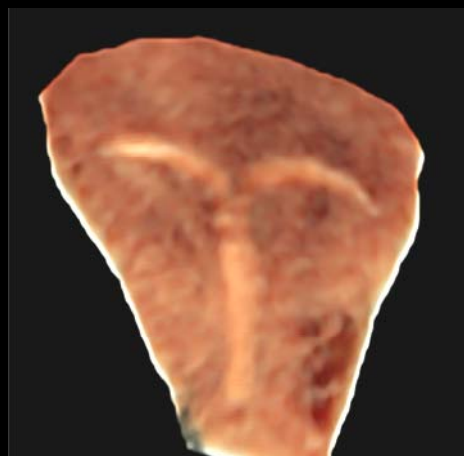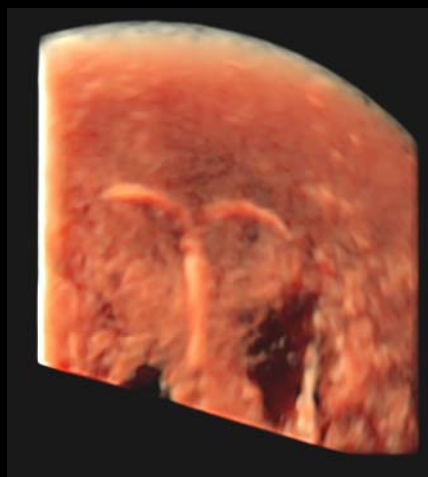
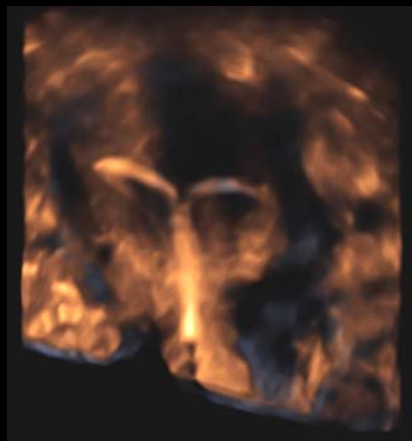
# ENDOMETRIOSIS

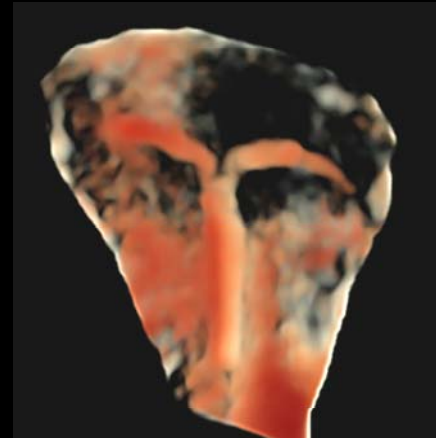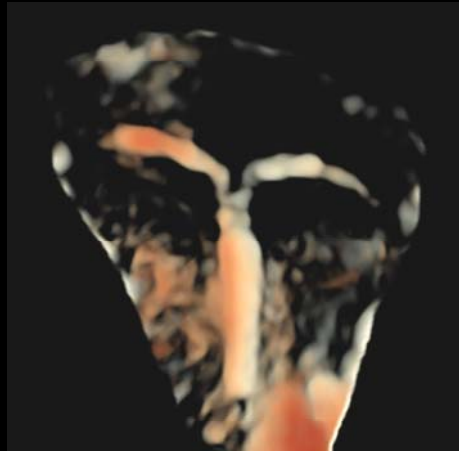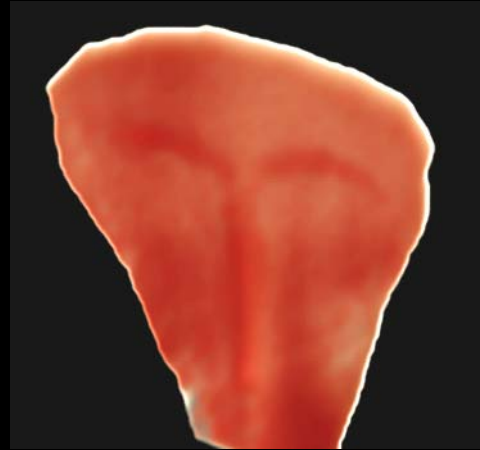
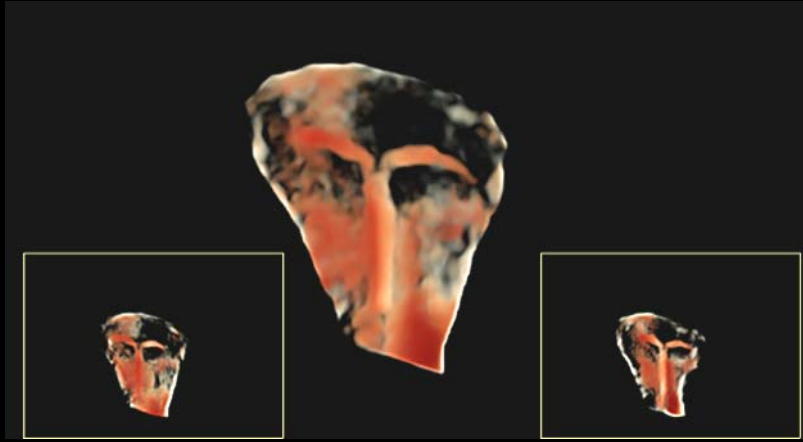


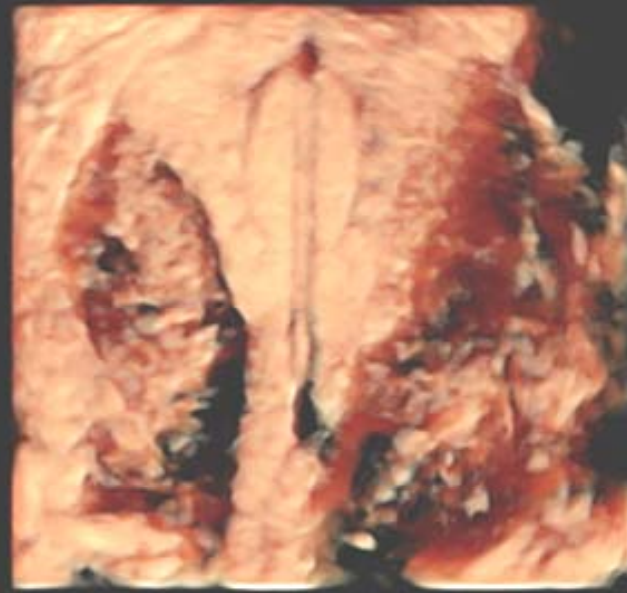
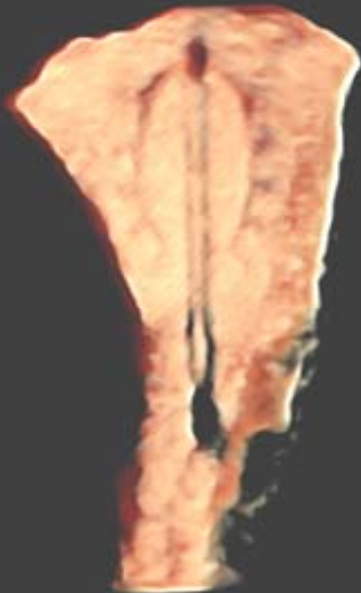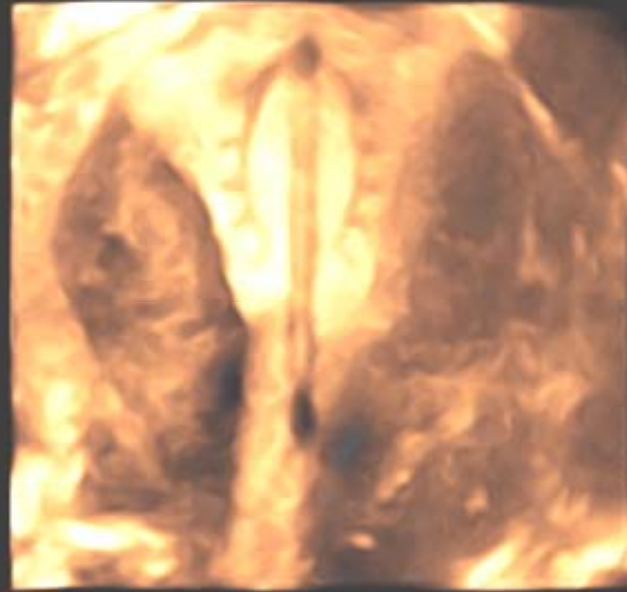
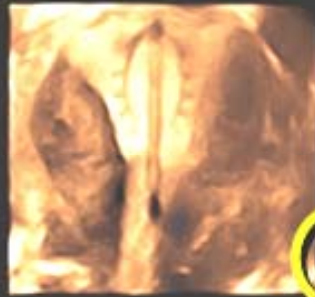
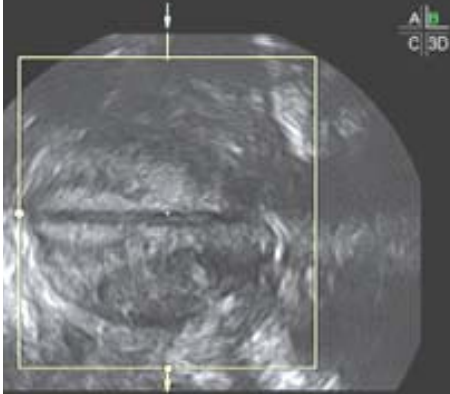
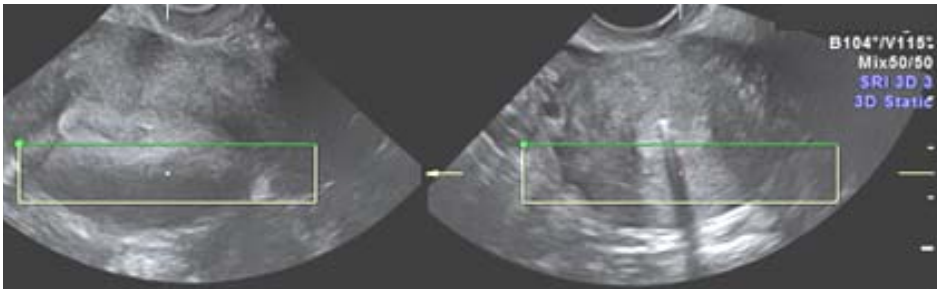


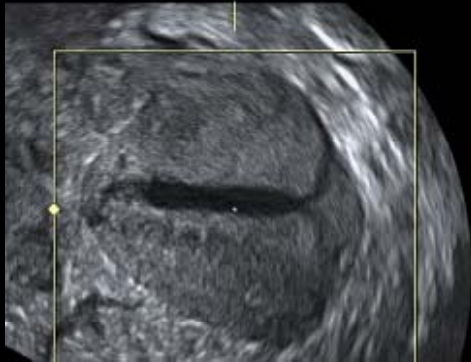
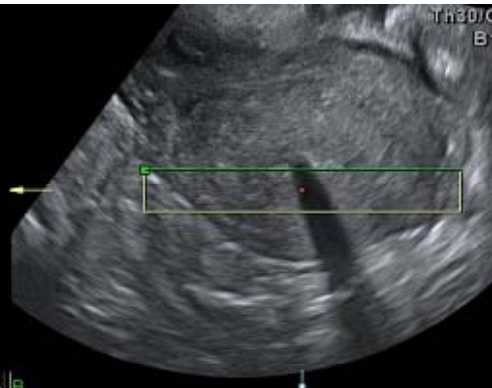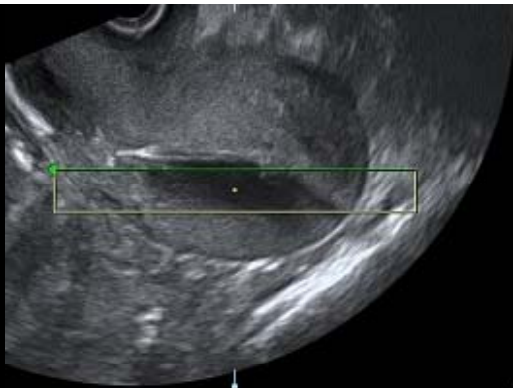A | B  
C | 3D



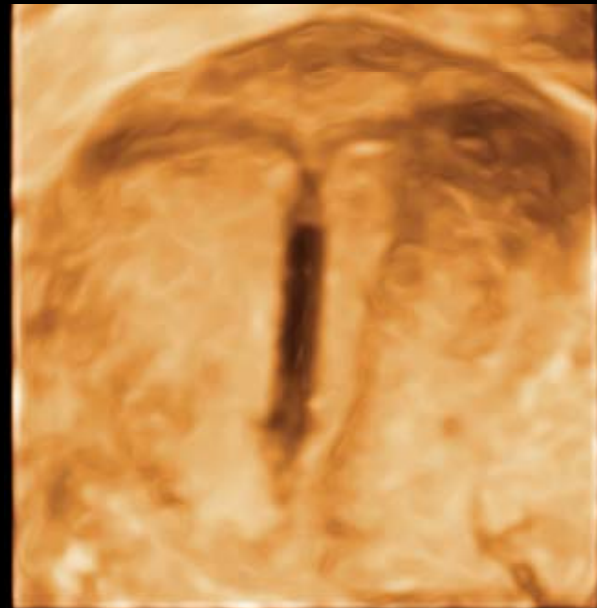
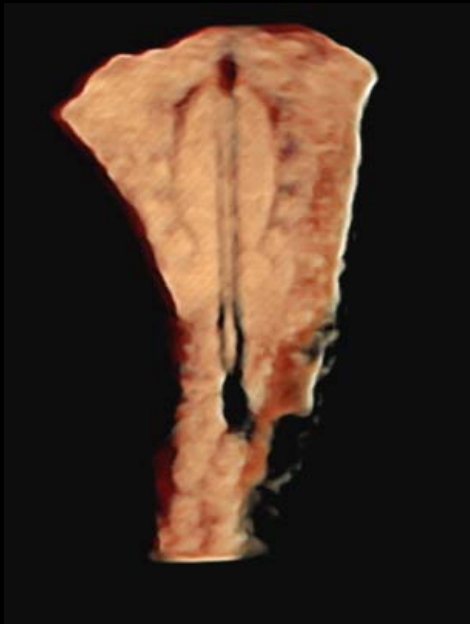
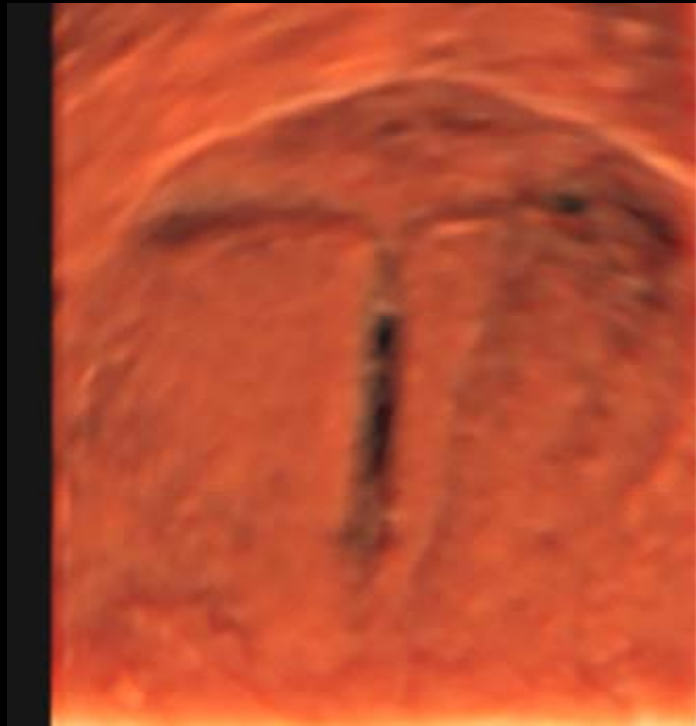
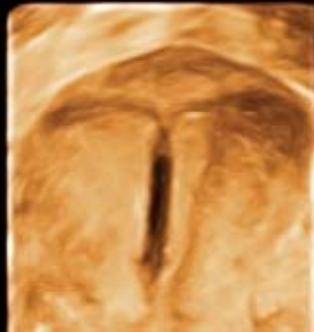

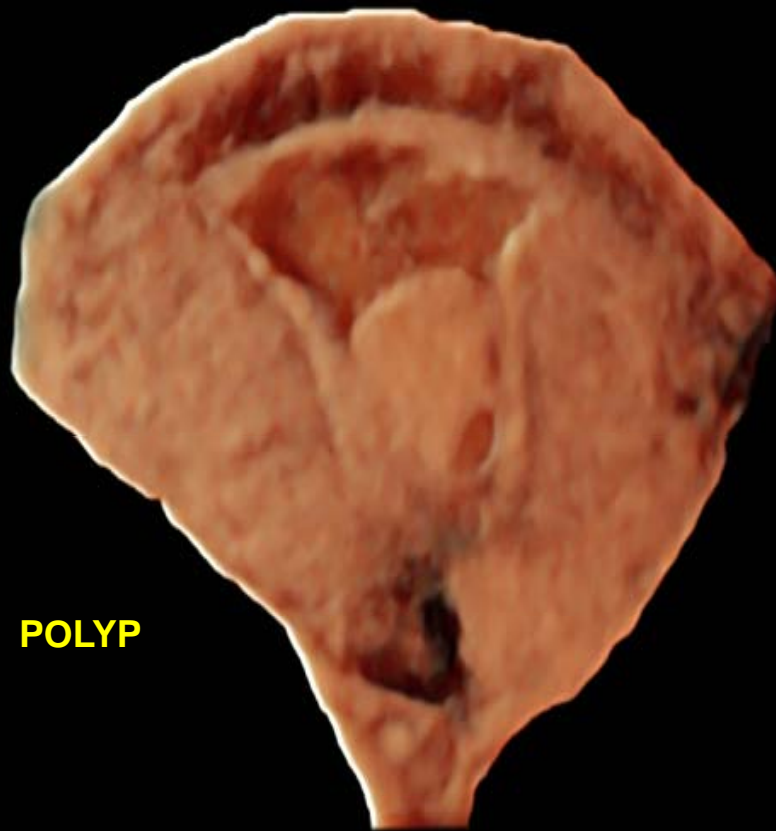






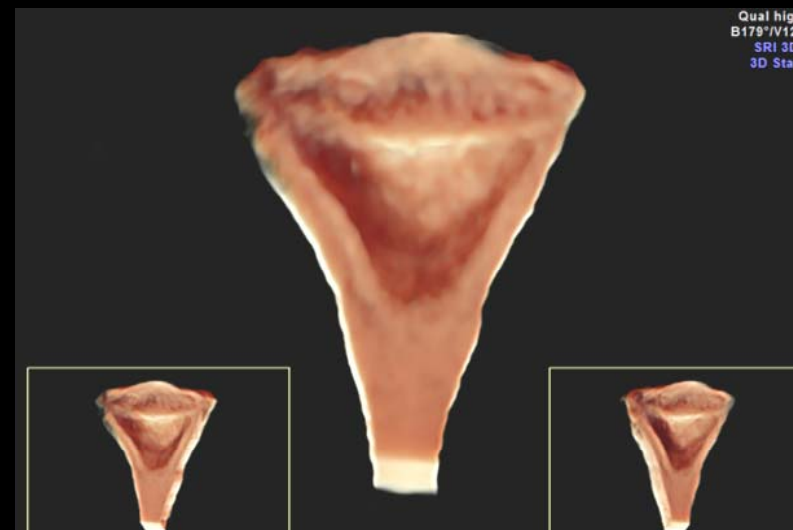
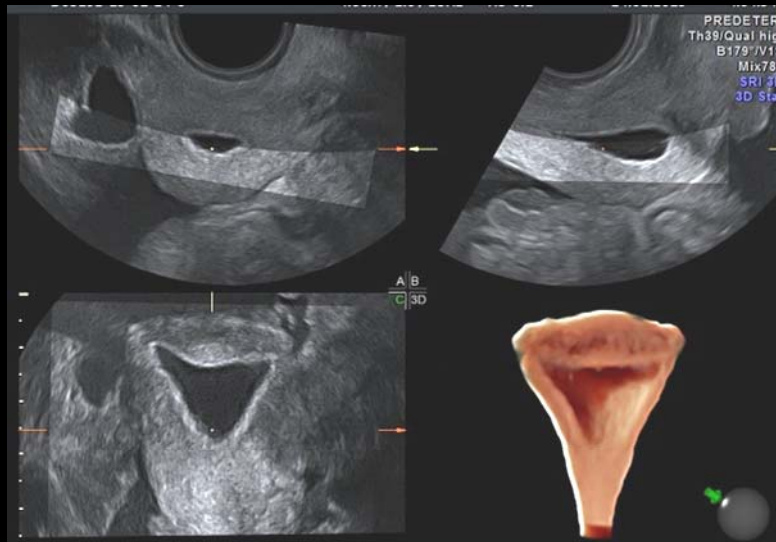
A | B  
C | 3D





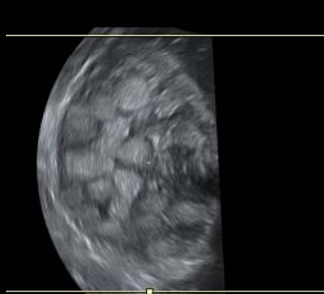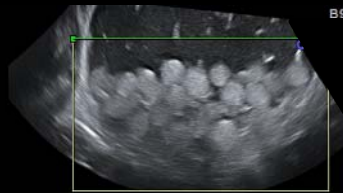
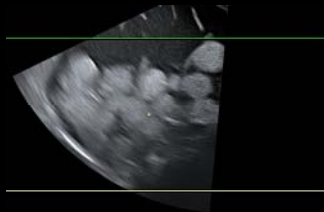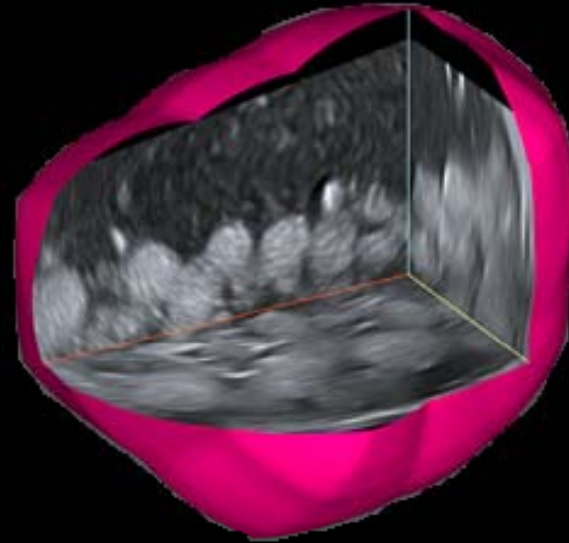
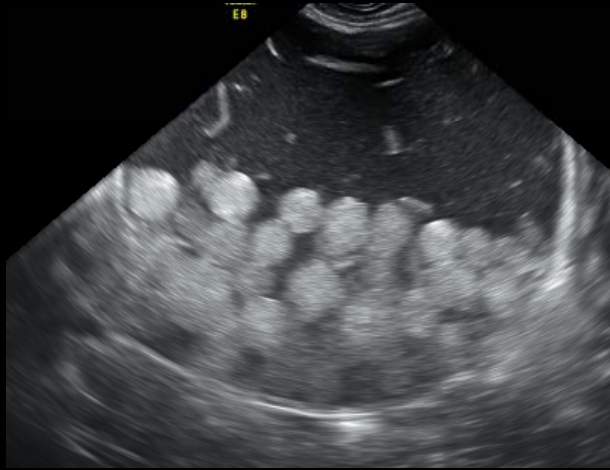
**POLYP**

# MUCOMETRA

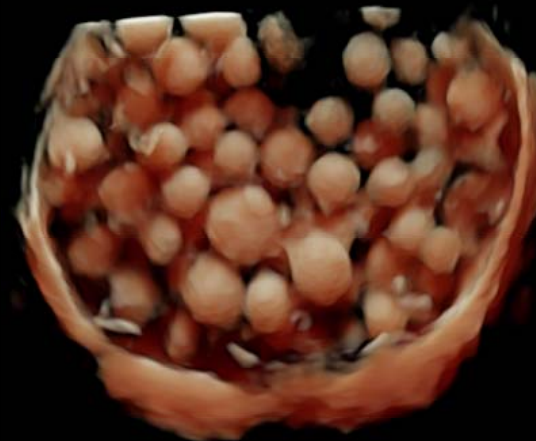
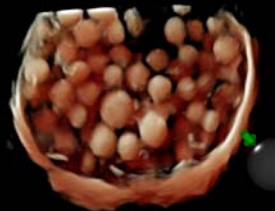




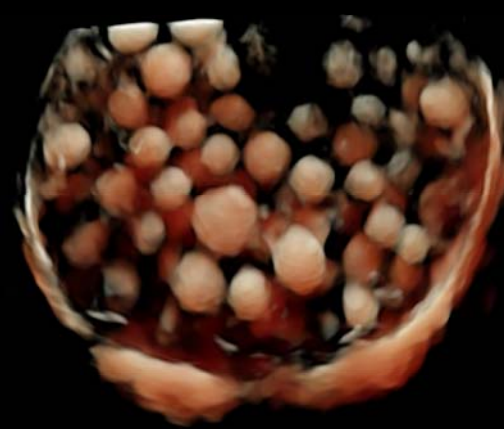
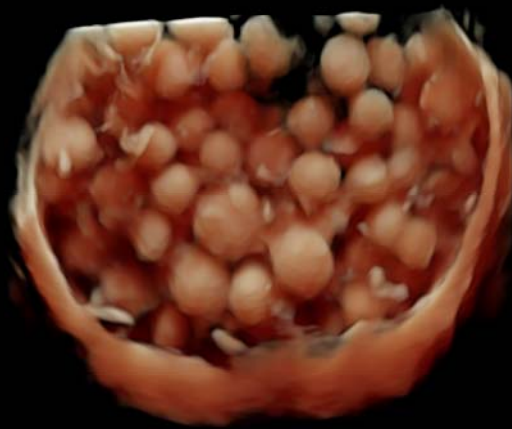
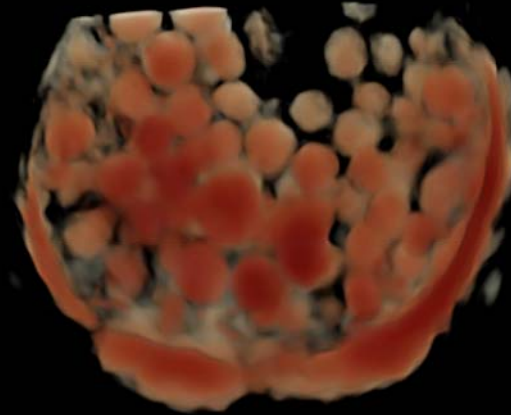
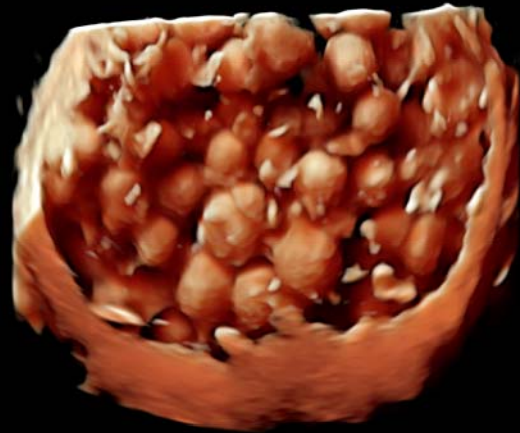
# DERMOID

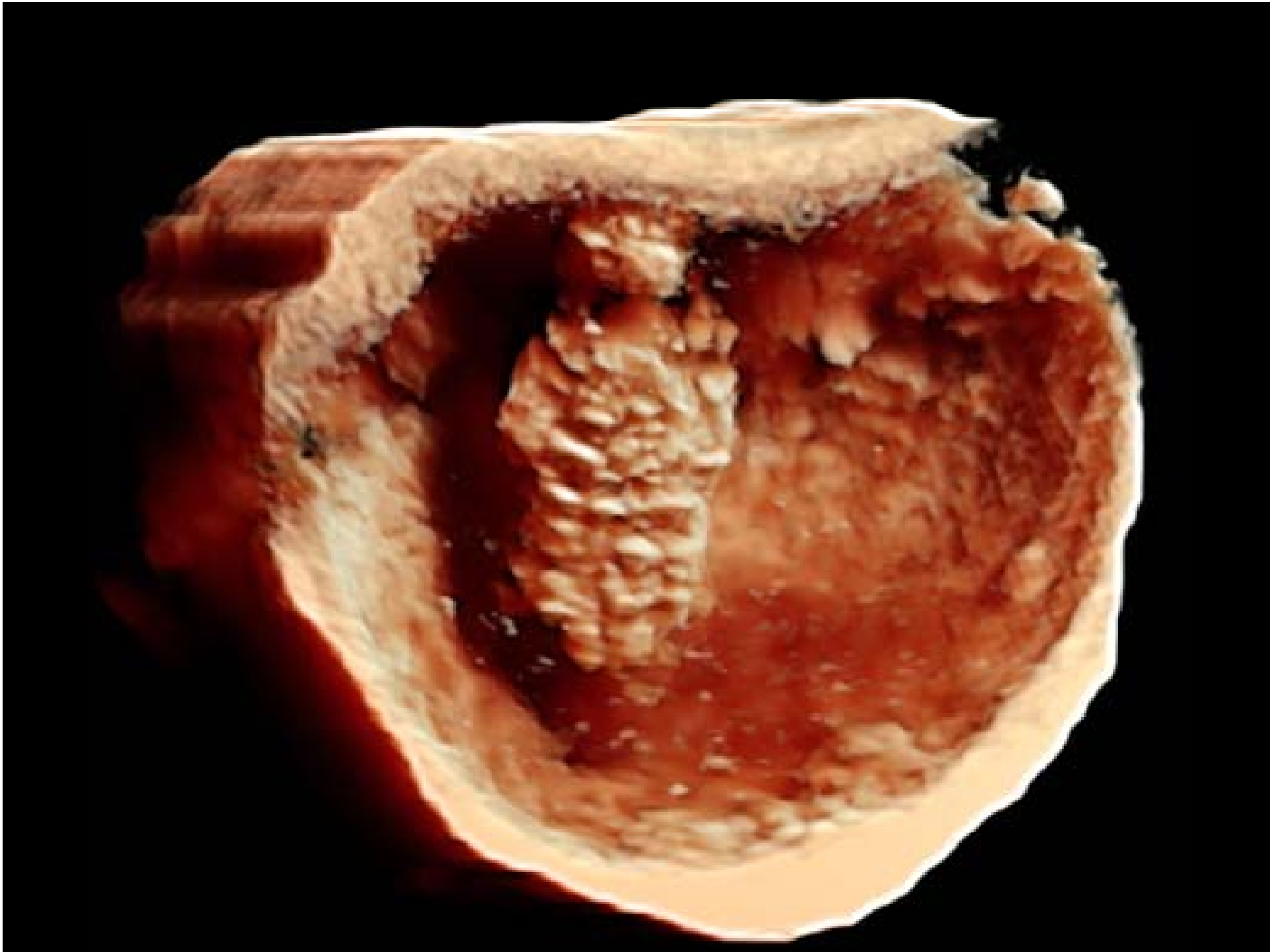


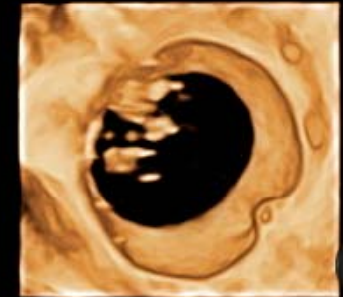
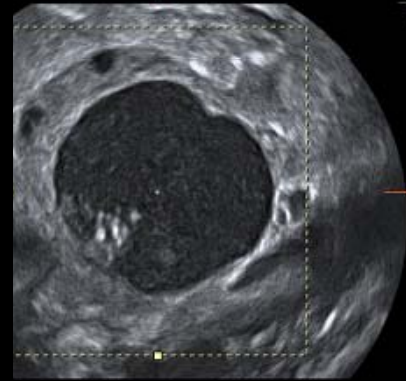
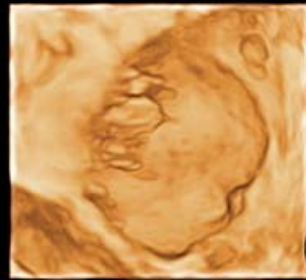
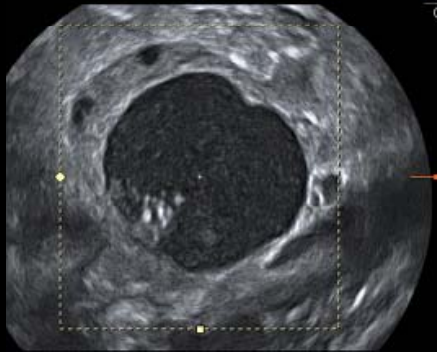
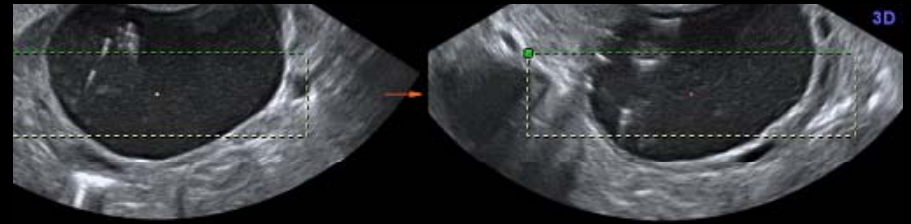
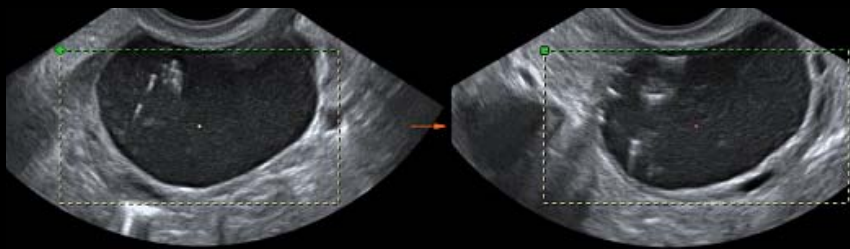
A/B  
C/D



# DERMOID

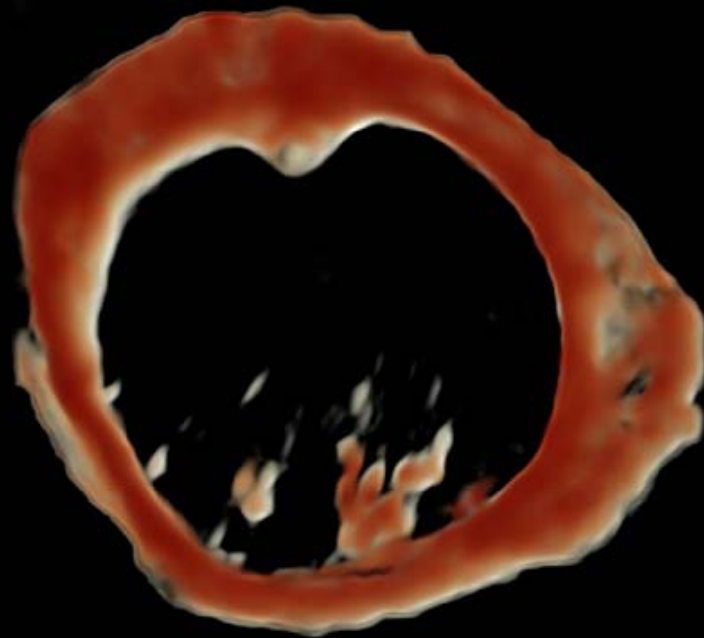
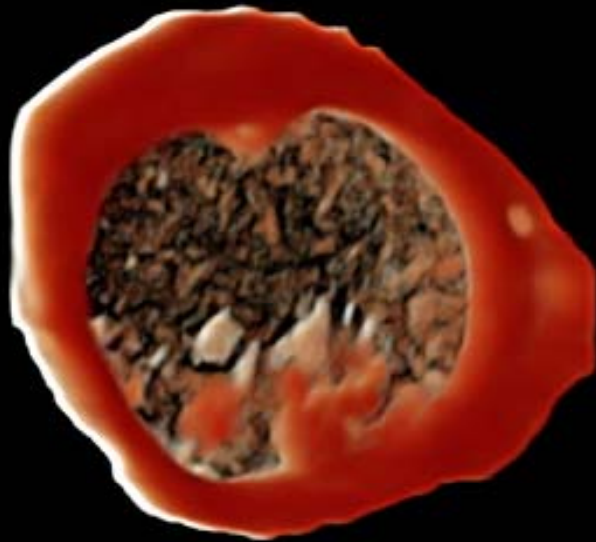


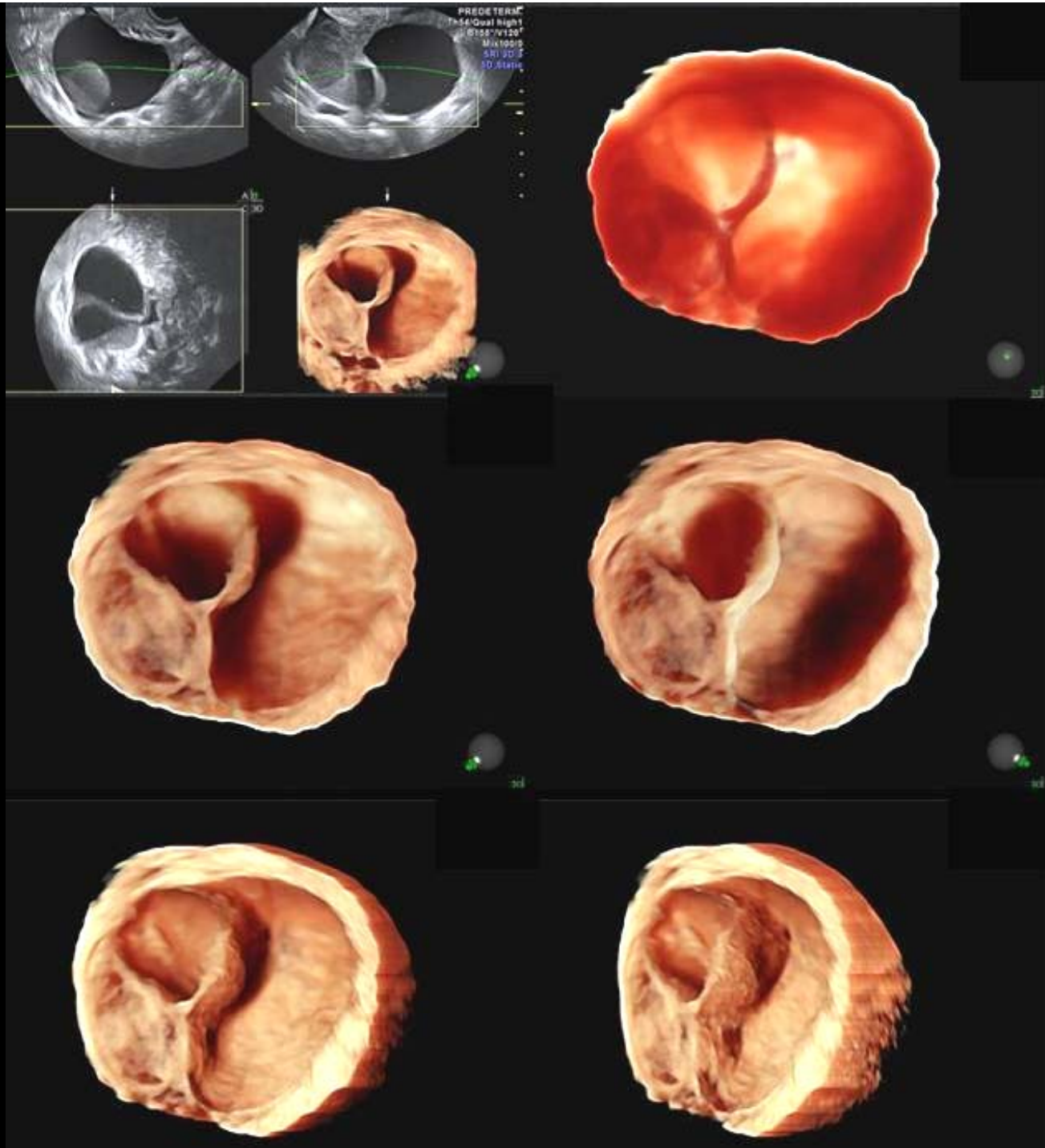




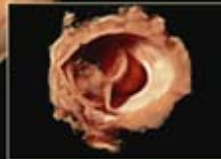
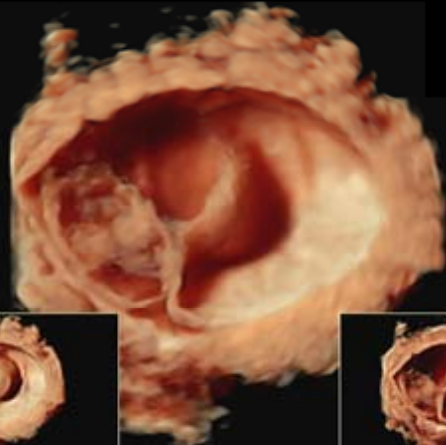
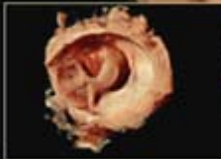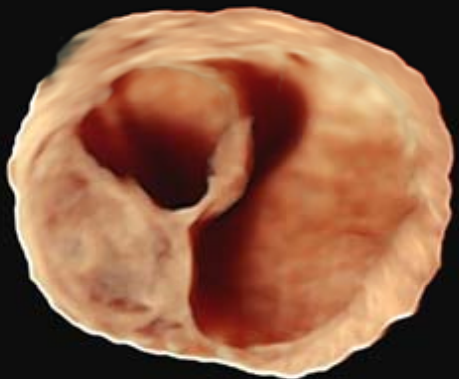
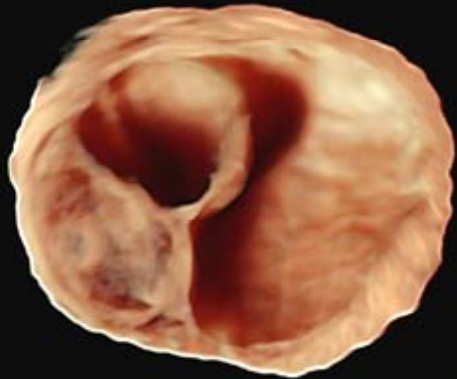
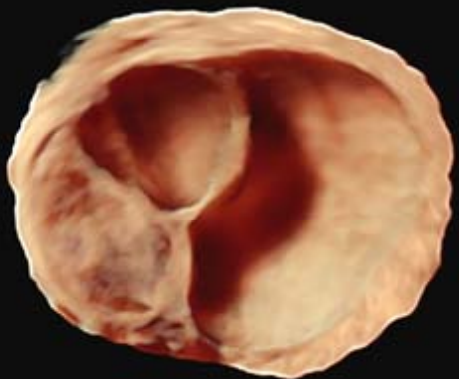
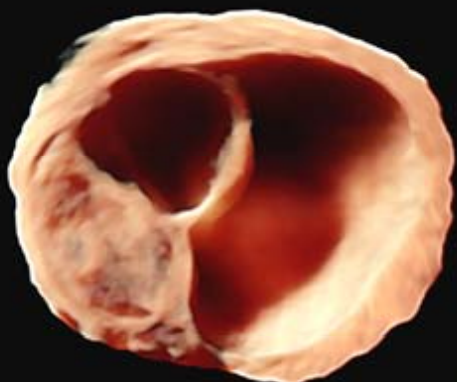
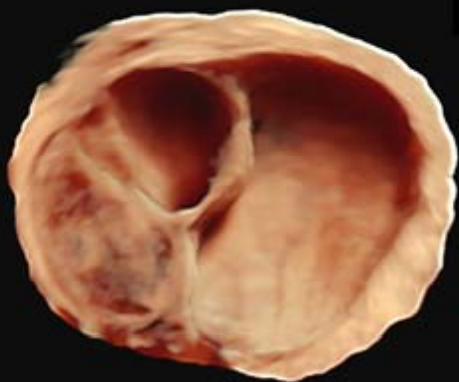
3D St:

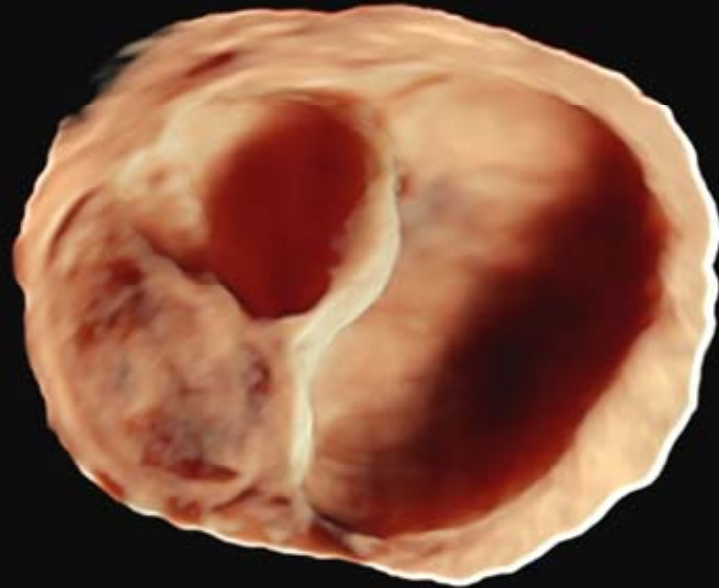
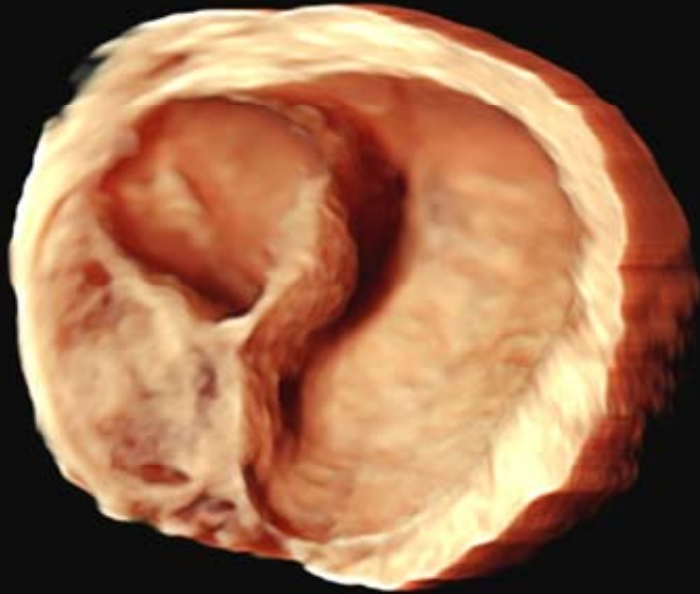
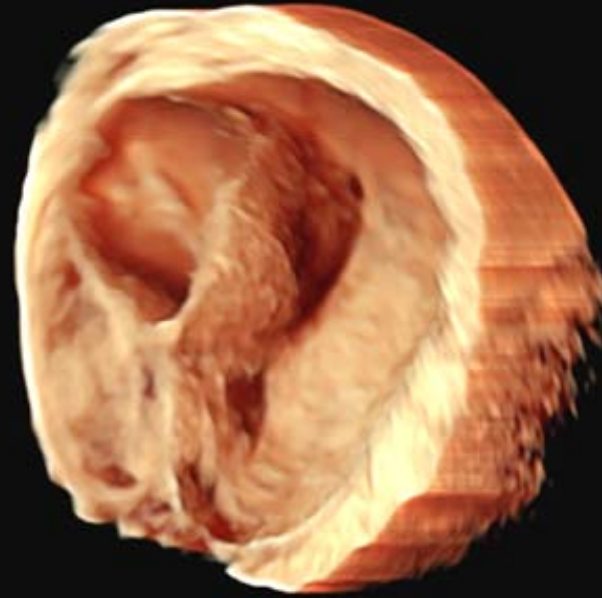
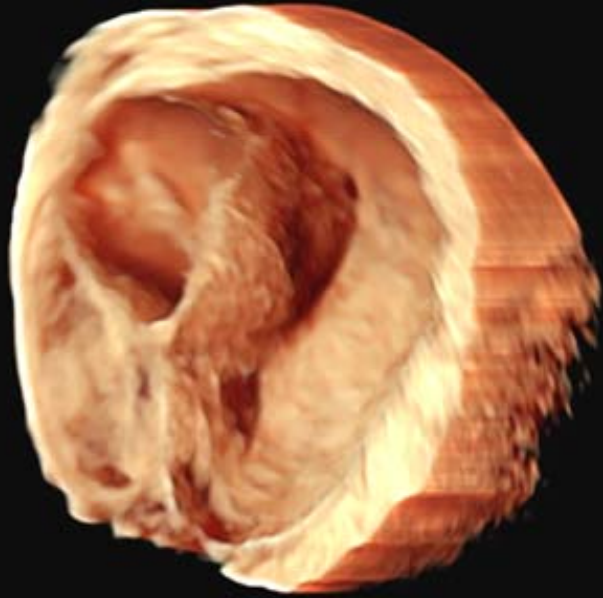
T:

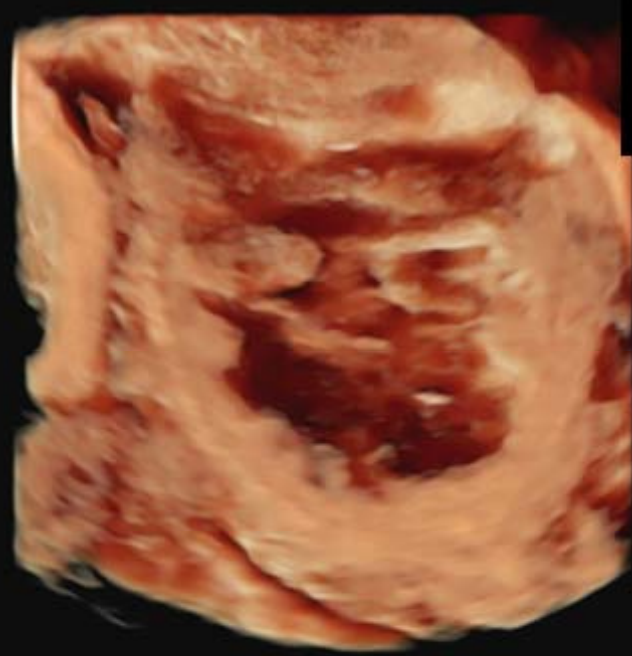
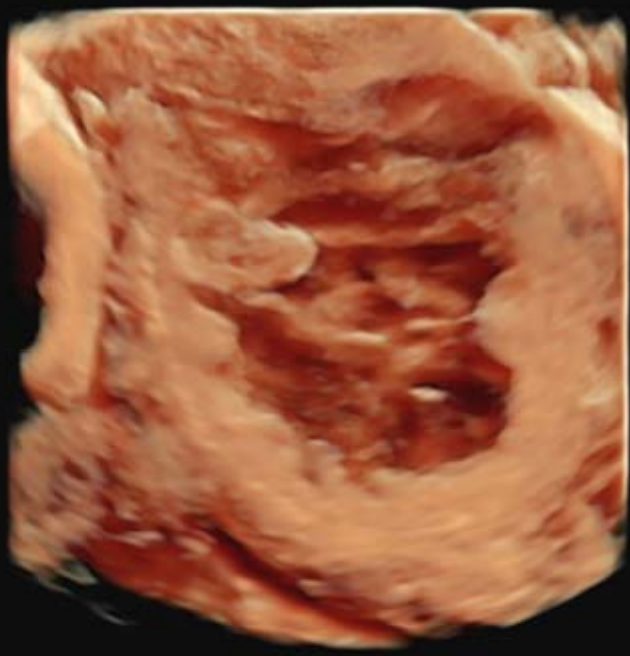
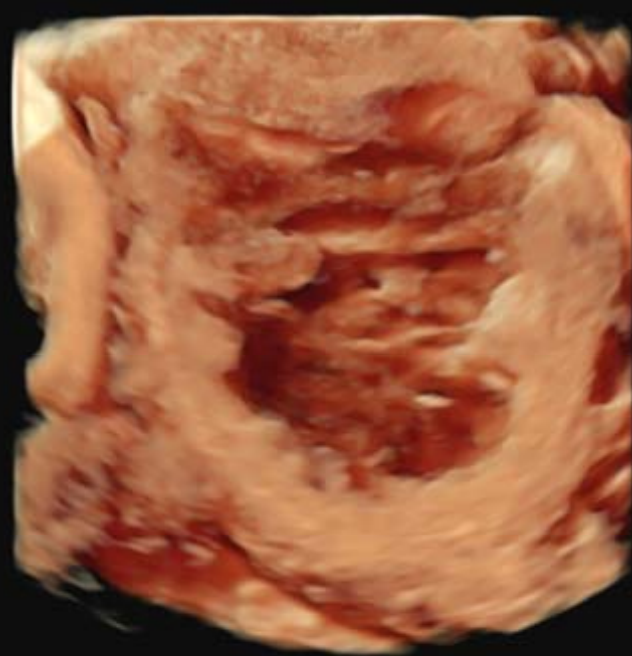
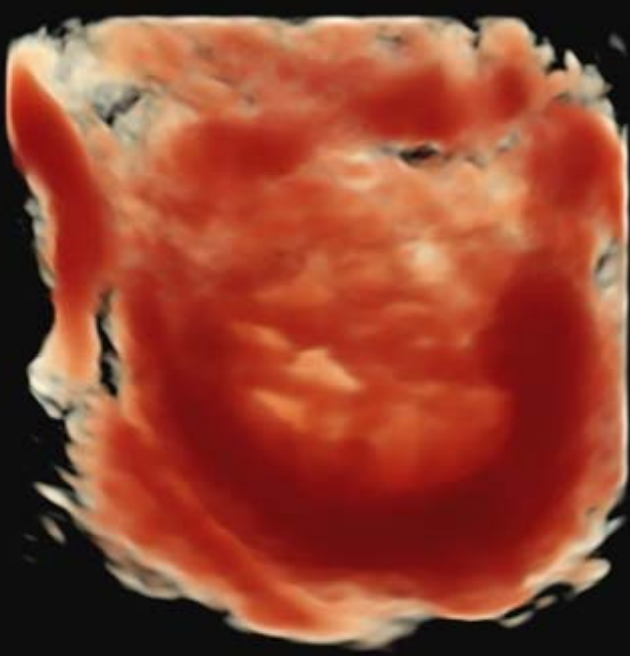




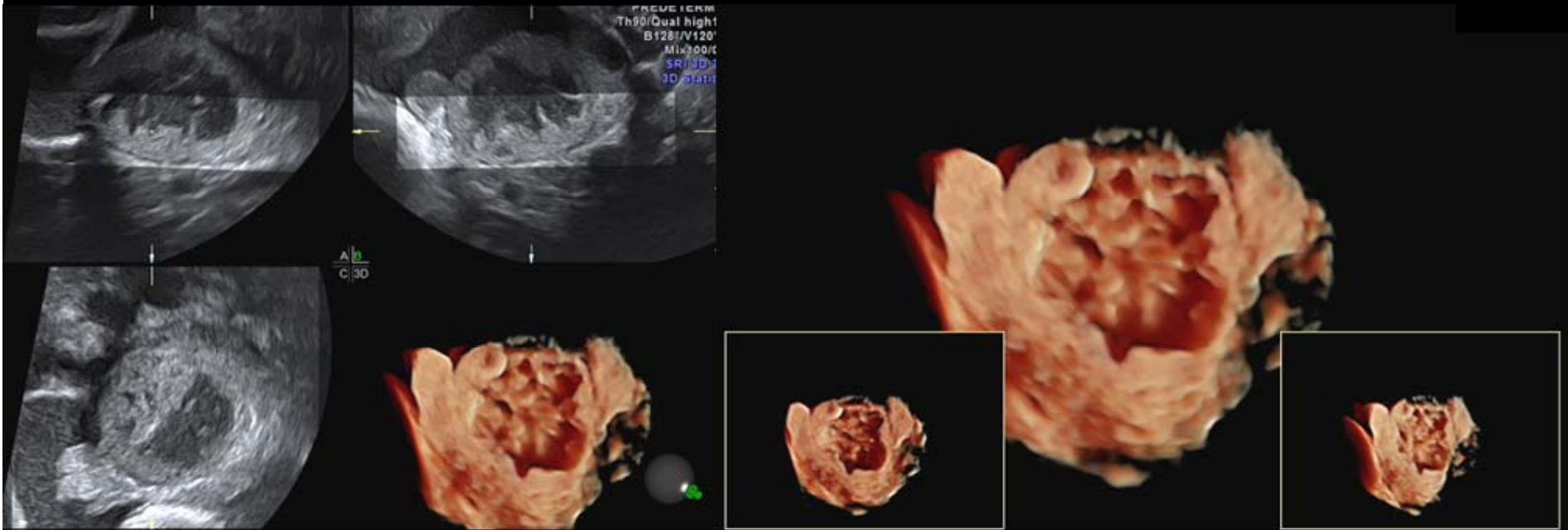
**POLIZYSTITISCHES  
TUMOR**

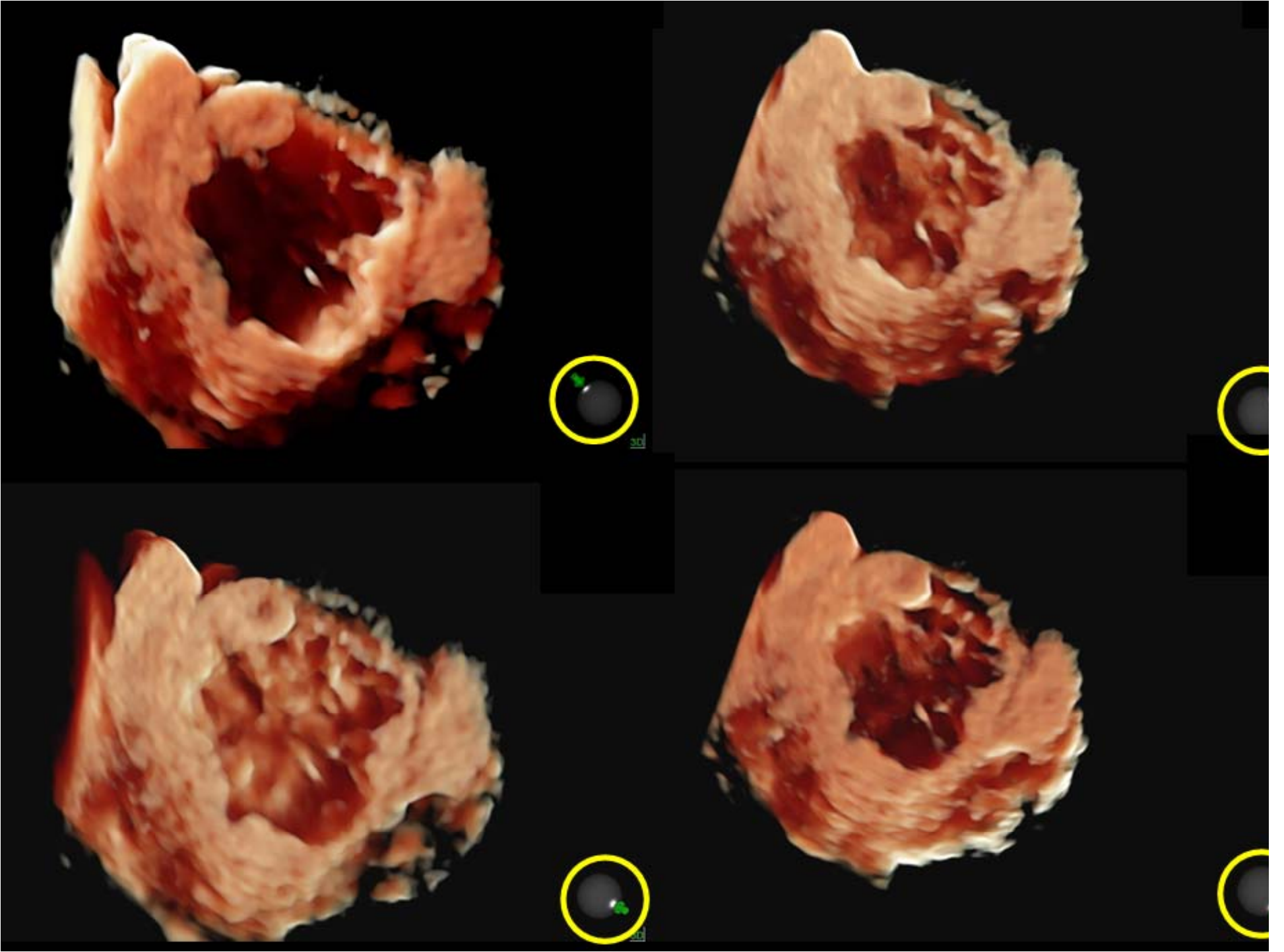


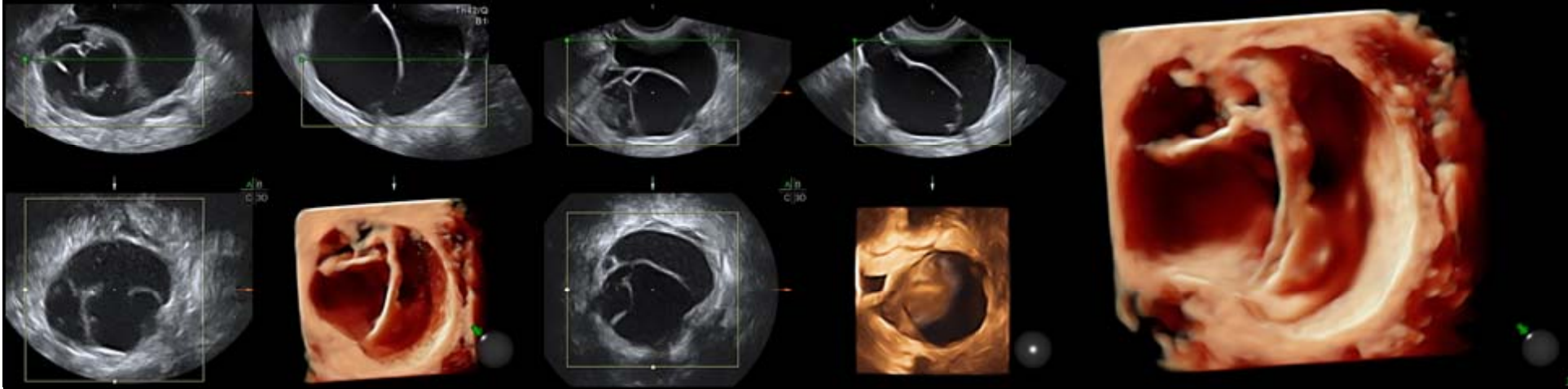




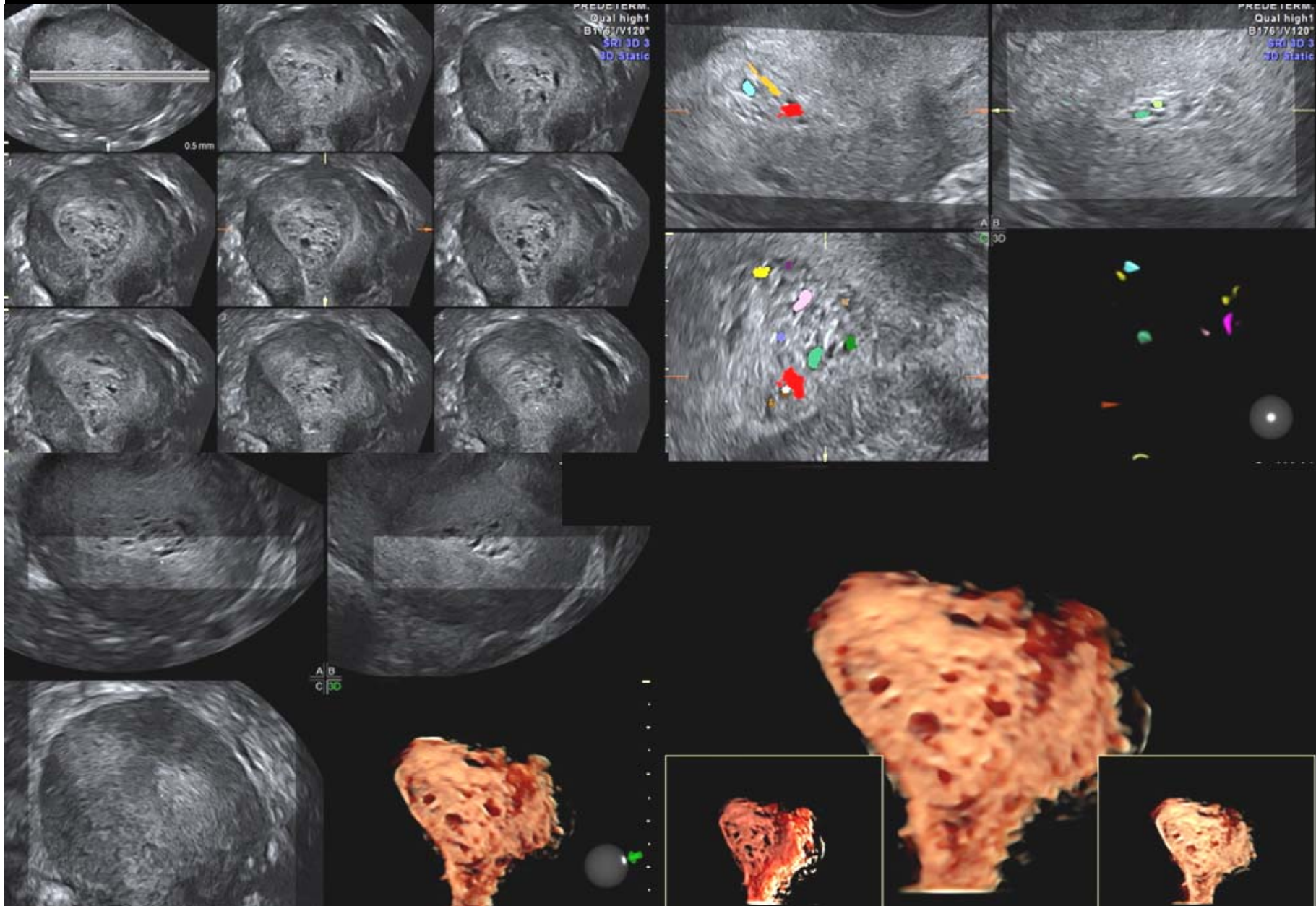




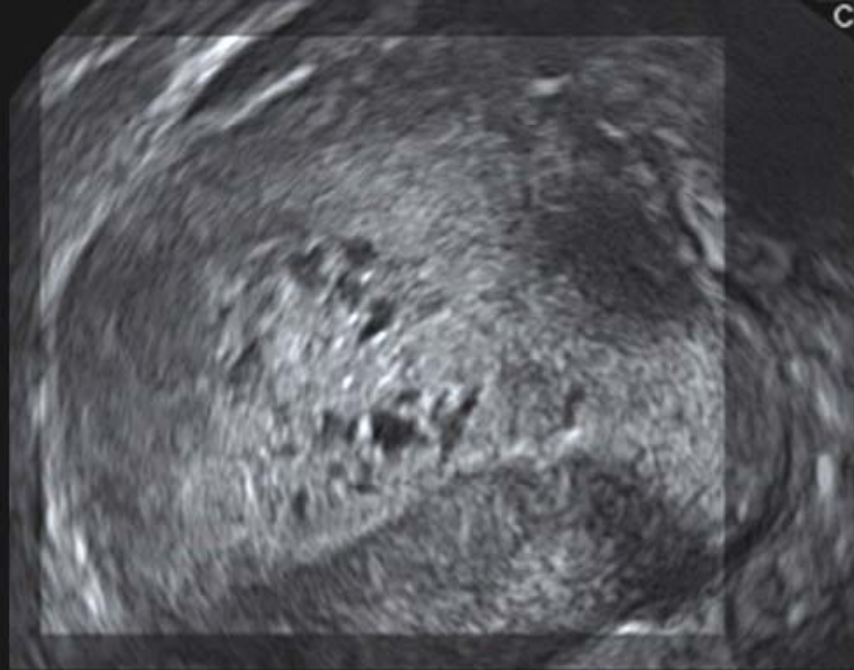



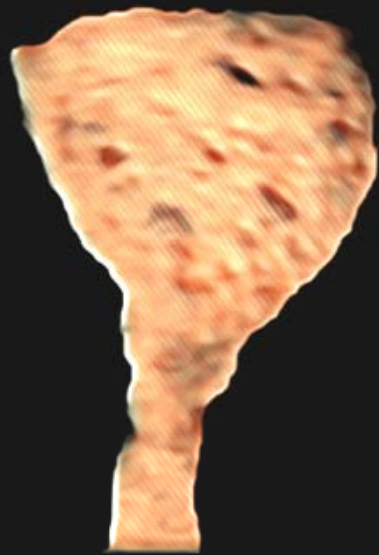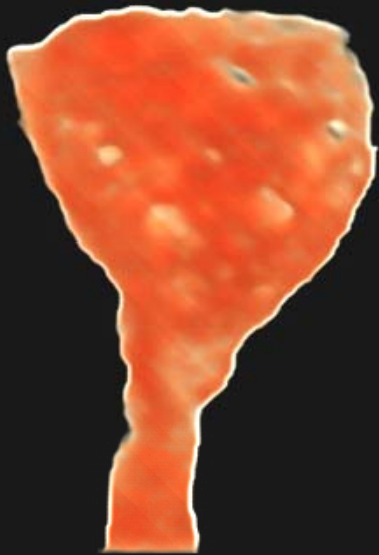
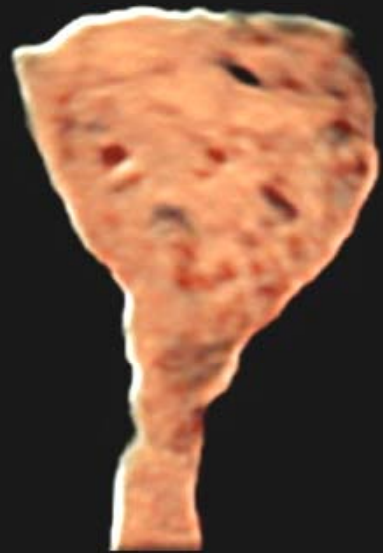# ENDOMETRIUM

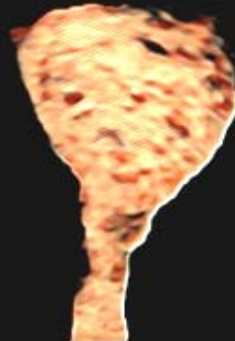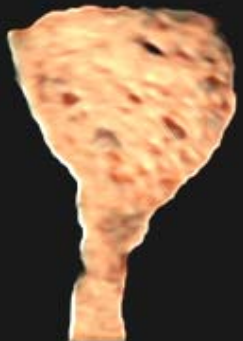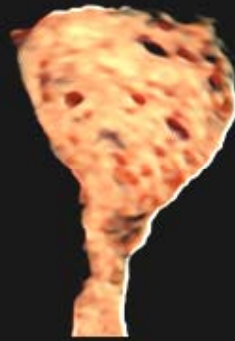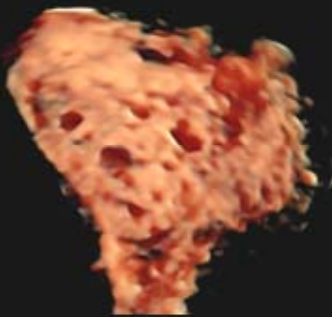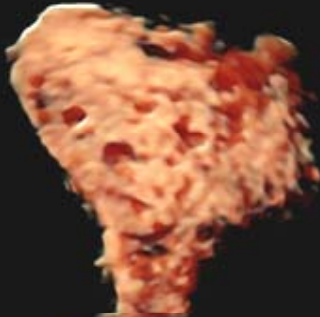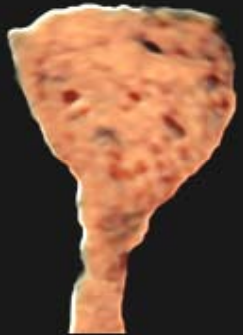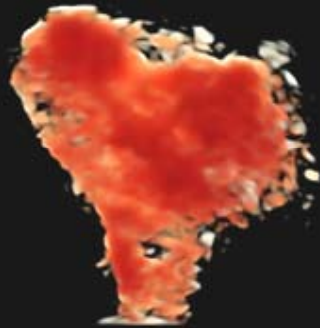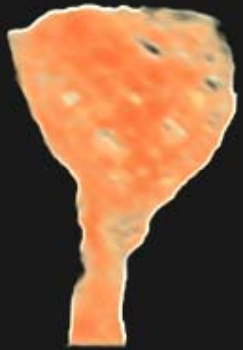


c | 3D



1





**ENDOMETRIUM**