LÁMINAS DIAGNÓSTICAS
Biología Celular y Tisular
(HISTOLOGÍA)
GRADO PODOLOGÍA CURSO 24-25

Departamento de Patología

Unidad de Histología

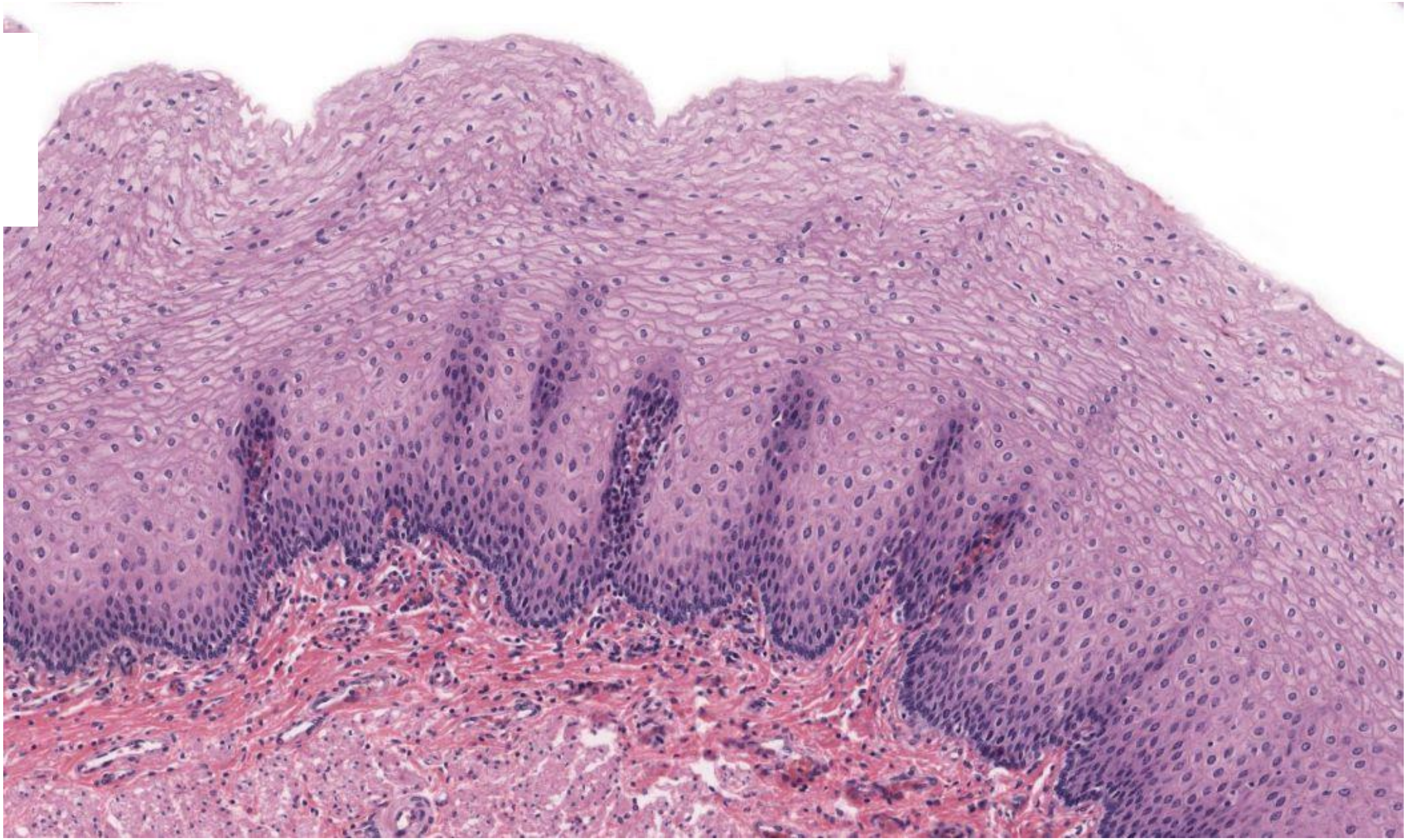

Lámina 1

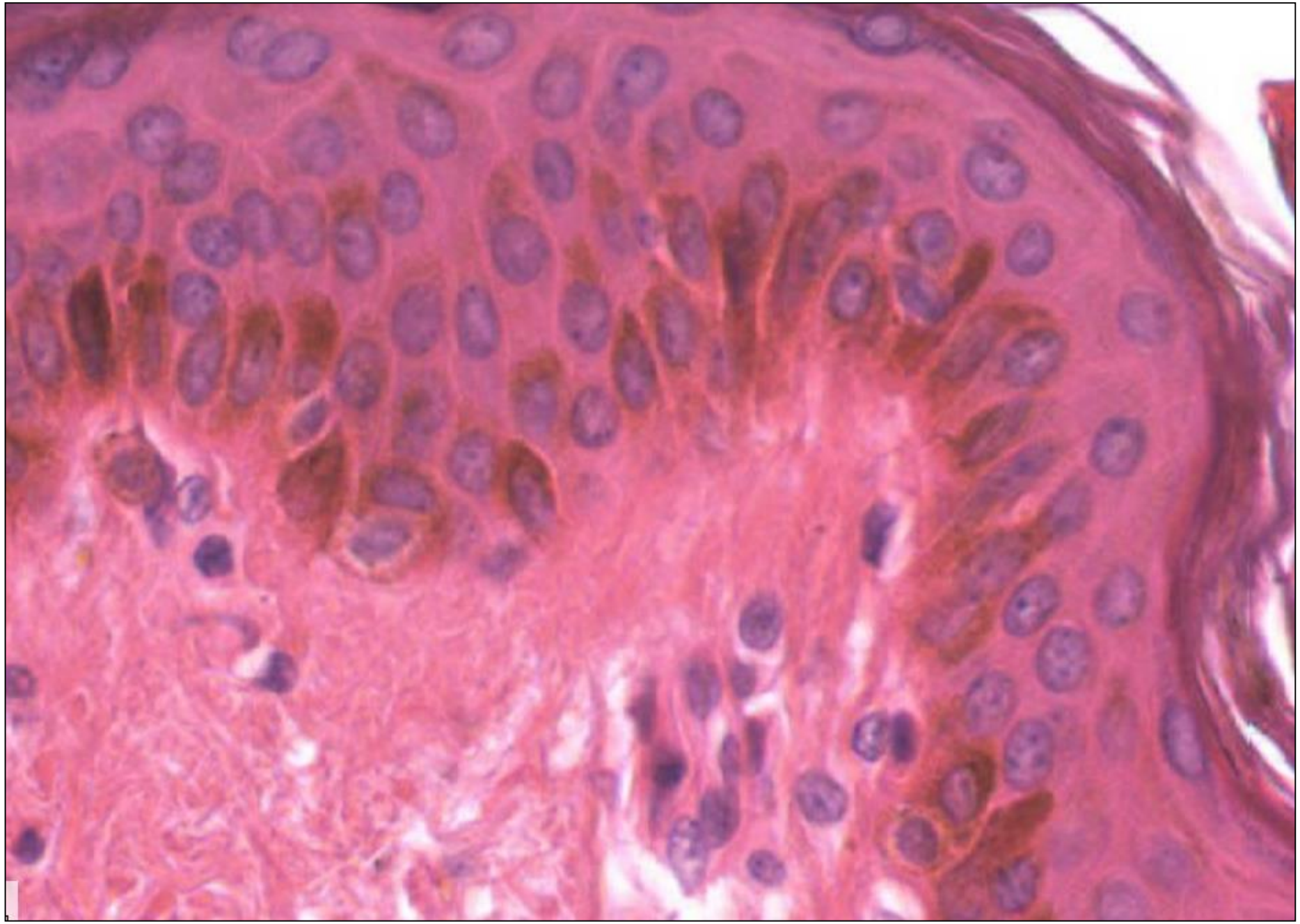

Lámina 2

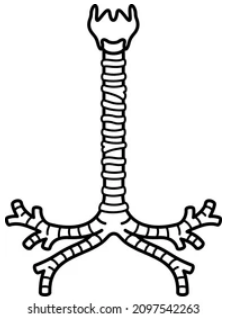

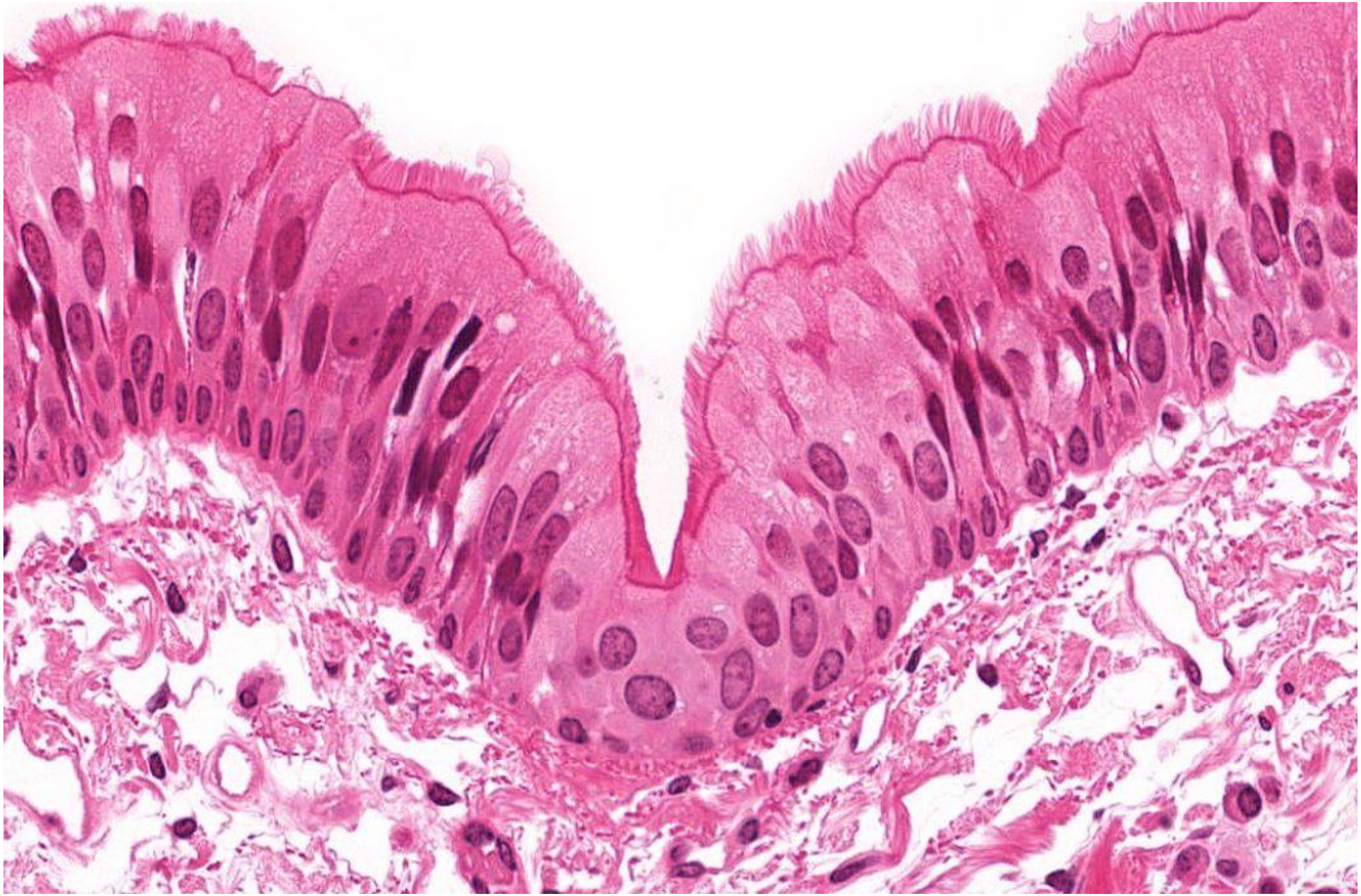

Lámina 3

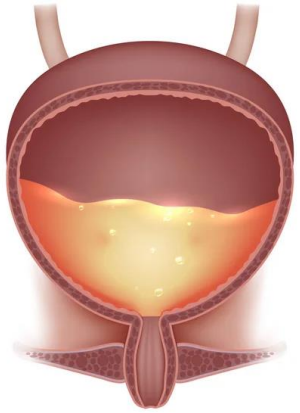

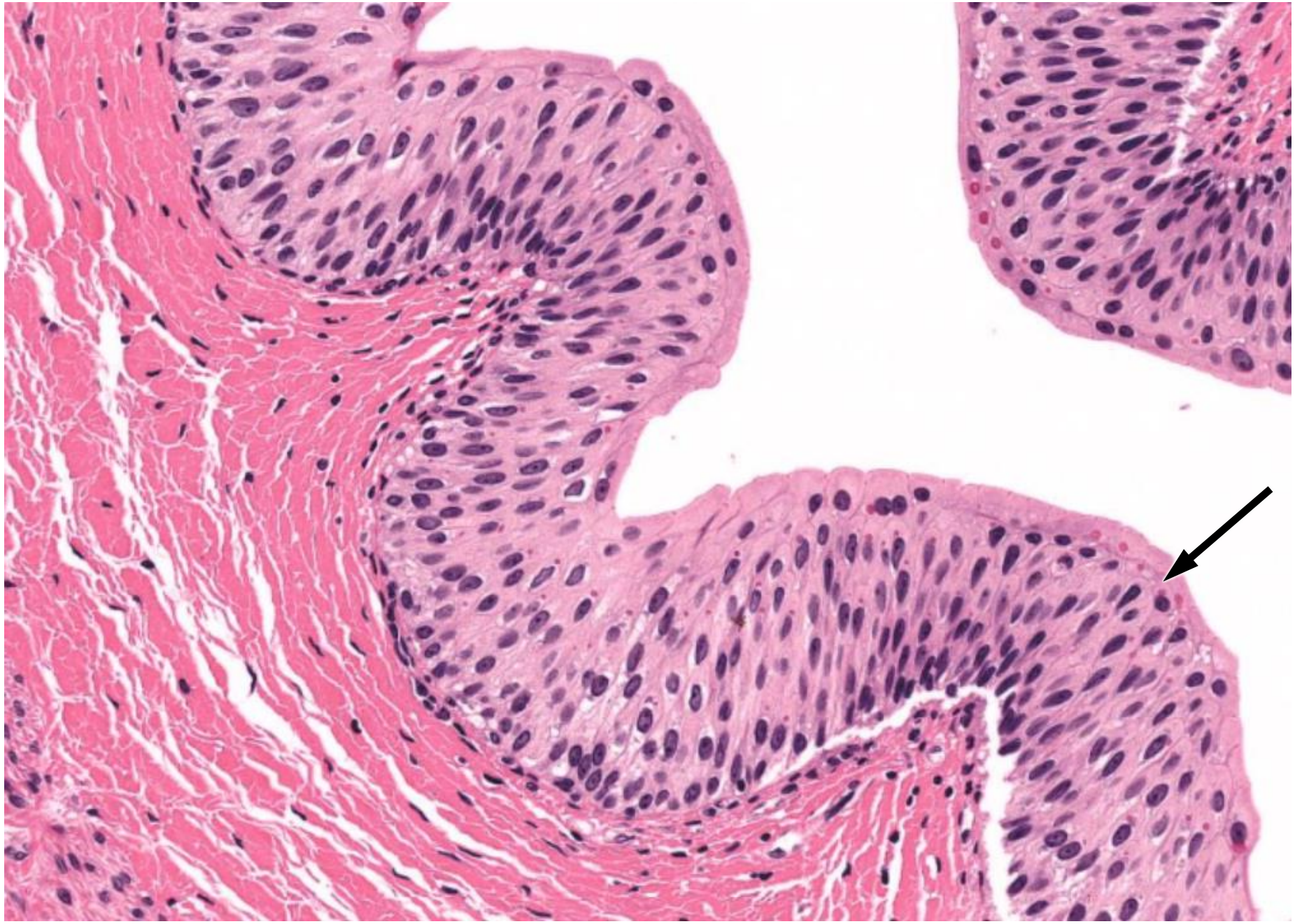

Lámina 4

Brown fat cell
Beige fat cell
White fat cell
shutterstock.com · 1682998204

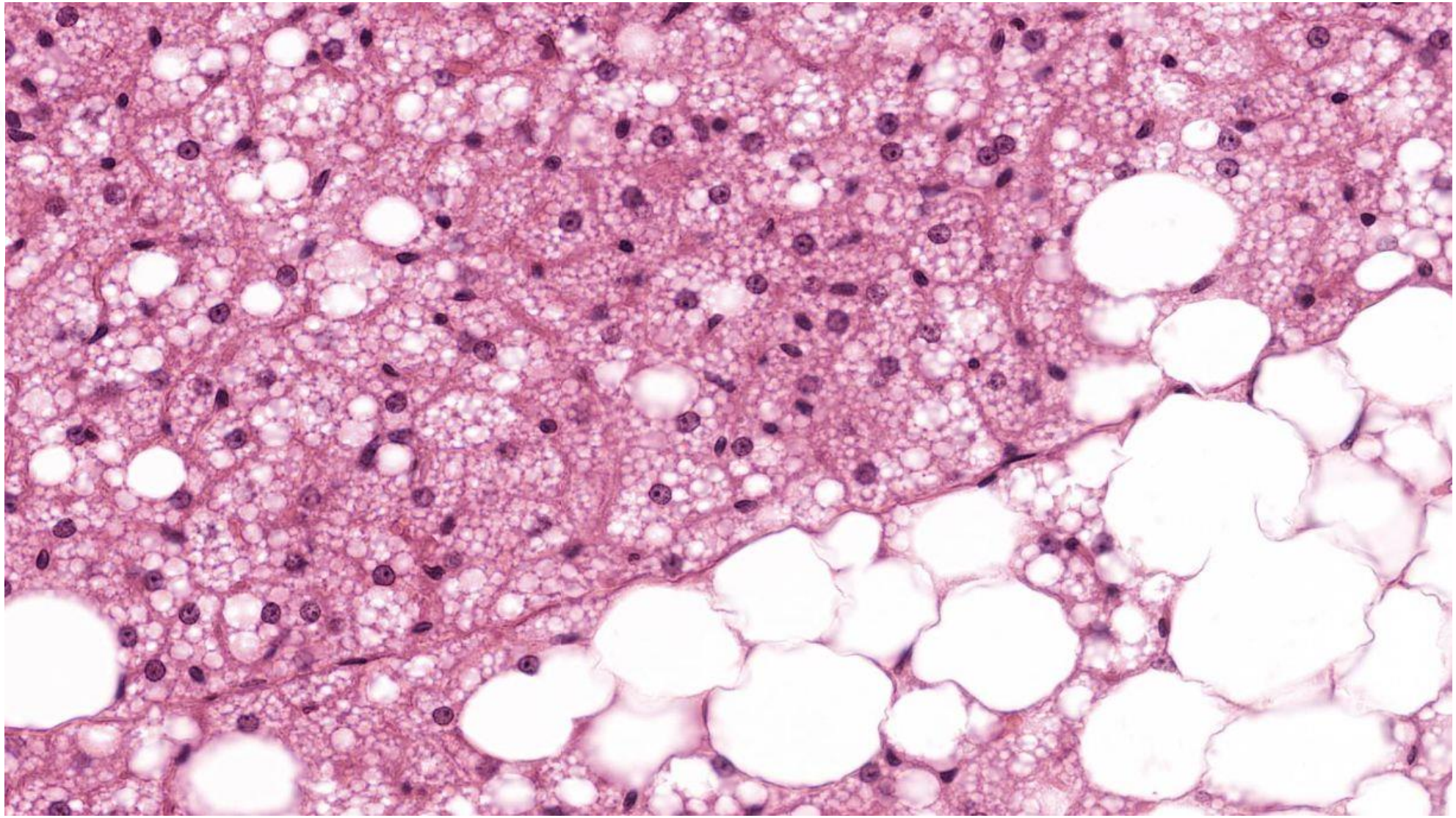

Lámina 5

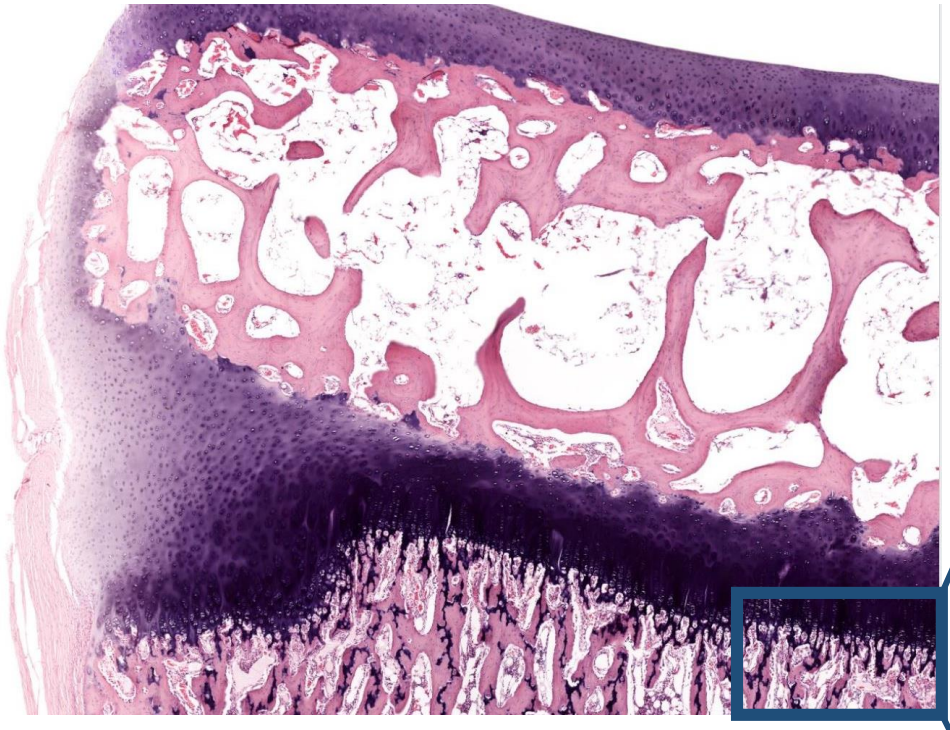

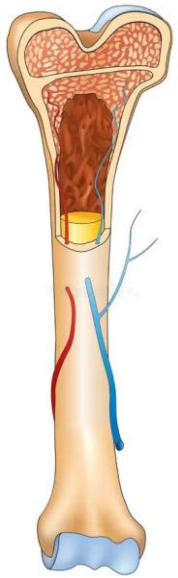

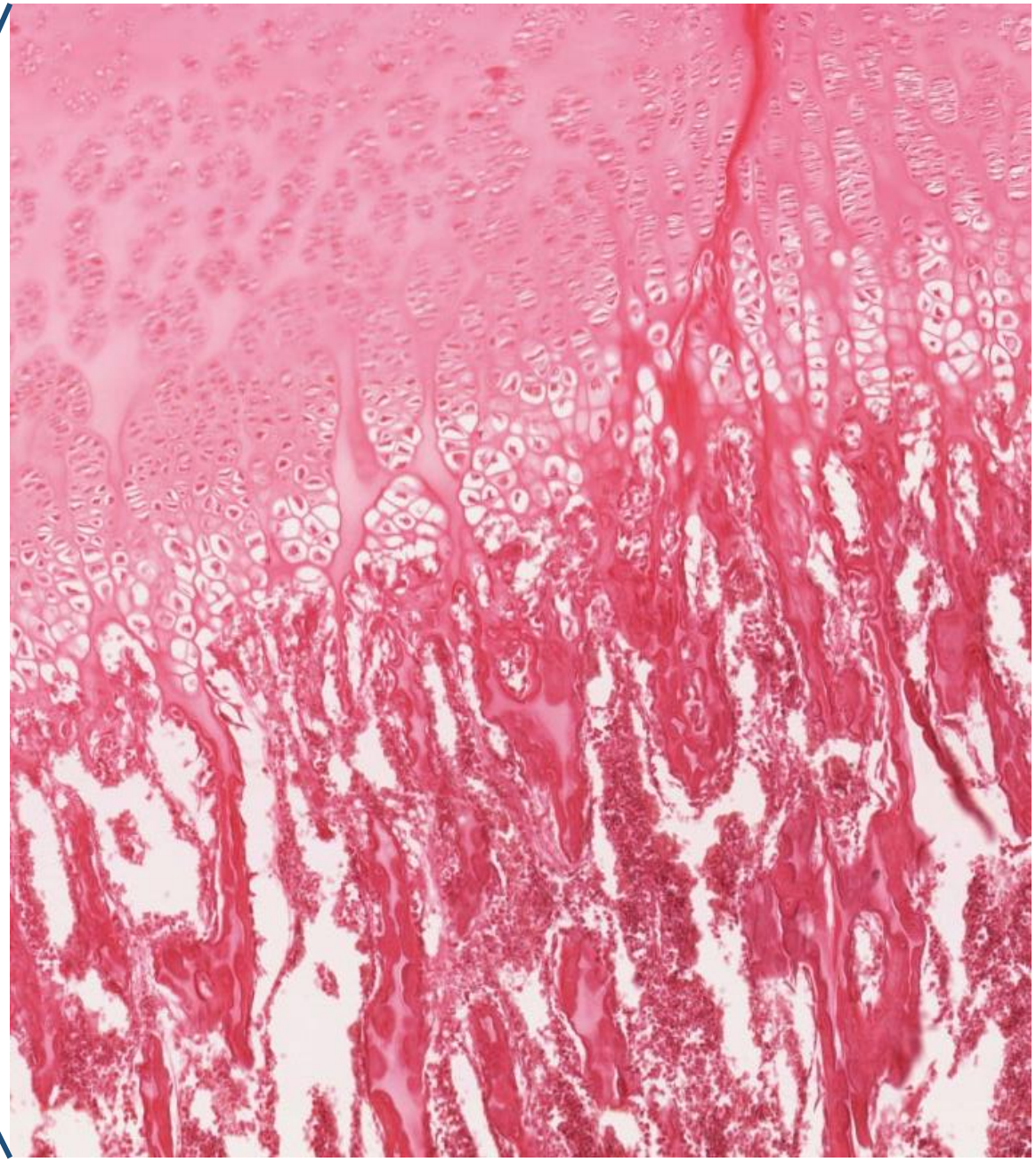

Lámina 6

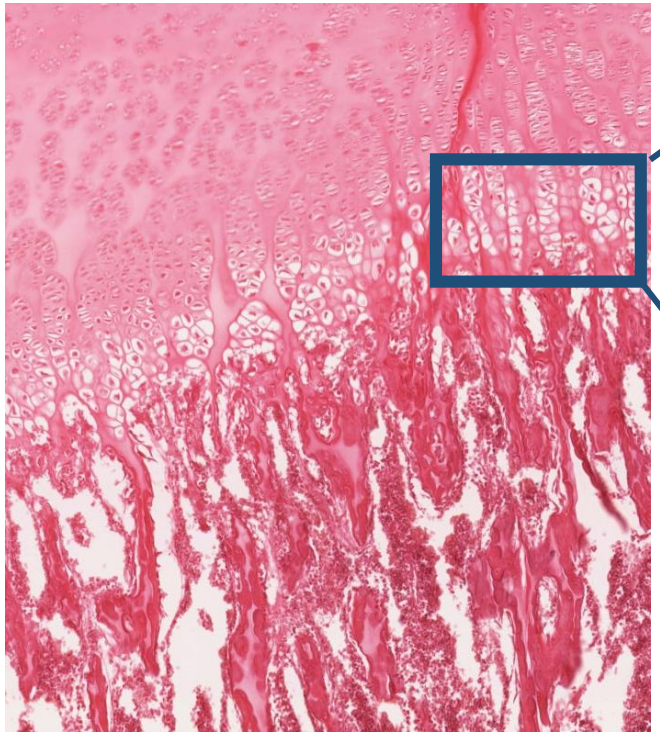

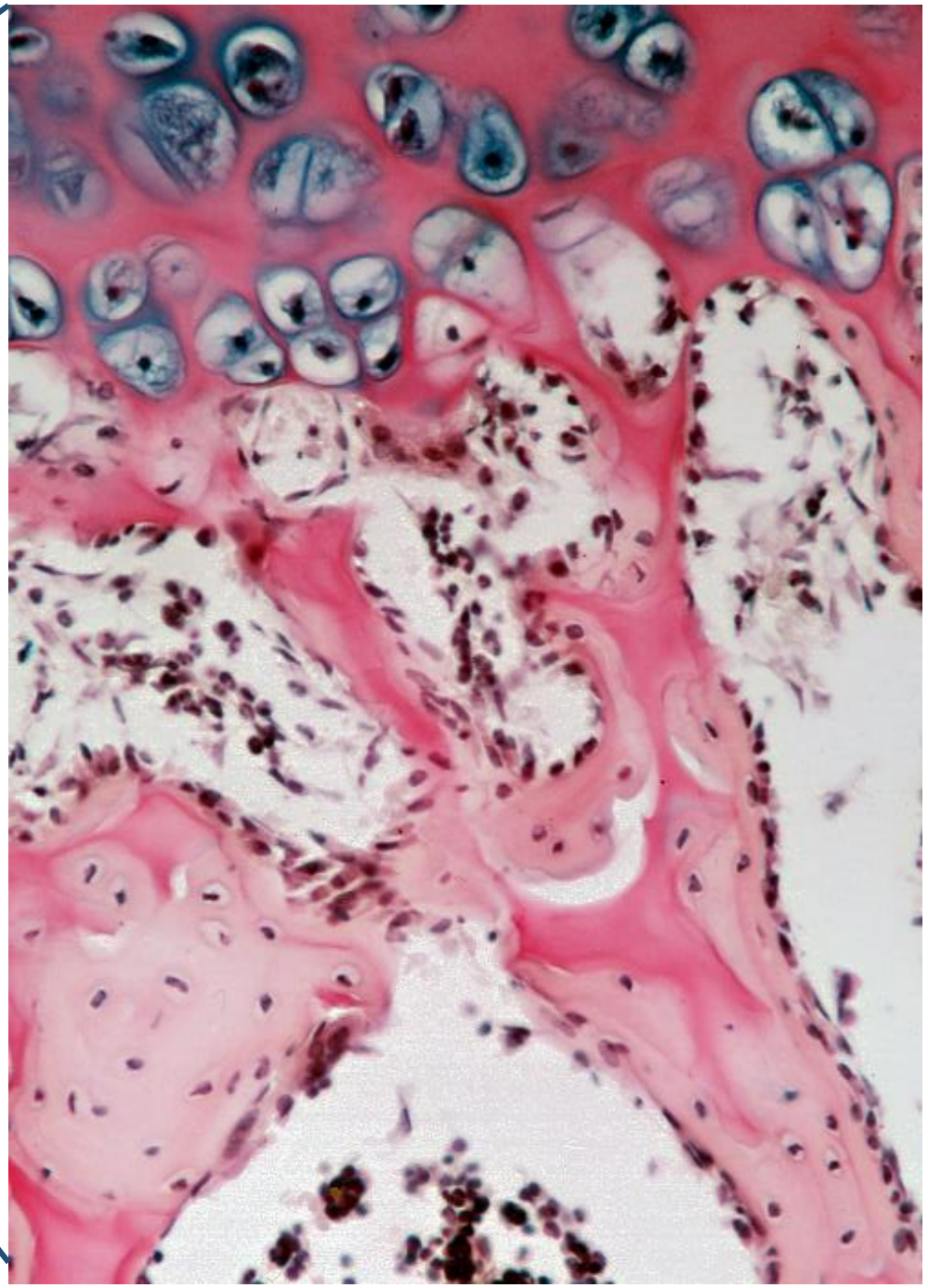

Lámina 7

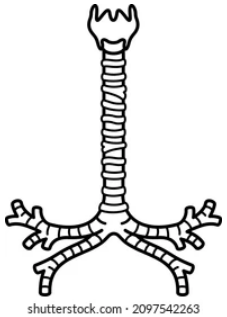

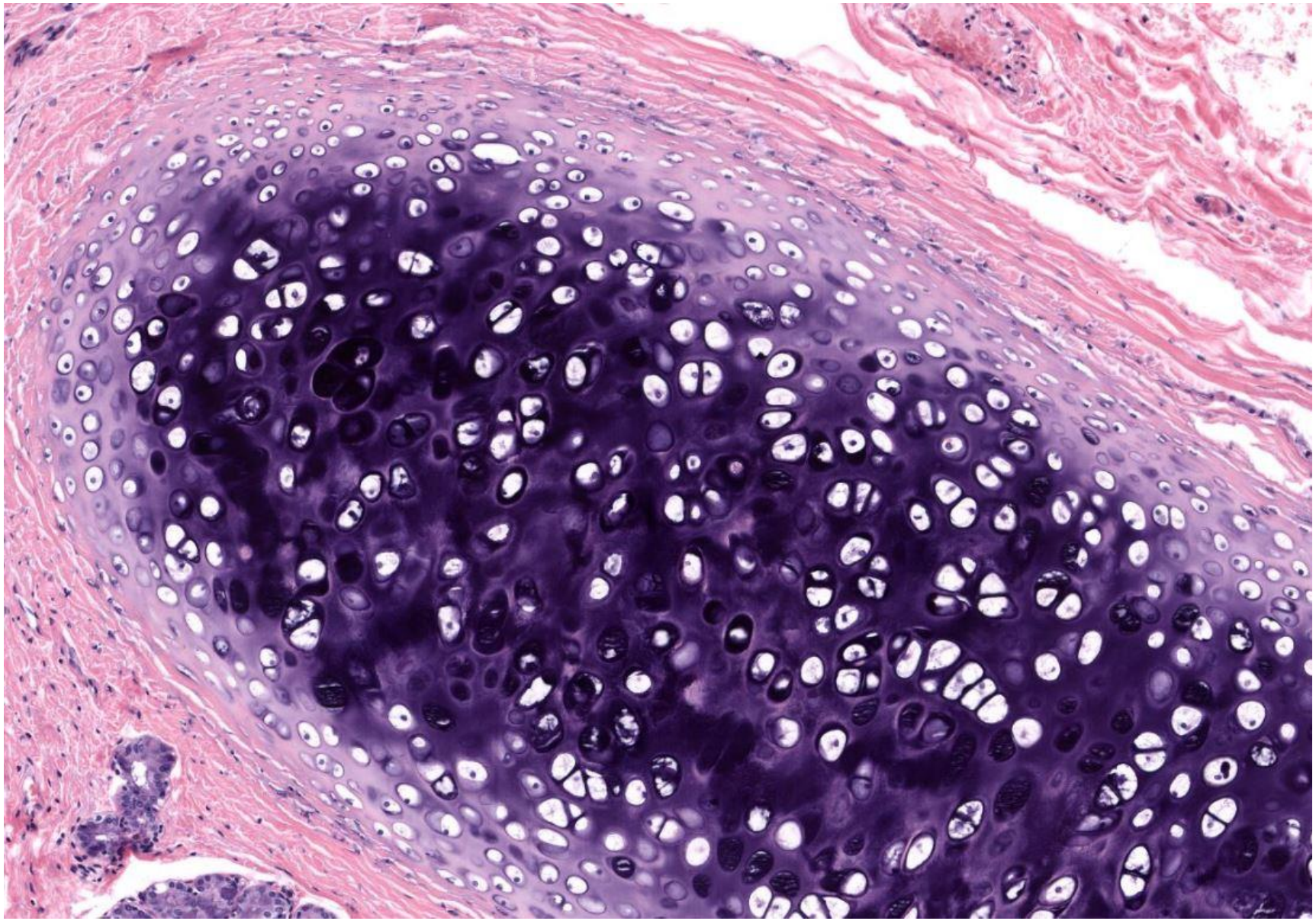

Lámina 8

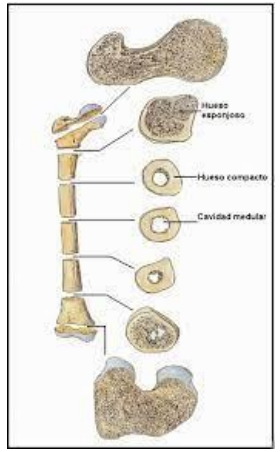

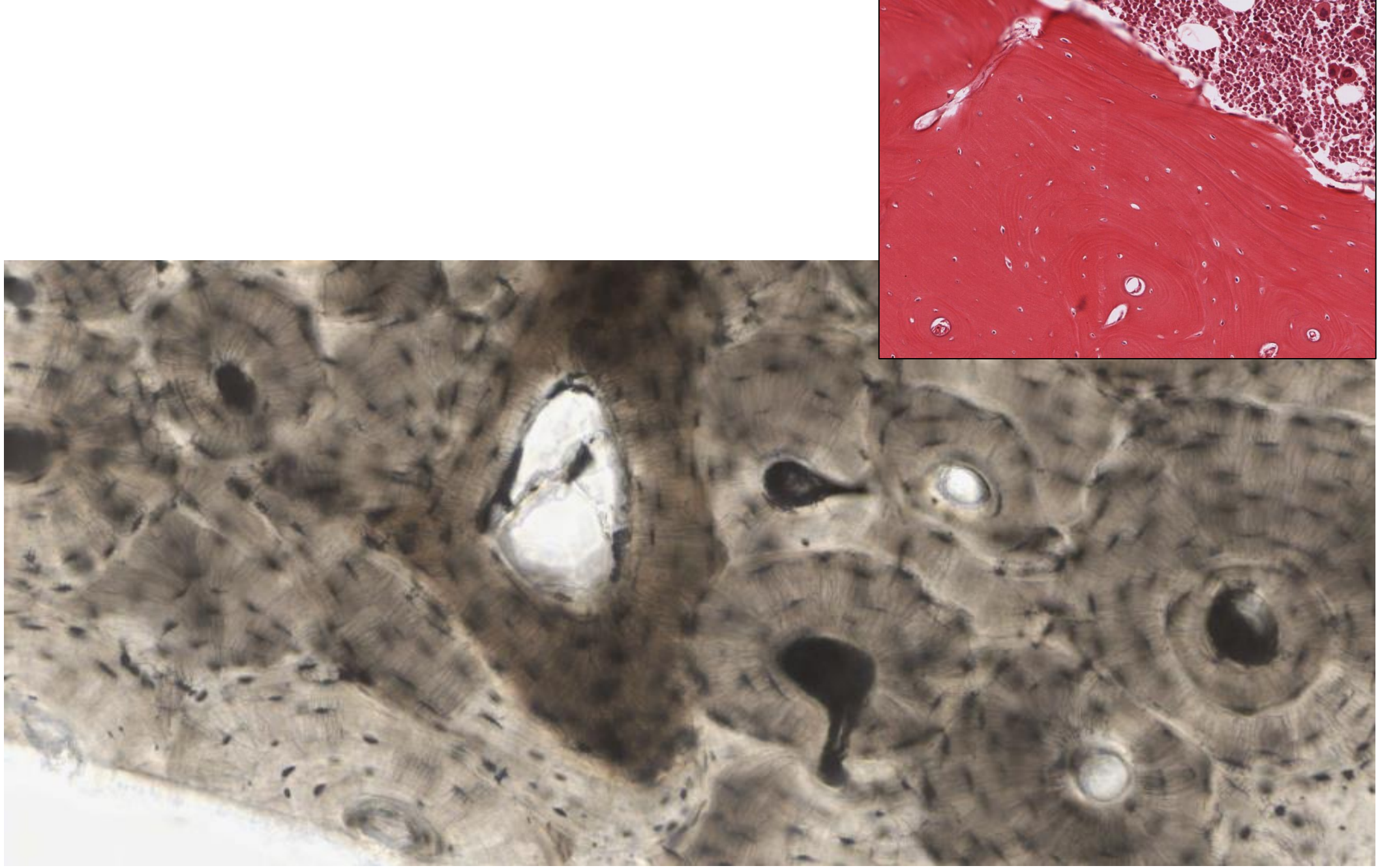

Lámina 9

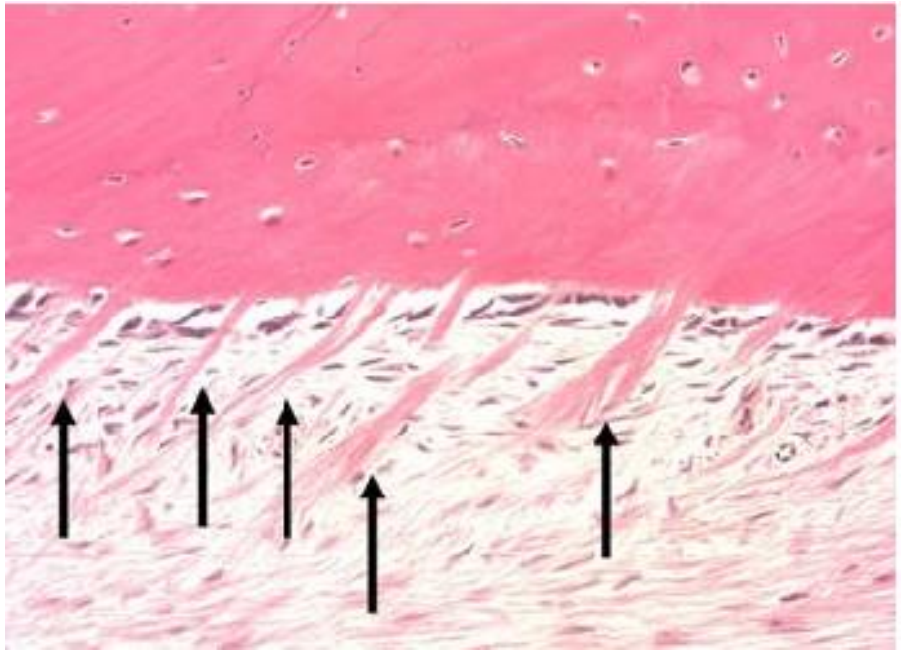

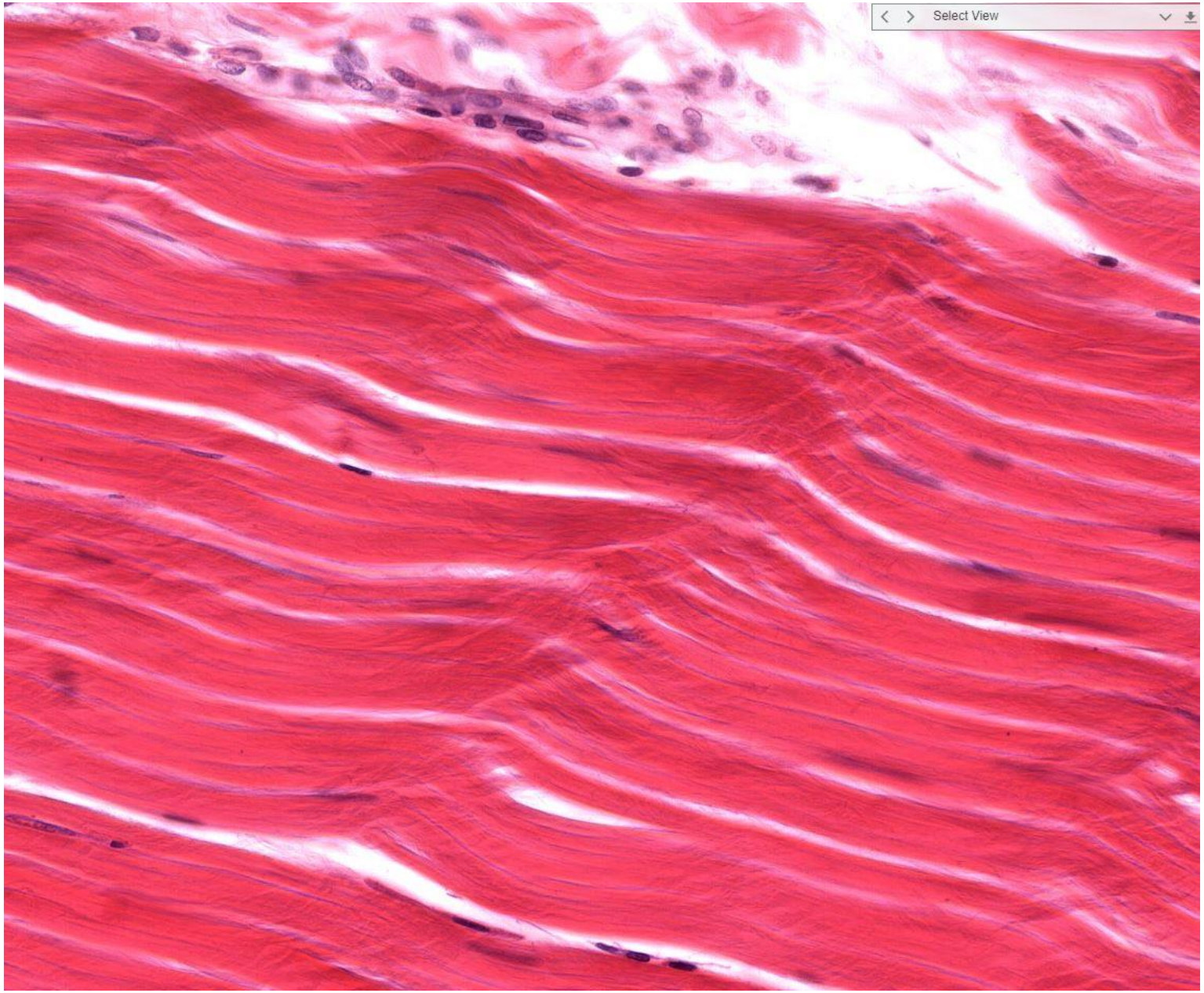

Lámina 10

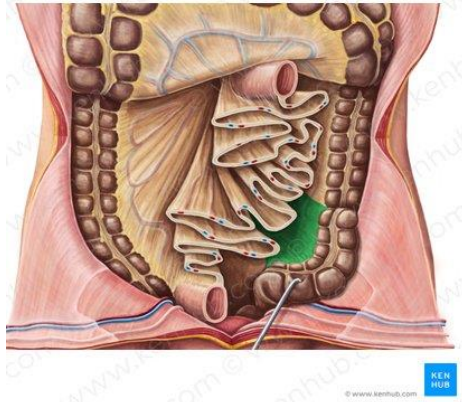

Lámina 11

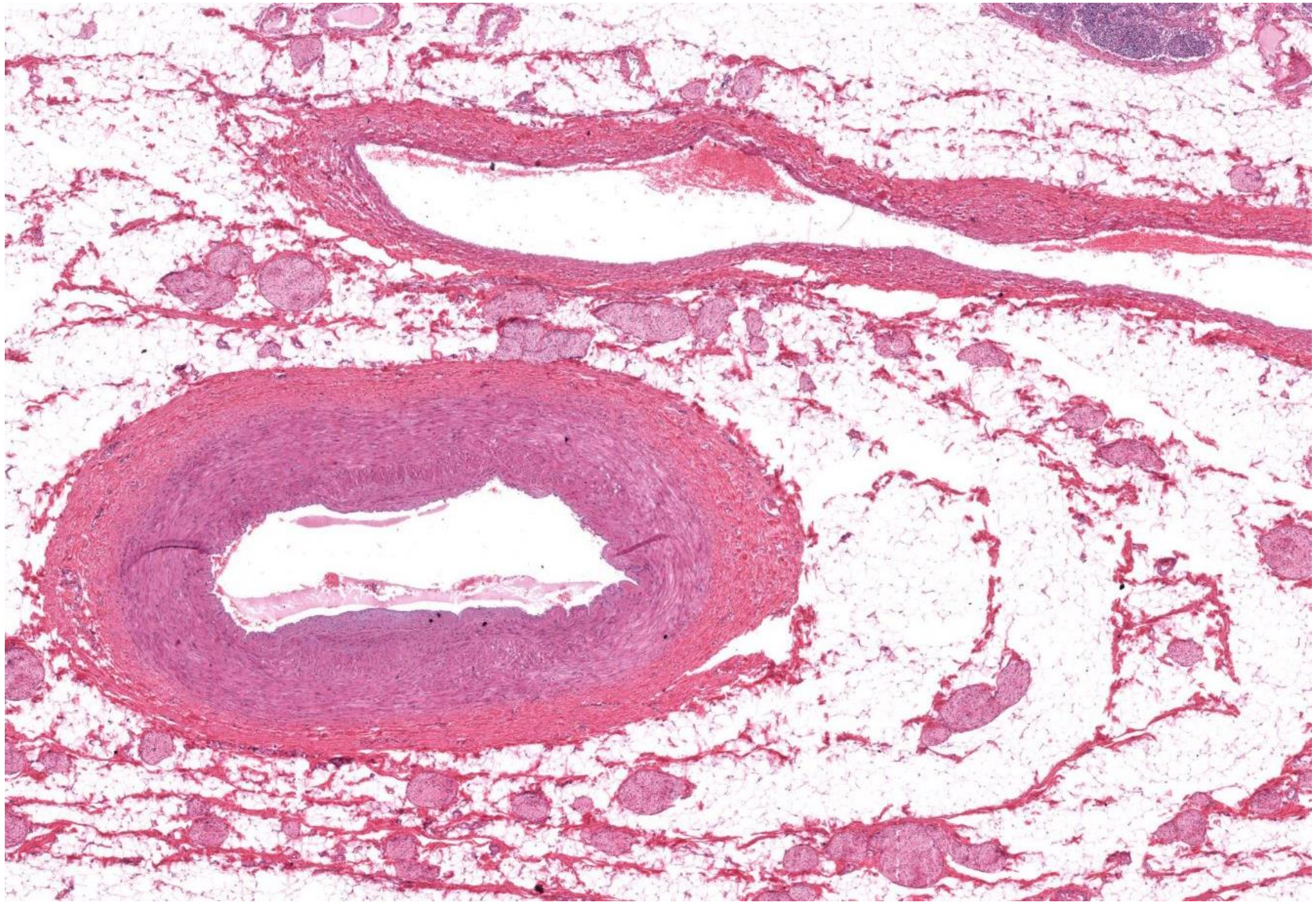

Lámina 11

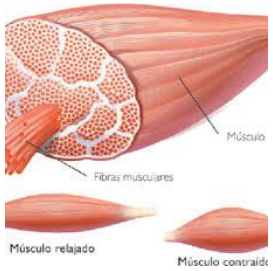
Músculo
Fibras musculares
Músculo relajado
Músculo contraído

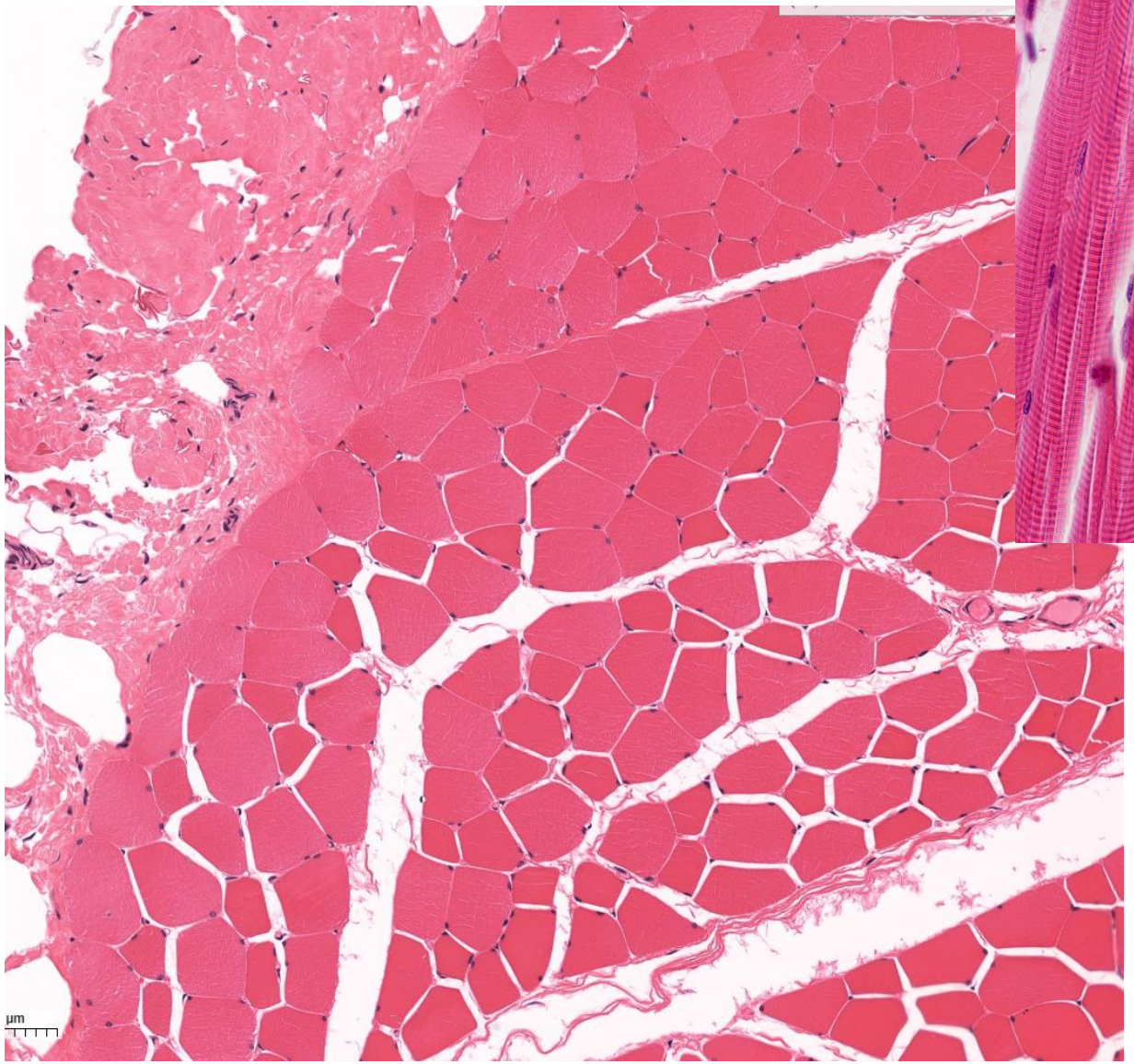
µm

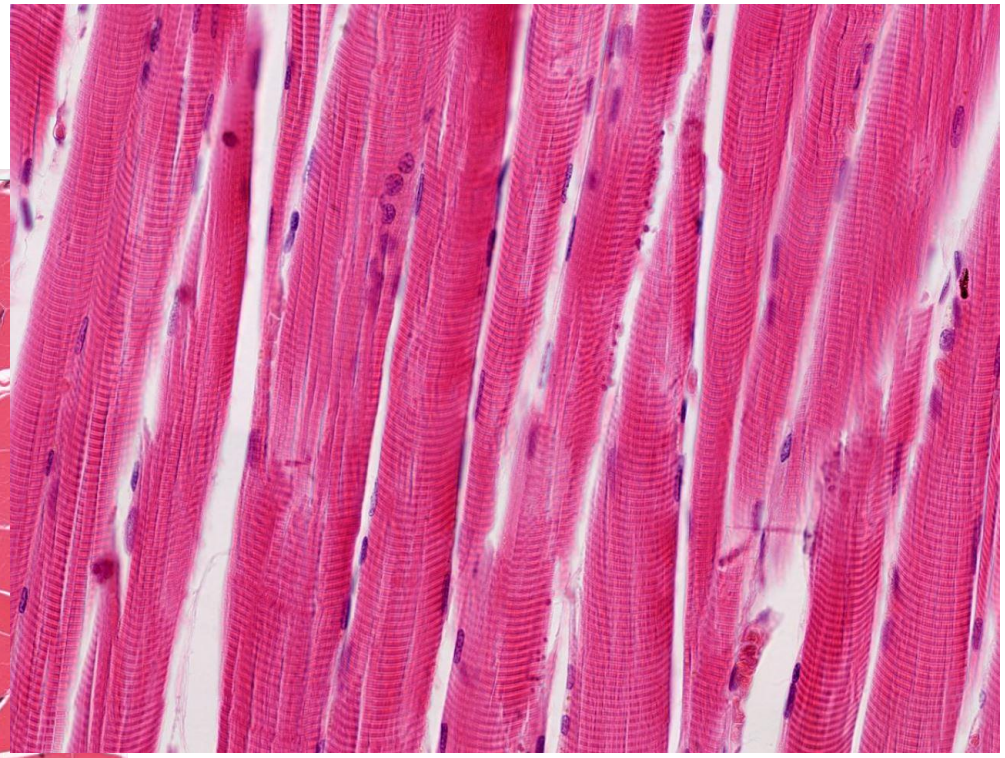

Lámina 12

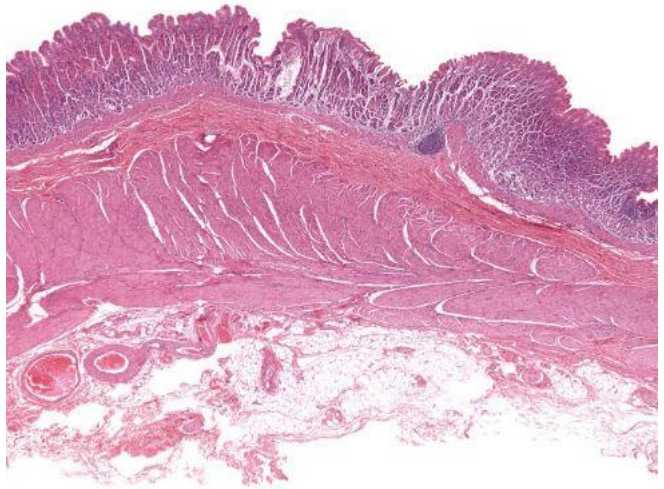

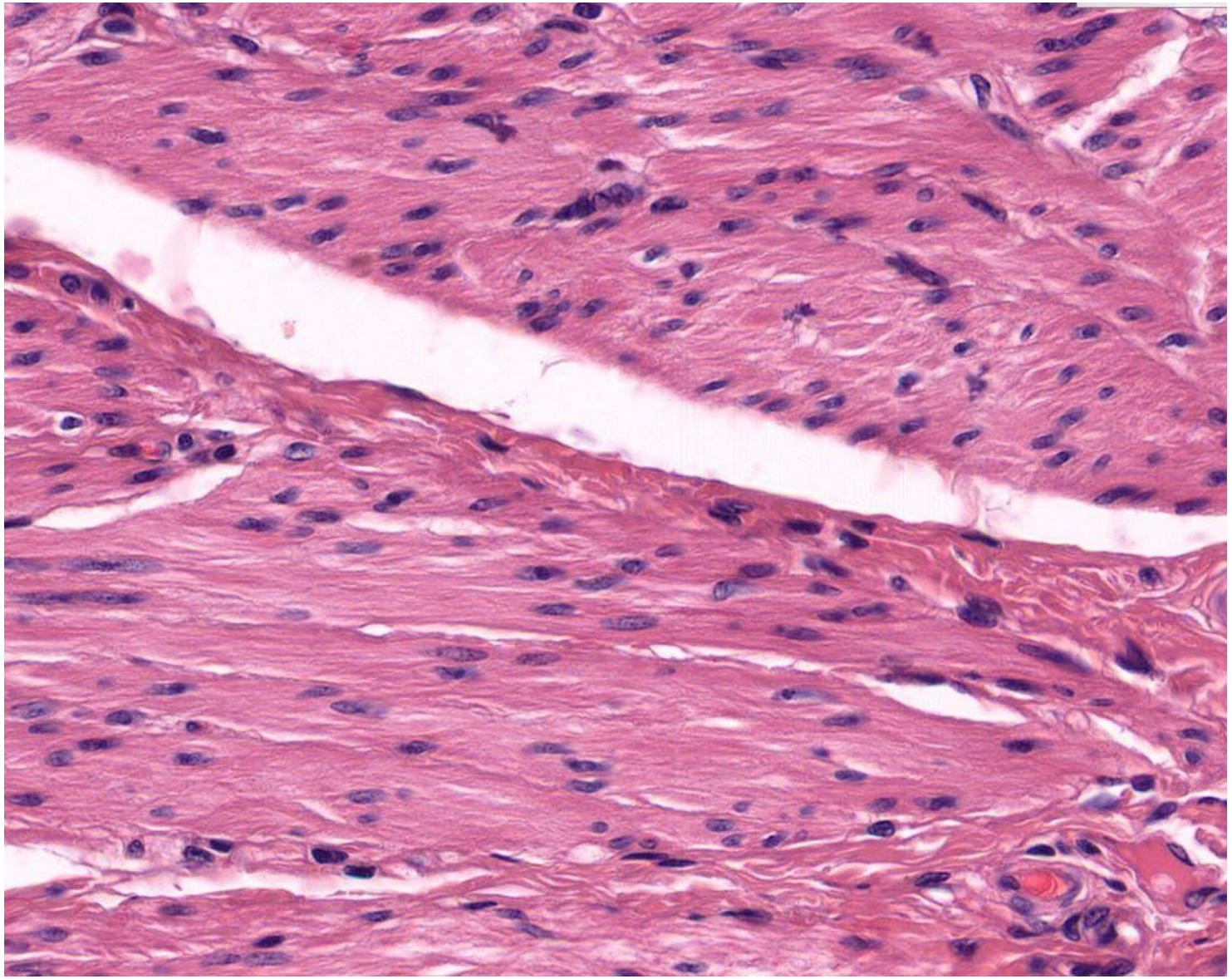

Lámina 13

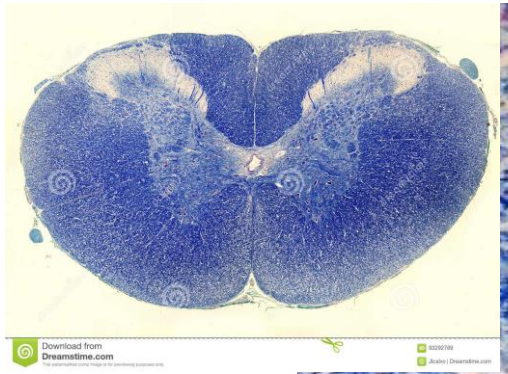

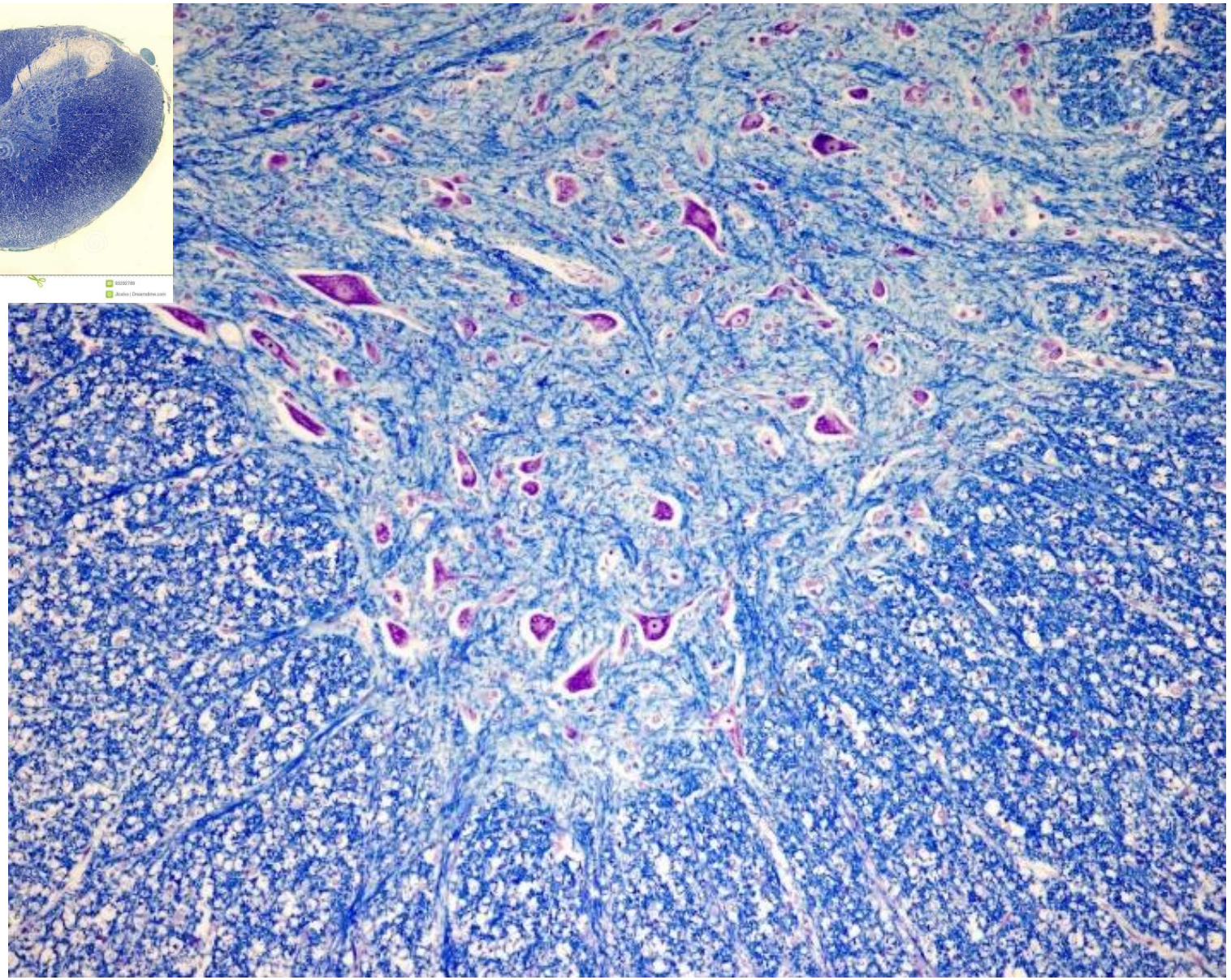

Lámina 14

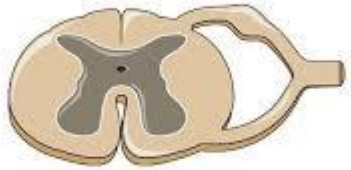

Lámina 14

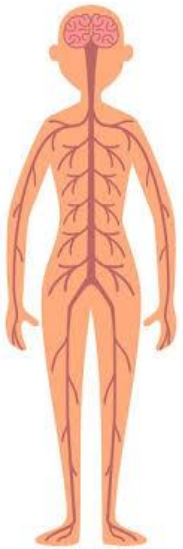

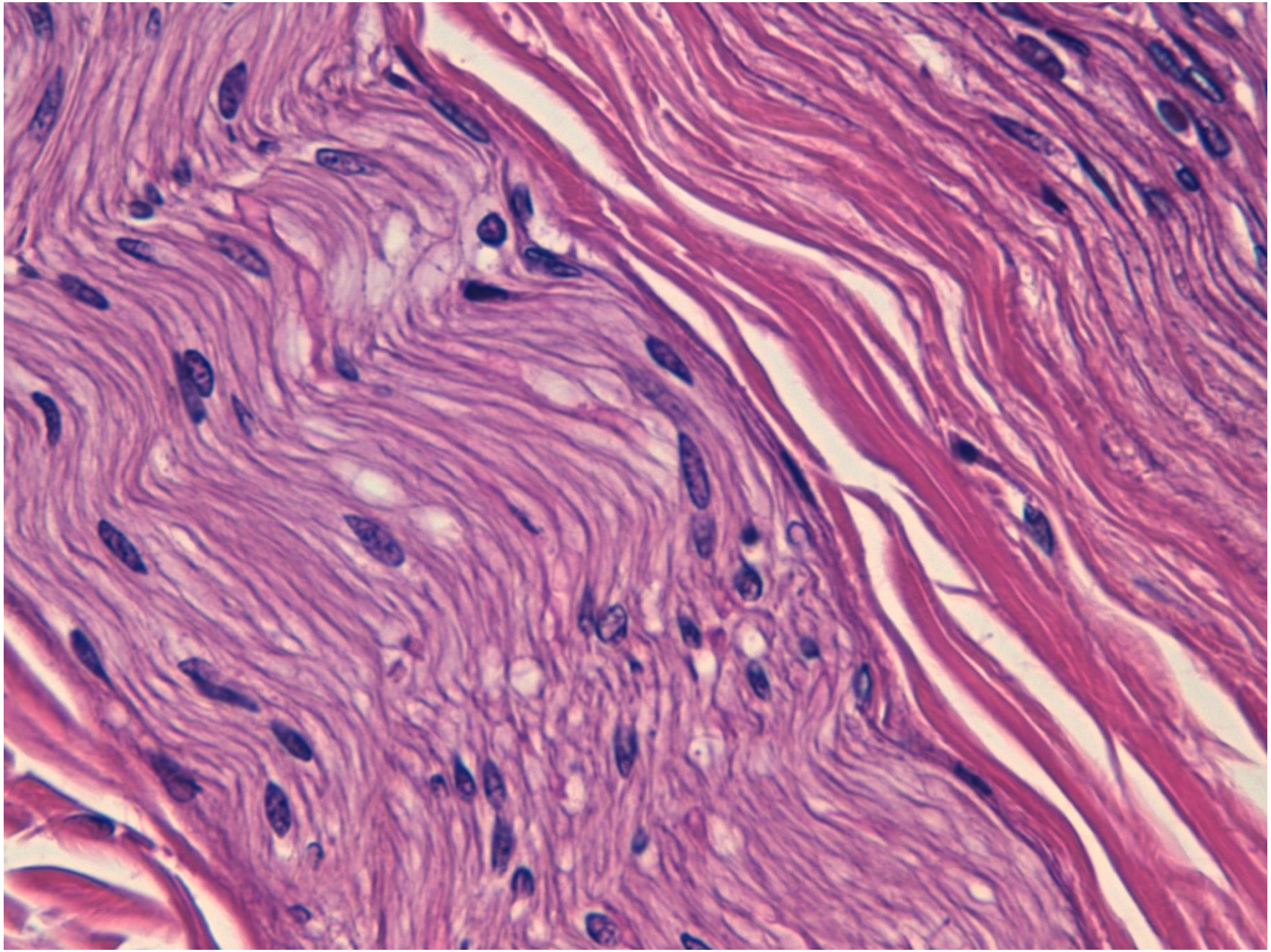

Lámina 15

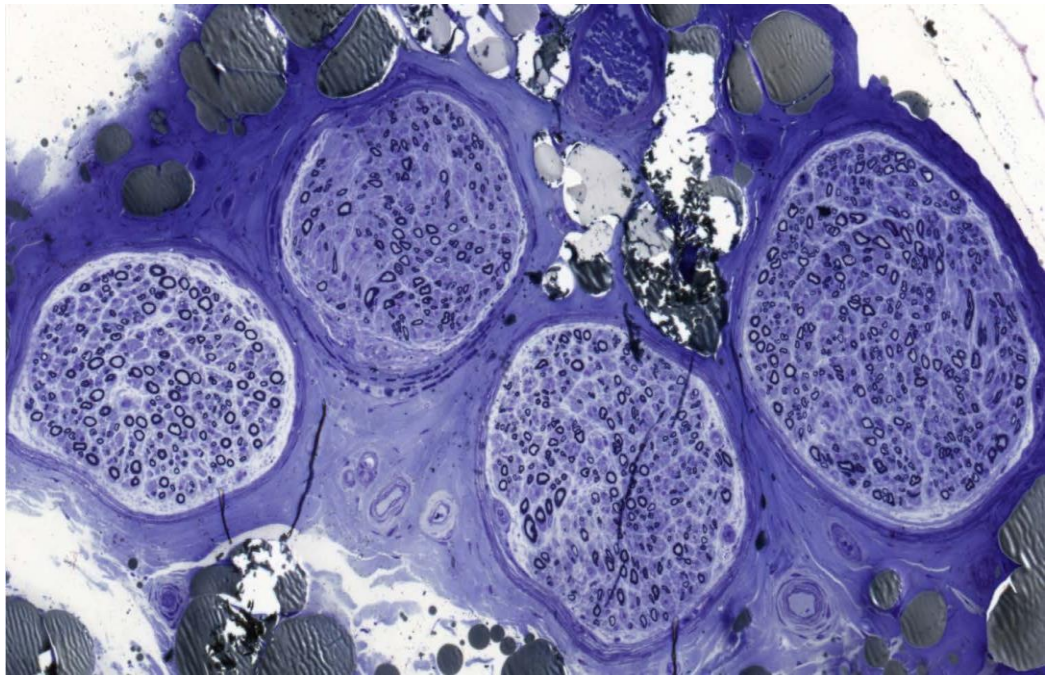

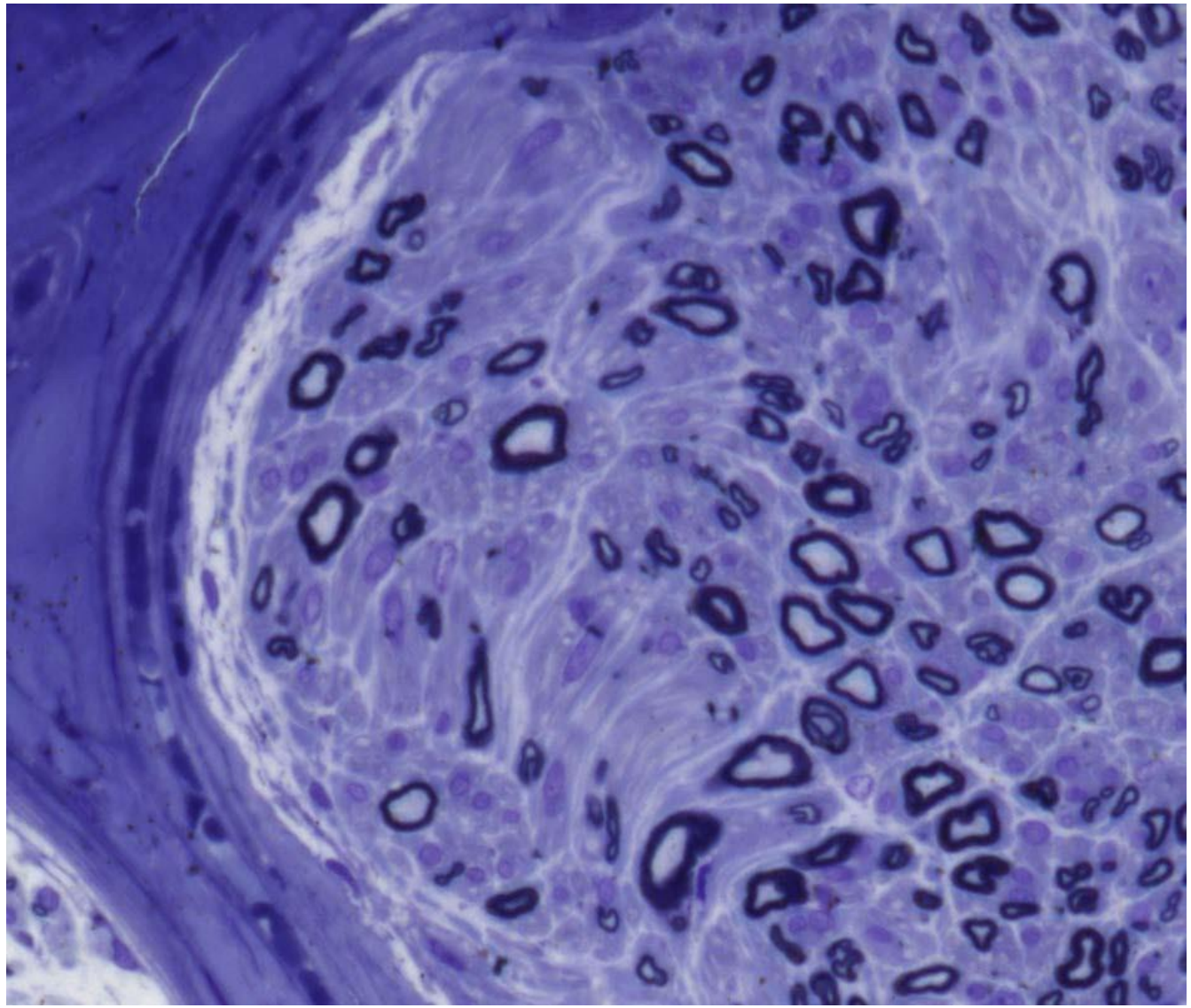

Lámina 16

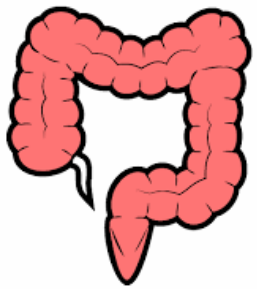

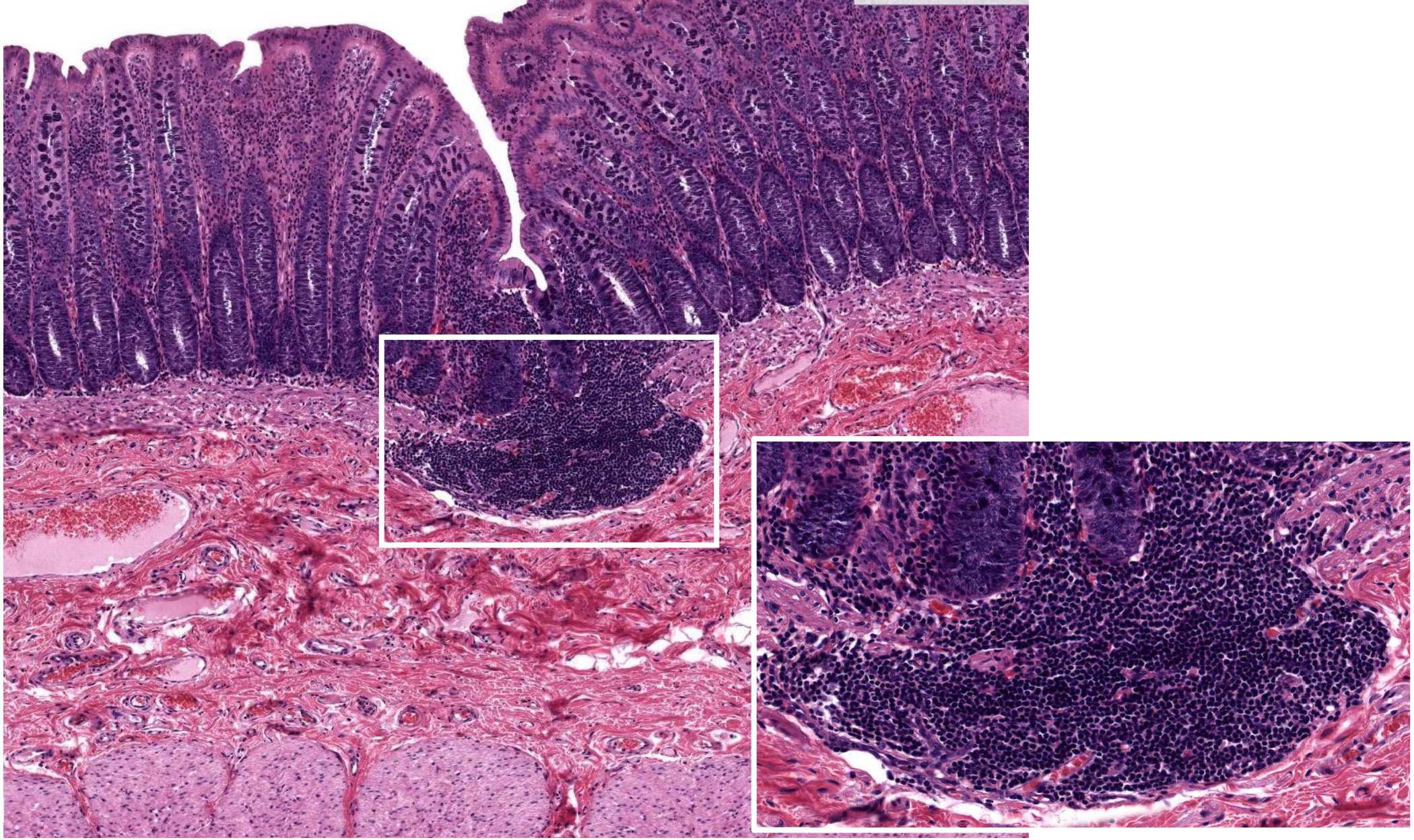

Lámina 17

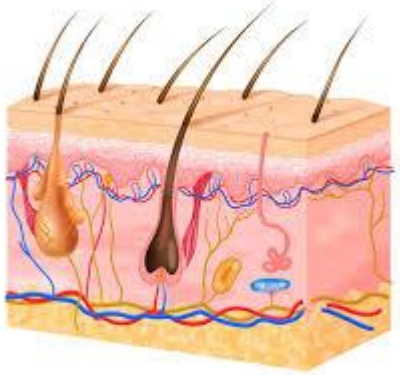

Lámina 18

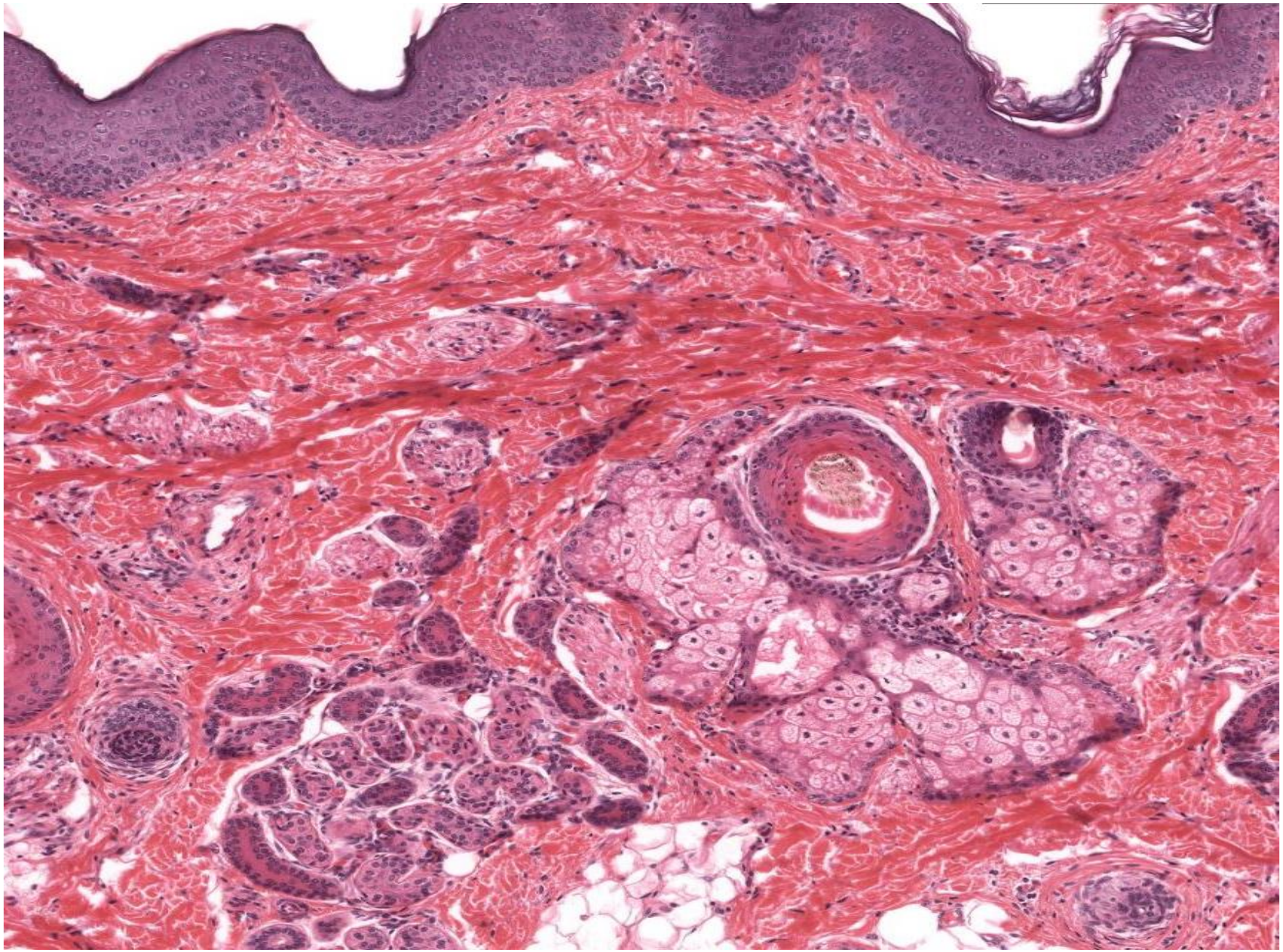

Lámina 18

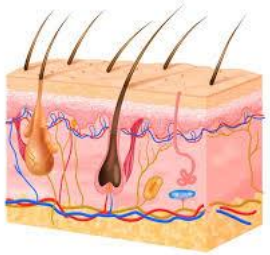

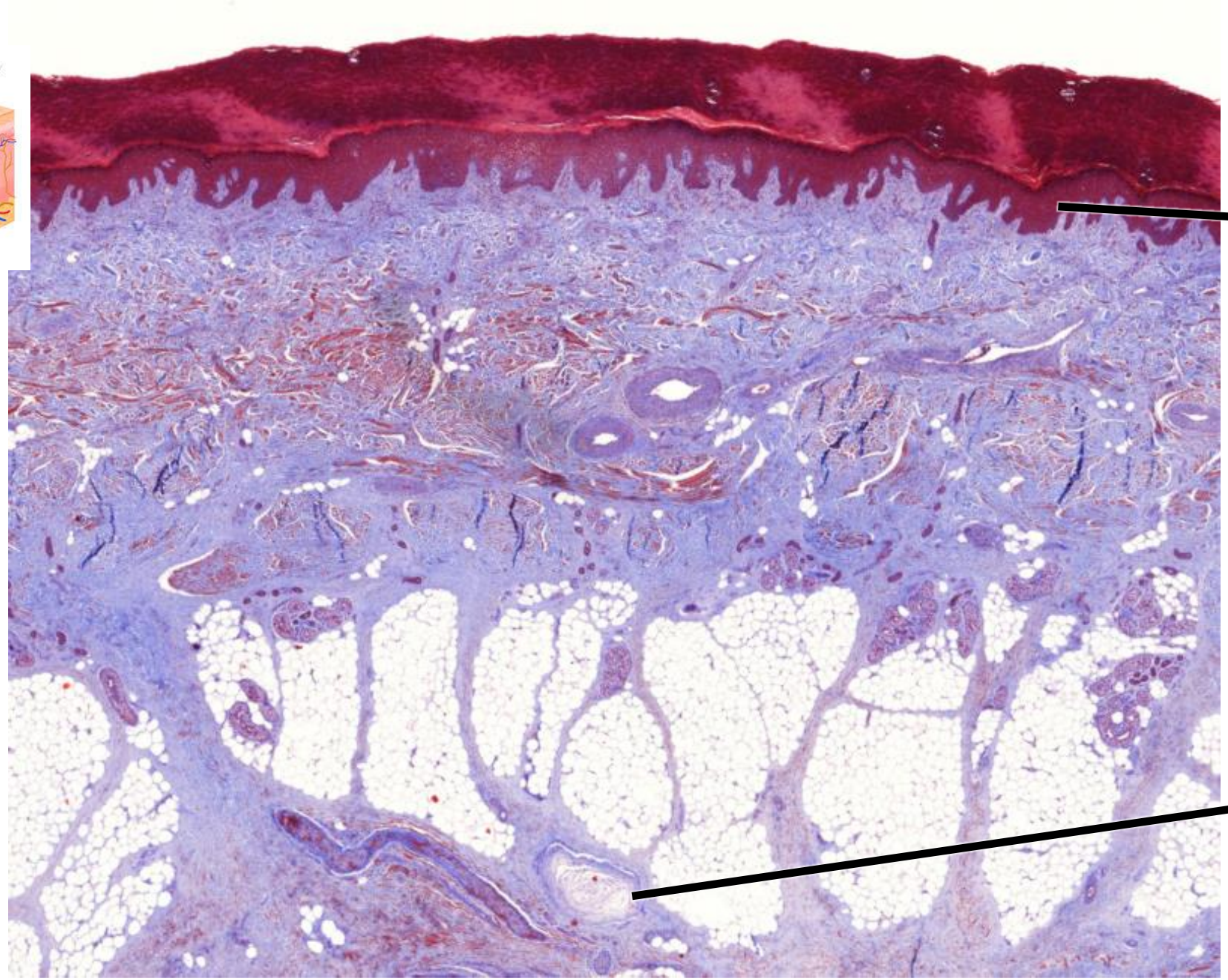

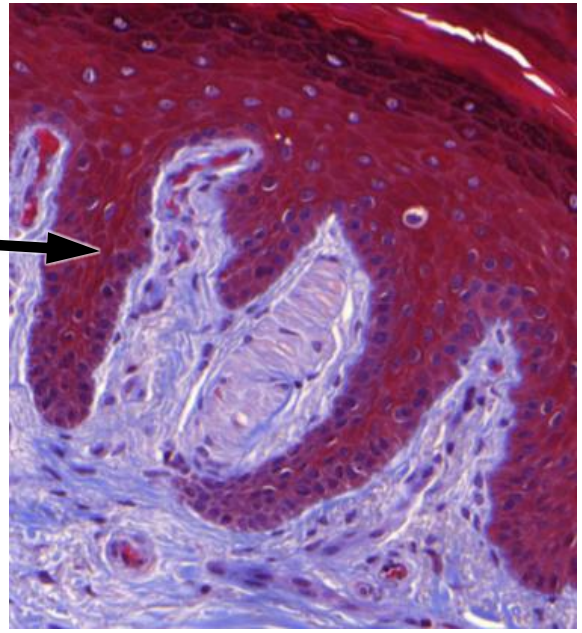

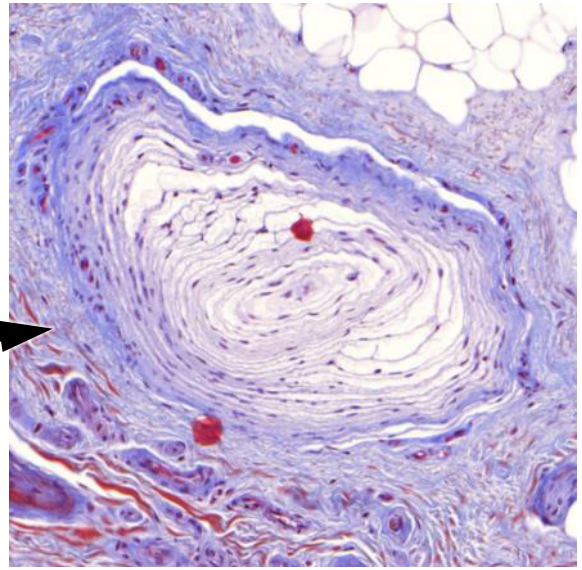

Lámina 19

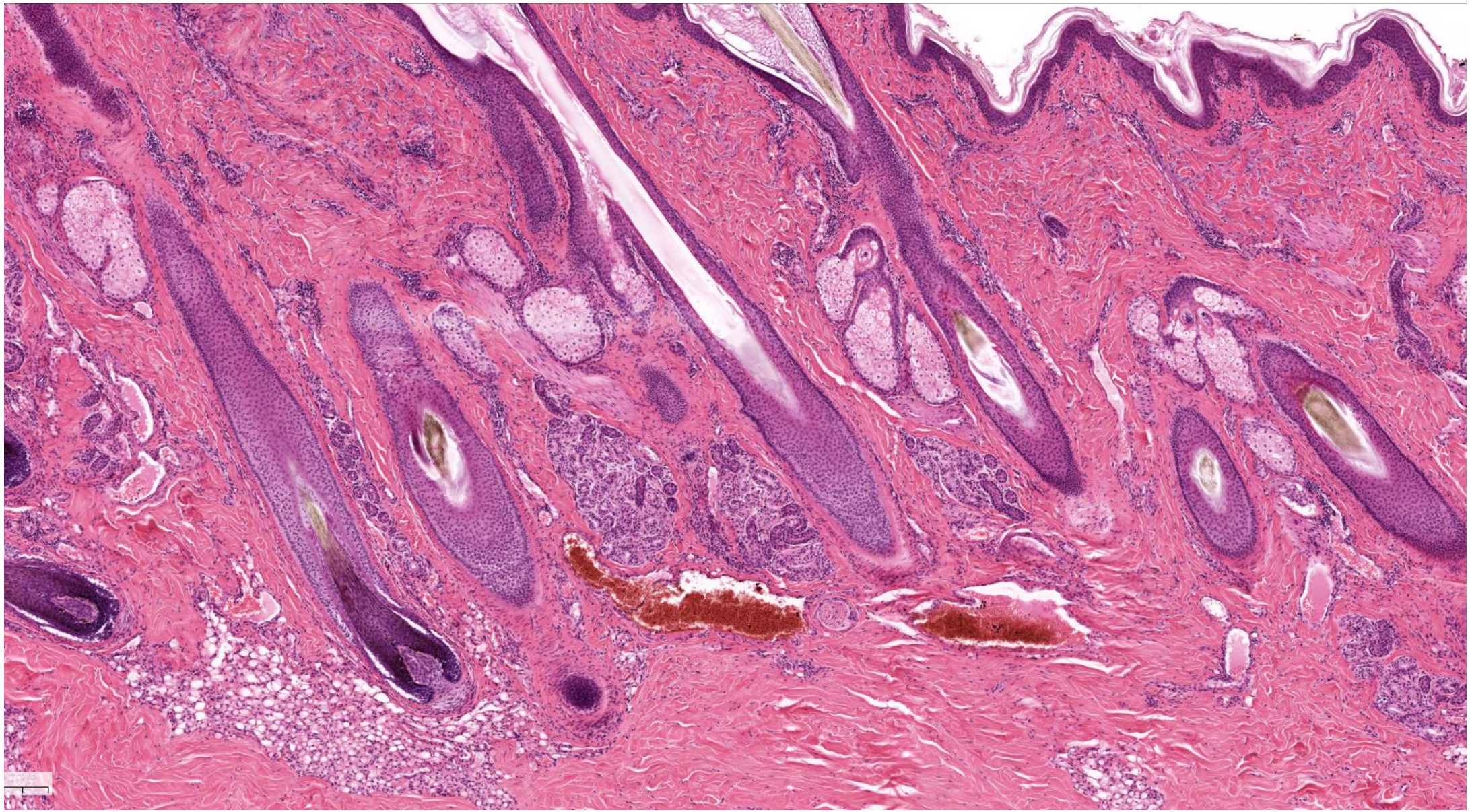

Lámina 20