

KINEMATICS OF NORMAL MENISCI DURING KNEE FLEXION

J.G. GUERRERO¹ and M. FOIDART-DESSALLE²

From the Department of Physical Medecine, University Hospital Center of Liège, Sart Tillman-4000 LIEGE

ABSTRACT

The human knee menisci are important structures to, proper knee joint function. At present, little data exists describing the meniscal kinematics of the intact knee. Accordingly, the purpose of this study was to determine in-vivo meniscal kinematic motion of the non-injured knee during unloaded knee flexion through use of magnetic resonance imaging (MRI).

Seven females and three males (mean age = 27.6 yrs. +/- 7.7 yrs.) who denied previous history of knee injury, were examined by magnetic resonance imaging (MRI) throughout a full range of motion at 0, 60, and 120 degrees of knee flexion. Computer two-dimensional images of the menisci were generated and evaluated quantitatively for anteroposterior excursion. Deformation was evaluated qualitatively. During flexion, the posterior excursion of medial meniscus was 6.2 mm, while that of the lateral meniscus was 8.2 mm. The lateral meniscus is relatively more mobile. The anterior horn segments were shown to be more mobile than the posterior horn segments except for the lateral meniscus and indicates that this meniscus moves more as a single unit. The medial meniscus has been shown to be constrained in the posterior horn, a site of frequent tear. The menisci also act to fill the void created by the incongruous femoral condyles and tibial plateau, and thereby enhance joint stability.

Prior limitations of meniscal kinematic assessment may be overcome with advanced imaging techniques such as magnetic resonance imaging. The menisci are highly mobile and easily deformed structures within the intact knee joint. This imaging technique may prove useful in the elucidation of meniscal dynamics. In conclusion, this study revealed that MRI can be used as a noninvasive method to determine in-vivo meniscal motion. In addition, the amount of kinematic motion was menisci and horn dependent. In the future, similar techniques may be applied clinically to aid in the diagnosis of joint dysfunction.

Key words: *Menisci-Kinematics-Magnetic resonance images*

¹ Physiotherapist

² Prof. Dr. M. FOIDART-DESSALLE

INTRODUCTION

A large number of researches have investigated the functions of the menisci. In the past, the meniscus was thought to be a functionless structure. The menisci are now considered an integral component to the complex biomechanics of the knee.

At the seventies, there was considerable speculation as to the mechanical role of the menisci. Thus, it was common practice to perform total meniscectomy as a treatment for injured menisci. However, clinical follow-up studies began to report that the meniscectomized knees were more prone to degenerative arthritis.^{1, 2, 10, 23, 27}

This led other researchers to speculate that the menisci might have some load-bearing function.^{6, 8, 14, 20, 25, 41} The functions attributed to the menisci include load transmission, shock absorption, joint lubrication,^{17, 21} joint nutrition, congruity^{14, 28, 39} and joint stability.^{19, 29, 38, 41} Also, the nerve endings in the menisci have sensory function. They may, therefore, provide some proprioceptive function relating to joint position.^{22, 45, 46}

Other clinical^{1, 12, 24, 32} and biomechanical^{3, 6, 14, 26, 35, 39, 41, 42} research has established that the meniscus has an important role as a protective load-sharing structure. These studies estimate that the menisci transmit between 30% to 70% of the load applied across the joint.^{1, 3, 6, 8, 14} They protect the articular cartilage from high concentrations of stress by increasing the congruity of the two surfaces and hence the contact area. In order to accomplish this, the menisci must resist extrusion from the space between the articular surfaces as load applied. This function is dependent on the generation of circumferential tension in the meniscus named « hoop stress » as vertical load is applied to the intact structure.⁵

The structural organization of collagen bundles suggested specific biomechanical functions.^{7, 13, 17, 44} There is a correlation between microstructure and biomechanics.^{5, 7, 13, 15, 30, 31, 42, 44} The ultrastructural organization of meniscal tissue appears to be a non homogeneous and non isotropic.^{5, 7, 13, 30} Despite this knowledge, a review of the literature reveals no published studies, except little data, in the area of mechanicals kinematics throughout a full extension-flexion arc of the non-injured knee in the in-vivo conditions. Early work by Shear,³⁶ Brantigan and Voshell,⁴ and DePalma¹¹ visualized the menisci directly to describe displacement during flexion. In each study, the knee was extensively dissected leading to compromised joint stability. Additionally, the femoral condyles concealed much of the meniscal surface allowing assessment of only the exposed, nonarticulating segments.

In recent years, indirect imaging has been used to circumvent the limitations of dissection. Bylski-Austrow et al.,⁹ using single planar roentgenology, examined the effects of compression, rotation, and translation on meniscal displacement. While this study was the first to examine excursion under loaded conditions, results were only obtained through the first 30° of flexion.

More recently, Thompson et al.,⁴⁰ studied the kinematic motion of cadaver menisci using a MRI scanner. A three-dimensional reconstruction magnetic resonance image model was used to explore the meniscal dynamics in an intact, unloaded cadaver knee through its full range of motion.

The purpose of this study was to determine in-vivo meniscal kinematic motion of the non-injured knee during unloaded knee flexion through use of magnetic resonance imaging (MRI).

MATERIALS AND METHODS

A total of 10 people volunteered to participate in the study, 7 females and 3 males. Demographic characteristics of the subjects are presented in Table 1. Subjects had no prior history of knee injury or surgery. All knees were included in this study. They had no evidence of osteoarthritis, meniscal lesion, and/or ligamentous abnormality to MRI.

Table 1. Demographic characteristics of the subjects (n=10).

MEASURE	MEAN	SD
HEIGHT (cm)	160.4	3.5
WEIGHT (kg)	60.4	4.1
AGE (yrs)	27.6	7.7

A 1.5 Tesla superconducting magnet was used to acquire the MR images (Philips, Release 3). Dual receiving surface coils were applied to either side of the knee to improve the signal to noise ratio and optimize the spatial resolution of the MR image. A 256 x 205 matrix with 1.25 x .625 mm pixel size and 16 cm field of view were selected to further enhance spatial resolution in the spatial plane. A spin echo (SE) pulse sequence was used with a repetition time (TR) of 550 msec and echo time (TE) of 20 msec. Multislice interleaved sagittal imaging produced scans consisting of 30 contiguous 3 mm slices with no gaps.

The MRI data was transferred to a computer (Gyroview H-R, Philips, Release 3) to obtain all measurements for evaluate composite MMX (medial menisci) and LMX (lateral menisci) motion. Tibial excursion of the menisci were evaluated quantitatively. The meniscal images were also viewed and grossly analyzed to qualitatively assess deformation (Figs. 1-6).

MRI scans were evaluated mid-sagittally at medial and lateral condyles. The midcondyle slice was determined through use the outer border of the meniscus and respective cruciate ligament as landmarks. The midway point between the two identified landmarks was used as the midcondyle slice. The reference points for anterior horn meniscal motion were the anterior edge of the tibial plateau and anterior peripheral border of the meniscus. The reference points for posterior horn meniscal motion were posterior edge of the tibial plateau and posterior peripheral border of the meniscus. The distance from the reference point on the tibial plateau to the reference point on the meniscus was recorded as the kinematic meniscal motion. The maximum anteroposterior translation of the anterior and posterior horn segments was measured along the tibial plateau and recorded. These measurements were averaged and a mean meniscal excursion value was obtained for each meniscus. Composite MMX and LMX motion was calculated by summing the respective anterior and posterior horn motion and dividing by two. All measurements were recorded in millimeters. MRI scanning was performed at 0, 60, and 120 degrees of knee flexion.

Protocol

Potential subjects who responded to the study advertisement were informed of the purpose of the study. The subject

was asked to lie on a platform which was used to move her/him into the bore of the MRI scanner. The researcher identified the subject's medial and lateral knee joint line to which dual surface coils were centered and secured with an elastic wrap. Knee joint angles were goniometrically confirmed by the investigator. The 0 degree knee flexion scan was completed with the subject supine. The 60 and 120 degree knee flexion scans were complete with the subject in lateral decubitus position. Order of testing was sequential, beginning at 0 degrees. The data were archived on magnetic tape and hard copy film for analysis.

Data Analysis

Data were analyzed using descriptive and inferential statistics. Inferential analyses were completed using paired t-tests. Independent variables analyzed were horn and composite meniscal motion. The 0.10 level of probability was considered statistically significant.

RESULTS

All knees in this preliminary study demonstrated normal soft tissue, bony, ligamentous, and meniscal anatomy on MRI. The mean medial meniscal excursion was 6.2 mm \pm 2.3 mm and the mean lateral meniscal excursion was 8.2 mm \pm 2.5 mm. This displacement is well visualized by representative two-dimensional parasagittal MR images through the medial and lateral midfemoral condyles from 0 to 120 degrees of knee flexion (Figs. 1-6).

The ratio of medial to lateral excursion was 1:1.4 and was statistically significant ($P < 0.10$, $t = 0.074$). A significant difference existed between the MMX and LMX: the LMX moved 1.4 times more than the MMX from 0 to 120 degrees of knee flexion. These values are resumed in Table 2.

Segmental analysis of both menisci was also performed. The MMX and LMX kinematic motion was stratified by anterior and posterior horn. Compositely, from 0 to 120 degrees of knee flexion, the anterior MMX horn moved very significantly ($P < 0.10$, $t = 0.051$) more than the posterior MMX horn. No significant difference ($P < 0.10$, $t = 0.693$) in composite motion occurred between the two horns of the LMX. The ratio of mean posterior to anterior horn excursion was 1 : 1.5 medially and 1 : 0.9 laterally. The anterior horn medially moved 1.5 times more than the posterior horn. The anterior and posterior horn laterally moved as a single unit. Values for mean segmental motion of the MMX and the LMX are given in Table 3.

Table 2. Composite meniscal motion (mm). Values obtained in the midcondylar, parasagittal plane along the tibial plateau.

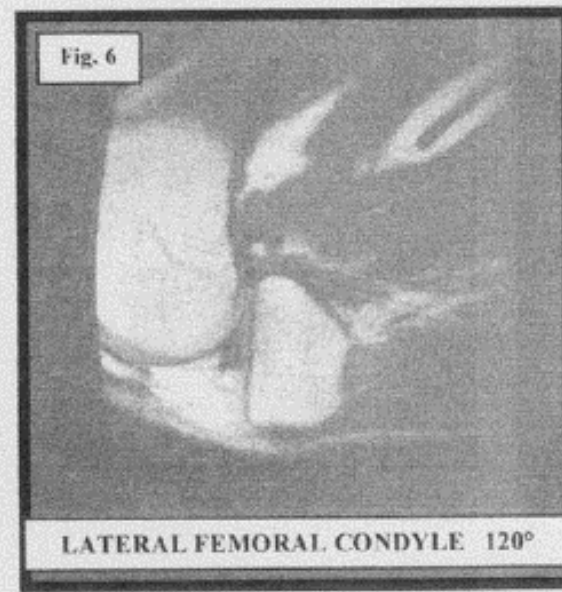
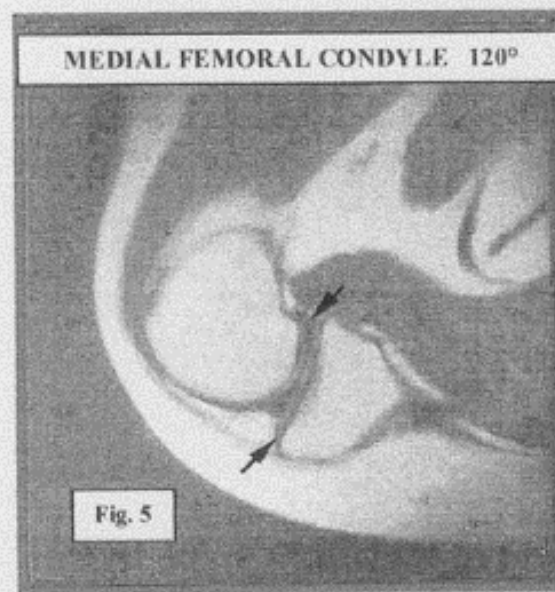
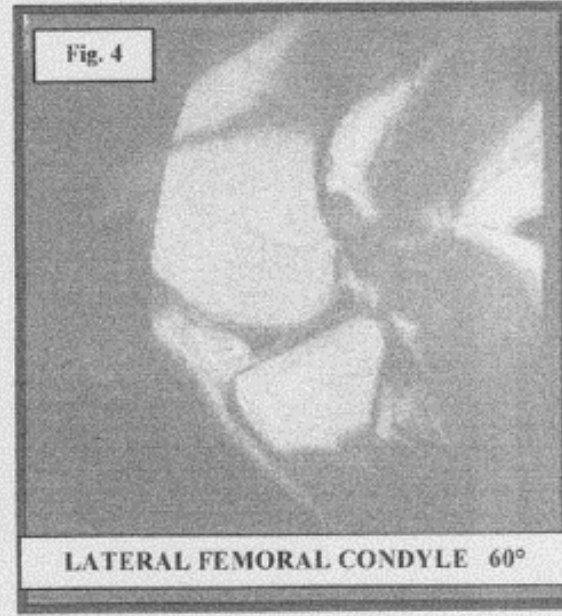
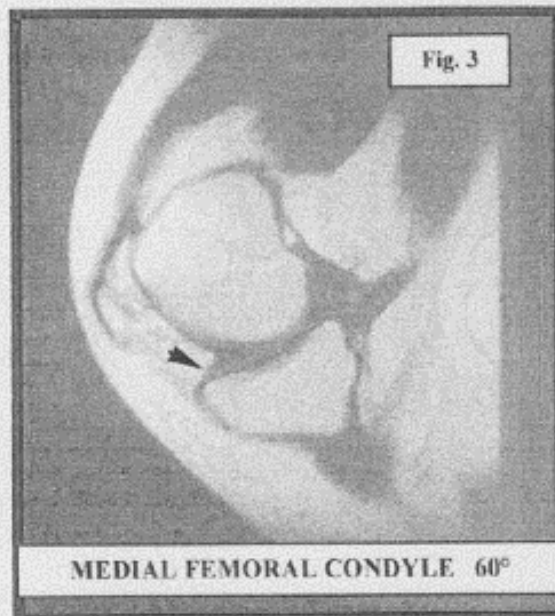
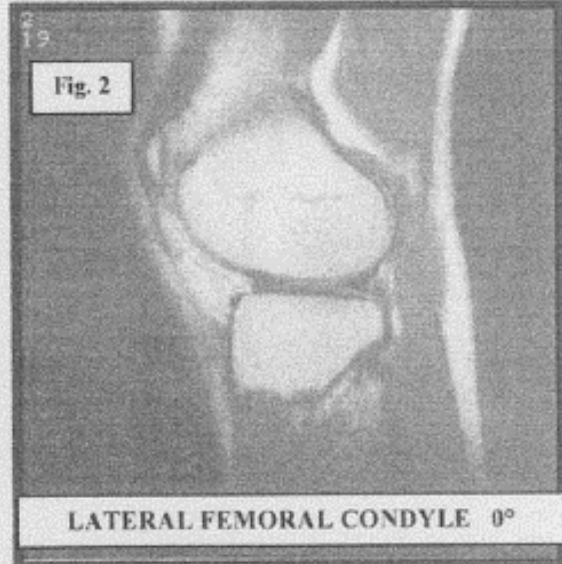
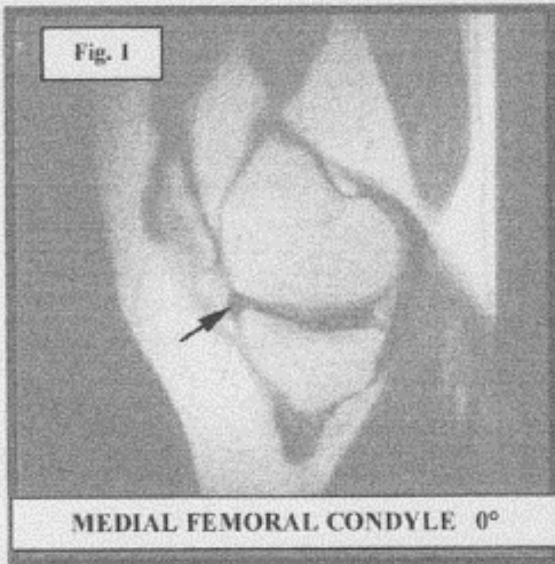
MENISCUS	MEAN	SD	RATIO
MEDIAL (MMX)	6.2	2.3	1
LATERAL (LMX)	8.2	2.5	1.4

The menisci in all of the knees remained in constant contact with tibial and femoral articular surfaces throughout the full range motion. Meniscal deformation was primarily demonstrated qualitatively as increasing concavity of the superior articulating meniscal surface in response to increasing femoral flexion (Figs. 1-6). Other more subtle changes were observed, including a change in the orientation of the nonarticulating meniscal surface of the anterior horns. This meniscal margin maintains a nearly vertical orientation in full extension and changes to an anteroinferior to posterosuperior plane with femoral flexion. In this study, the anterior horn of medial meniscus demonstrated the greatest degree of deformation (Figs 3 and 5). In full extension, a portion of the meniscal substance is displaced anterior to the tibial plateau margin, resulting in a more irregular cross-sectional appearance of this segment (Fig. 1). The coronary ligaments were also visualized attached to the inferior margins of both anterior horns in all knees. The anterior portions of these ligaments were lax in extension and became taut during flexion (Figs 3 and 5).

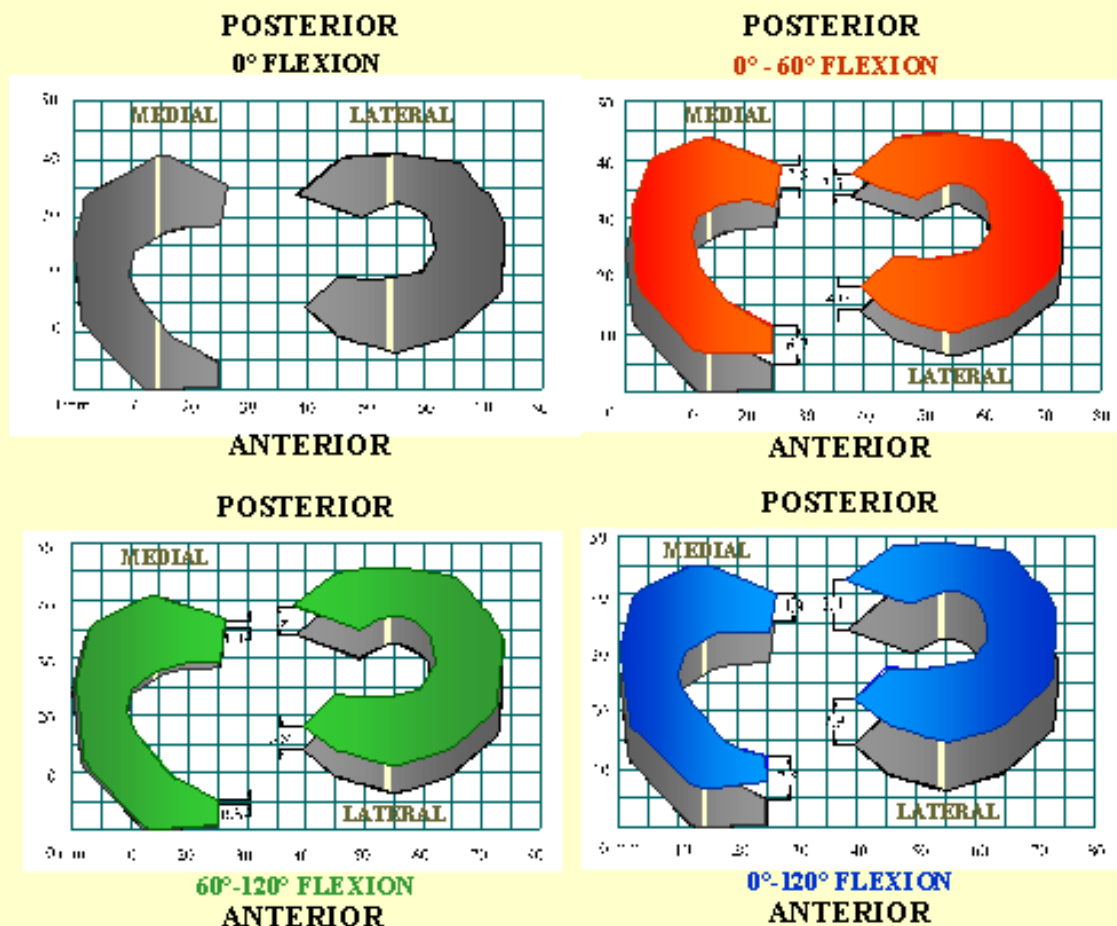
Table 3. Segmental motion of the MMX (mean value in mm) and the LMX (mean value in mm) as a function of flexion angle.

ANGLE (deg)	<i>MEDIAL MENISCAL EXCURSION</i>				<i>LATERAL MENISCAL EXCURSION</i>			
	ANT. HORN	SD	POST. HORN	SD	ANT. HORN	SD	POST. HORN	SD
0-60	6.7	3.9	3.8	2.5	4	3.1	3.5	3.2
60-120	0.8	2.5	1.1	2.6	3.9	2.5	4.9	2.5
0-120	7.5	3.7	4.9	1.8	7.9	3.7	8.4	2.6

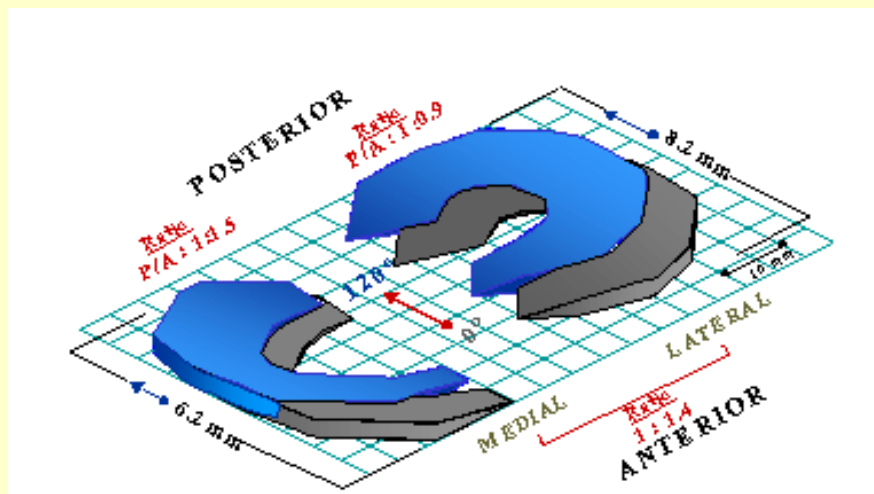
Figures 1-6. Parasagittal MR images through the medial and lateral midfemoral condyles (from 0° to 120°).



Figures 2. 1-6 Parasagittal MR images through the medial and lateral midfemoral condyles (0° to 120°).



Graphic 1. Schematic depiction of mean meniscal motion (in millimeters) along the plateau tibial.



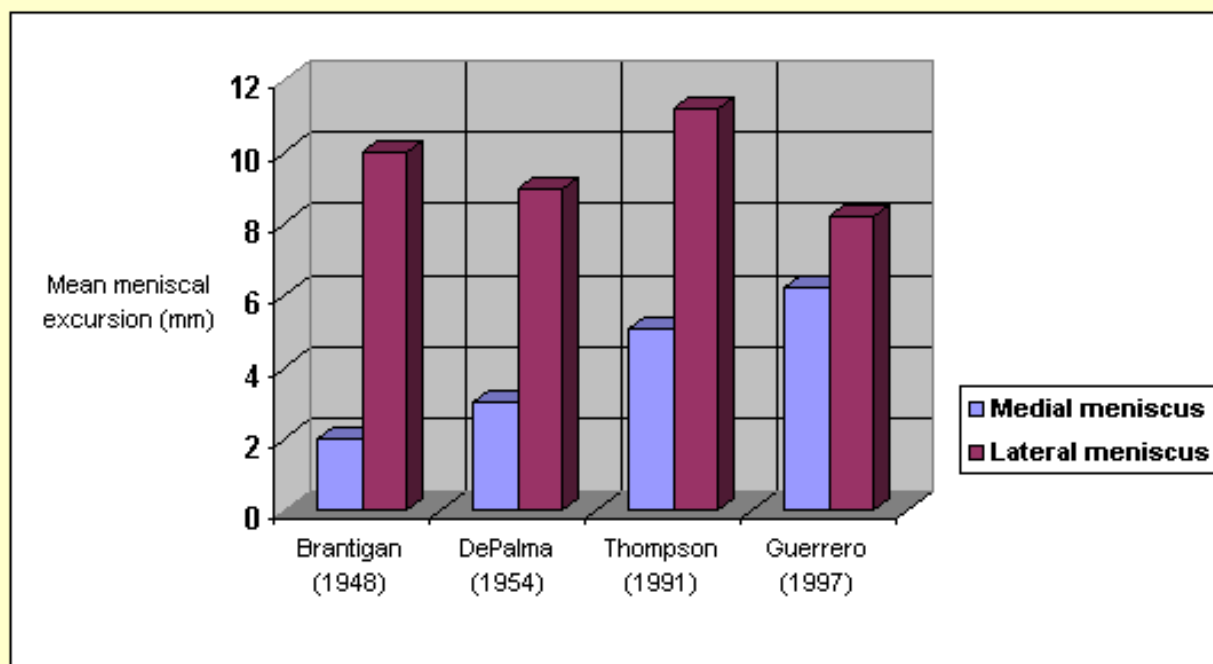
DISCUSSION

In the past, limitations, including mechanically disruptive dissection, and visual obstruction by adjacent structures, precluded the complete dynamic description of the menisci. Recent improvements in radiographic techniques such as computed tomography (CT) and magnetic resonance imaging (MRI) allow for the kinematic analysis of an intact joint. Indirect imaging has been used to avoid the limitations of dissection. The study by Shapeero et al.³⁷ used a cardiac cine CT technique to assess the change in femorotibial contact points during flexion in the intact cadaver knee. Unfortunately, due to beam-hardening artifacts, CT offers limited soft tissue contrast adjacent to bone. This made detailed descriptions of the meniscus and hence meniscal motion very difficult.^{16, 33} Advances in multiplanar CT and

MRI imaging and processing now make three-dimensional reconstructions possible to essentially dissect the knee, isolate the menisci, and study their dynamics without alteration of joint anatomic structures and thus knee motion.

A comparison of the data obtained in this study with that of prior studies was made (Graphic 2). The classic study by Brantigan and Voshell⁴ of ligamentous function revealed the medial meniscus to move on average 2 mm while the lateral meniscus was markedly more mobile with approximately 1 cm of anteroposterior displacement during flexion. In later investigation, DePalma¹¹ states that the medial meniscus undergoes 3 mm of anteroposterior displacement while the lateral moves 9 mm with flexion. Shear's study³⁶ included no numeric data. Thompson et al.⁴⁰ studied the kinematic motion of cadaver menisci using a MRI scanner. Using five cadavers knees resected to 12 to 15 cm proximal to the knee joint, they measured meniscal motion at 10 degree intervals from 0 to 110 to 130 degrees of knee flexion. They reported that composite meniscal motion for the MMX was 5.1 mm +/- 0.96 mm and for the LMX was 11.2 mm +/- 3.27 mm. The ratio of medial to lateral motion was 1:2.3 +/- 0.86, which was statically significant. It was further reported that the posterior horns of the menisci were significantly less mobile than the anterior horns. The ratio of posterior to anterior horn motion for the LMX was 1:2.4 +/- 0.81 and for the MMX was 1:1.3 +/- 0.23. The average horn motion was as follows: anterior horn MMX, 7.0 mm; anterior horn LMX, 12.8 mm; posterior horn MMX, 3.2 mm; and posterior horn LMX, 9.6 mm.

Graphic 2. Comparison of values obtained by different authors for mean meniscal excursion (mm) along the tibial plateau.



Our series revealed the mean medial excursion to be 6.2 mm (average of anterior and posterior horns) and mean lateral excursion to be 8.2 mm along the tibial articular surface. Thus, all of the study are in agreement that the lateral meniscus has greater tibial excursion than the medial excursion. The ratios of medial meniscus to lateral meniscus motion are also similar, ranging from a low of 1:2.3 (Thompson)⁴⁰ to a high of 1:5 (Brantigan)⁴. Our study was 1:1.4. Exact explanation of the slight translational discrepancies is impossible since none of the prior studies describe in detail the method of measurement or which reference points were used to obtain displacement data. This is the first study to examine the differential of anterior to posterior horn excursion in the in-vivo condition. The menisci showed a significant segmental difference in mobility with the posterior horns (except for the LMX) exhibiting less posterior displacement than the anterior horns (except LMX) in relation to the tibia during flexion. In fact, the anterior to

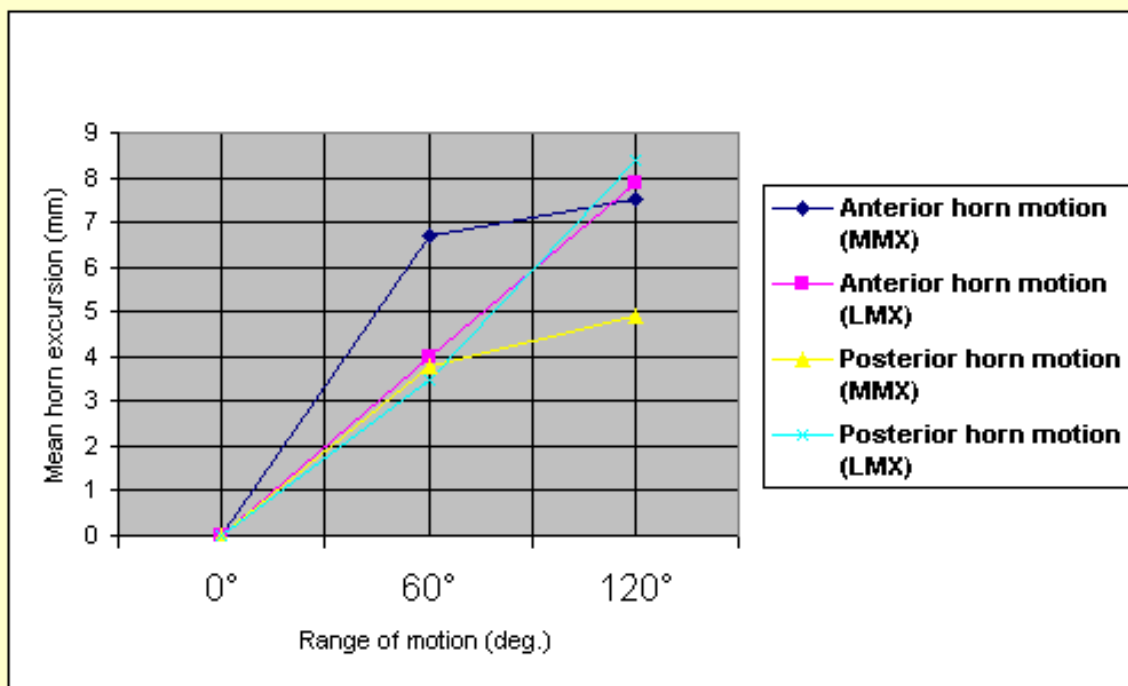
posterior horn lateral meniscus ratio is smaller and indicates that this meniscus moves more as a single unit (Graphic 3). Alternately, the medial meniscus as a whole moves less than the lateral displaying a greater anterior to posterior horn differential excursion.

The area of least meniscal motion is the posterior medial corner, where the meniscus is constrained by its attachment to the tibial plateau by the meniscotibial portion of the posterior oblique ligament fibers,^{18, 43} as well as the articular geometry. This area has also been shown to be much more prone to injury.³⁴ Diminished motion of the posterior horn of the medial meniscus is a potential mechanism for meniscal tear in this region, with a resultant « trapping » of the fibrocartilage between the femoral condyle and tibial plateau during full flexion (Fig. 5). The greater differential between anterior and posterior horn excursion also may place the medial meniscus at greater risk for injury.

A analysis of various phases of knee flexion by DePalma¹¹ demonstrates that the majority of lateral meniscal displacement occurs after 5 to 7 degrees of knee flexion have been achieved. In contrast, the medial meniscus is quiescent until 17 to 20 degrees of flexion. Also, according to DePalma, the medial meniscus commences translation at 70 degrees as the posterior horn is gripped firmly between the posterior flare of the femoral condyle and the tibial plateau, whereas the lateral meniscus continues its posterior excursion until the completion of flexion. This observation is quite reasonable when one considers the lateral compartment anatomy. The lack of posterior bony opposition (i.e., convex femoral condyle and tibial plateau), an unconstrained peripheral meniscal margin, and close central tibial attachments allow the lateral meniscus a wide range of excursion.

The differential of anterior horn to posterior horn motion allows the menisci to assume a decreasing radius with flexion, which correlates to the decreasing radius of curvature of the posterior femoral condyles. This change in radius enables the menisci to maintain contact with the articulating surfaces of both femur and tibia throughout the full range of motion (Figs. 1-6), and thus provide additional stability to the tibiofemoral joint. This is a demonstration of the viscoelastic nature of menisci (Graphic 3). Their ability to change shape and translocate allows the menisci to maintain joint congruity of the articular surfaces throughout a full range of motion. In addition, probably the motion of menisci will be influence by the capsular, muscular, and ligamentous attachment, as well as the tibial and femoral articular anatomic configurations, knee joint motion, and loading.

Graphic 3. Diagram of mean segmental motion (mm) of the medial and lateral menisci as a function of flexion angle.



Several limitations of this study should be noted, including the small sample size. Further work needs to be done to confirm the preliminary excursion values obtained. This study reveals that MRI may be used as a noninvasive method to determine meniscal motion. Limitations of this model however include: the non-weight mode due to restriction of presently available MRI technology, knee flexion limited to 90 degrees for large size people due to space limitation in the MRI bore, and lack of control and measurement of tibiofemoral rotation. Possible clinical uses of this model include assessment of meniscal dynamics after meniscal injury or repair. With meniscal transplantation gaining more interest. Three-dimensional reconstruction of magnetic resonance images may be used to size menisci. Both volumetric data can be derived from 3D reconstructed images. Advances in 3D software, as well as a nonrestrictive magnet bore size permitting full range of motion of the patient's knee, may allow this technique to be applied clinically.

Future advancements of noninvasive imaging techniques and data manipulation will possibly allow the orthopaedic surgeons to evaluate the pathomechanics of menisci in a patient, suitably select a volumetrically compatible allograft or prosthesis, and evaluate its kinematics after surgery.

REFERENCES

1. **Allen, P.R., Denham, R.A., and Swan, A. V.:** Late degenerative changes after meniscectomy. Factors affecting the knee after operation. *J. Bone Joint Surg.* 66B: 666-671, 1984.
2. **Appel, H.:** Late results after meniscectomy in the knee joint. A clinical and roentgenologic follow-up investigation. *Acta Orthop. Scand. Suppl.* 133: 1-111, 1970.
3. **Baratz, M.E., Fu, F.B., and Mengato, R.:** Meniscal tears. The effect of meniscectomy and of repair on intraarticular contact areas and stress in the human knee. *Am. J. Sports Med.* 14: 270-275, 1986.
4. **Bratigan, O., and Voshell, A.:** The mechanics of the ligament and menisci of the knee joint. *J. Bone Joint Surg.* 23: 44-66, 1941.
5. **Beaupré, B.A., Choukroun, R., Guidouin, R., and Garneau, R.:** A study of the menisci of the knee by scanning electron microscopy. *Rev. Chir. Orthop.* 67: 713-719, 1981.

6. **Bourne, R.B., Finlay, J.B., Papadopoulos, P., and Andreae, P.:** The effect of medial meniscectomy on strain distribution in the proximal part of the tibia. *J. Bone Joint Surg.* 66A: 1431-1437, 1984.
7. **Bullough, P.G., Munera, L., Murphy, J., and Weinstein, A.M.:** The strength of the menisci of the knee as it relates to their fine structure. *J. Bone Joint Surg.* 52B: 564-570, 1970.
8. **Burke, D.L., Ahmed, A.M., Miller, J., and Stachiewicz, J.W.:** Pressure distribution of the tibial plateau : Load transmission role of the menisci. *Trans. of 23th Orthop. Res. Soc.* 2: 105, 1977.
9. **Bylski, D.:** In situ measurement of meniscal mechanics in human knee joints. *Doctoral dissertation, University of Michigan, 1986.*
10. **Dandy, D.J., and Jackson, R.W.:** The diagnosis of problems after meniscectomy. *J. Bone Joint Surg.* 57B: 349-352, 1975.
11. **DePalma, A.F.:** Diseases of the knee. *Philadelphia, J.B. Lippincott Company, 1954.*
12. **Fairbank, T.J.:** Knee joint changes after meniscectomy. *J. Bone Joint Surg.* 30B: 664-670, 1948.
13. **Fithian, D.C., Kelly, M.A., and Mow, V.C.:** Material properties and structure-function relationships in the menisci. *Clin. Orthop.* 252: 19-31, 1990.
14. **Fukubayashi, T., and Kurosawa, H.:** The contact area and pressure distribution pattern of the knee. *Acta Orthop. Scand.* 51: 871-879, 1980.
15. **Ghadially, F.N., Lalonde, J.M.A., and Wedge, J.H.:** Ultrastructure of normal and torn menisci of the human knee joint. *J. Anat.* 136: 773-791, 1983.
16. **Ghelman, B.:** Meniscal tears of the knee: evaluation by high-resolution CT combined with arthrography. *Radiology* 157: 23-27, 1985.
17. **Ghosh, P., and Taylor, T.K.F.:** The knee joint meniscus. A fibrocartilage of some distinction . *Clin. Orthop.* 224: 52-63, 1987.
18. **Heller, L., and Langman, J.:** The menisco-femoral ligaments of the human knee. *J. Bone Joint Surg.* 46B: 307-313, 1986.
19. **Hsieh, H., and Walker, P.S.:** Stabilizing mechanisms of the loaded and unloaded knee joint. *J. Bone Joint Surg.* 58A: 87-93, 1976.
20. **Ihn, J.C.:** In vitro study of the contact area and pressure distribution in the human knee of the partial and total meniscectomy . *Int. Orthop.* 17: 214-218, 1993.
21. **Jaspers, P.A., De Lange, A., Huiskes, R., and Van Rens, Th. J.G.:** The mechanical function of the meniscus experiments on cadaveric pig knee joints. *Acta Orthop. Belgica* 45: 663-668, 1980.
22. **Johansson, R.J., Sjolander, P., and Sojka, P.:** Receptors in the knee joint ligaments and their role in the biomechanics of the joint. *Biomedical Engineering* 18: 341-368, 1991.
23. **Johnson, R.J., Kettelkamp, B.B., Clarck, W., and Leaverton, P.:** Factors affecting late results after meniscectomy. *J. Bone Joint Surg.* 56A: 719-786, 1974.

24. **Jones, D.A., Smith, E.C., and Reisch, J.S.:** Effects of medial meniscectomy in patients older than forty years. *J. Bone Joint Surg.* 60A: 783-786, 1978.
25. **Kettelkamp, D.B., and Jacobs, A.W.:** Tibiofemoral contact area. Determination and implications. *J. Bone Joint Surg.* 54B: 349-356, 1972.
26. **Krause, W.R., Pope, M.H., Johnson, R.J., and Wilder, D.G.:** Mechanical changes in the knee after meniscectomy. *J. Bone Joint Surg.* 58A: 599-604, 1976.
27. **Lotke, P.A., Lefkoe, R.T., and Ecker, M.L.:** Late results following medial meniscectomy in a older population. *J. Bone Joint Surg.* 63A: 115-119, 1981.
28. **Maquet, P.G., Van De Berg, A.J., and Simonet, J.C.:** Femorotibial weight-bearing areas. *J. Bone Joint Surg.* 57A:766-771,1975.
29. **Markolf, K.L., and Amstutz, H.C.:** Stiffness and laxity of the knee. The contributions of the supporting structures. *J. Bone Joint Surg.* 58A: 583-594, 1976.
30. **McDevitt, C.A., and Webber, R.J.:** The ultrastructure and biochemistry of meniscal cartilage. *Clin. Orthop. Rel. Res.* 252: 8-18, 1990.
31. **Mow, V.C., Holmes, M.H., and Lai, W.M.:** Fluid transport and mechanical properties of articular cartilage: a review. *J. Biomech.* 17: 377-394, 1984.
32. **Noble, J., and Erat, K.:** In defence of the meniscus. A prospective study of 200 meniscectomy patients. *J. Bone Joint Surg.* 62B: 7-11, 1980.
33. **Passariello, R., Trecco, F., de Paulis, F., Masciocchi, C., Bonanni, G., and Zobel, B.B:** Meniscal lesions of the knee joint: *CT diagnosis.* *Radiology* 157: 29-34, 1985.
34. **Ricklin, P., Ruttimann, A., and Del Bouno, M.S.:** Diagnosis, Differential Diagnosis and Therapy. *Second Edition, Stuttgart, Verlag, Georg Thieme, 1983.*
35. **Seedhom, BB., and Hargreaves, D.J.:** Transmission of the load in the knee joint with special reference to the role of the menisci. Part II: Experimental results, discussion and conclusions. *Eng. Med.* 8: 220-228, 1979.
36. **Shear, H.:** Der Meniskusschaden. Leipzig, *Georg Thieme, 1938.*
37. **Shapeero, L.G., Dye, S.F., and Lipton, M.J.:** Functional dynamics of the knee joint by ultrafast, cine-CT. *Invest. Radiol.* 23: 118-123, 1988.
38. **Shoemaker, S.C., and Markolff, K.L.:** The role of the meniscus in the anterior cruciate deficient knee. *J. Bone Joint Surg.* 68A: 71-79, 1986.
39. **Shrive, N.G., O'Connor, J.J, and Goodfellow, J.W.:** Load-bearing in the knee joint. *Clin. Orthop.* 131: 279-287, 1978.
40. **Thompson, W., Thaete, F., Fu, F., and Dye, S.:** Tibial meniscal dynamics using three-dimensional reconstruction of magnetic resonance images. *Am. J. Sports Med.* 19: 210-216, 1991.
41. **Walker, P.S., and Erkman, M.J.:** The role of the menisci in force transmission across the knee. *Clin. Orthop.*

109: 184-191, 1975.

42. **Whipple, R.R., Wirth, C.R., and Mow, V.C.:** Mechanical properties of the meniscus. *In: Spilker, R.L., Ed. Advances in bioengineering. ASME: 32-33, 1984.*

43. **Yamamoto, M., and Hirohata, K.:** Anatomical study on the menisco-femoral ligaments of the knee. *Kobe J. Med. Sci. 37: 209-226, 1991.*

44. **Yasui, K.:** Three-dimensional architecture of human normal menisci. *J. Jap. Orthop. Ass. 52: 391-399, 1978.*

45. **Zimny, M.L., Albright, D.J., and Dabezies, E.:** Mechanoreceptors in the human medial meniscus. *Acta Anat. 133: 35-40, 1988.*

46. **Zimny, M.L., and Wink, C.S.:** Neuroreceptors in the tissues of the knee joint . *J. Electromyogr. Kinesiol. 1: 148-157, 1991.*

ACKNOWLEDGMENTS

The authors wish to thank Prof. Dr. N. Perlmutter, from the Department of Radiology, University Hospital REINE FABIOLA; Joël Minet; and particular Marie Leonore Franck, for their valuable technical assistance with this study.



[Go to Fisioterapia Electrónica](#)